

The 2010 Nephrology Quiz and Questionnaire: Part 1

Richard J. Glassock (Co-Moderator),* Anthony J. Bleyer (Co-Moderator),[†] Donald E. Hricik (Discussant),[‡] and Biff F. Palmer (Discussant)[§]

Presentation of the Nephrology Quiz and Questionnaire (NQQ) has become an annual “tradition” at the meetings of the American Society of Nephrology. It is a very popular session judged by consistently large attendance. Members of the audience test their knowledge and judgment on a series of case-oriented questions prepared and discussed by experts. They can also compare their answers in real time, using audience response devices, to those of program directors of nephrology training programs in the United States, acquired through an Internet-based questionnaire. As in the past, the topics covered were transplantation, fluid and electrolyte disorders, end-stage renal disease and dialysis, and glomerular disorders. Two challenging cases representing each of these categories along with single best answer questions were prepared by a panel of experts (Drs. Hricik, Palmer, Bargman, and Fervenza, respectively). The “correct” and “incorrect” answers then were briefly discussed, after the audience responses and the results of the questionnaire were displayed. The 2010 version of the NQQ was exceptionally challenging, and the audience, for the first time, gained a better overall correct answer score than the program directors, but the margin was small. In this issue we present the transplantation and fluid and electrolyte cases; the remaining end-stage renal disease and dialysis, and glomerular disorder cases will be presented next month. These articles try to recapitulate the session and reproduce its educational value for a larger audience—the readers of the *Clinical Journal of the American Society of Nephrology*. Have fun.

Clin J Am Soc Nephrol 6: 2318–2327, 2011. doi: 10.2215/CJN.00900111

Transplantation Case 1: Donald E. Hricik

A 63-year-old woman with ESRD secondary to type 2 diabetes mellitus received a kidney transplant from a deceased donor 6 months ago. The donor was serologically positive for Epstein Barr-virus (EBV) and for cytomegalovirus (CMV) based on IgG titers, while the recipient was serologically negative for both EBV and CMV. The patient received induction antibody therapy with rabbit anti-thymocyte globulin (total dose ~ 6 mg/kg) and maintenance therapy with tacrolimus, enteric-coated mycophenolate sodium, and glucocorticoids that were withdrawn per protocol after 7 days. At the time of transplantation, the following prophylactic agents were prescribed: trimethoprim-sulfamethoxazole (one single strength daily for life), co-trimazole troches (10 mg three times daily for 3 months), and valganciclovir (450 mg daily for 3 months).

Because of a “donut hole” in her Medicare Part D drug coverage, her monthly co-pay for valganciclovir was ~\$1200/mo. Her allograft functioned immediately, and her nadir serum creatinine concentration was 1.4 mg/dl 3 weeks after transplant, with subsequent values ranging between 1.5 and 1.8 mg/dl. She is now admitted to the hospital for evaluation of a 2-week history of bloody diarrhea, fever, and chills.

On physical examination, the patient has mild postural hypotension. Temperature is 38.3°C. Laboratory studies reveal a serum creatinine concentration of 1.9 mg/dl, BUN 59 mg/dl, hemoglobin 8.9 g/dl (baseline 10.5 g/dl), and white blood cell 4500/cumm (baseline ~ 6000). Blood PCR for CMV is negative. EBV titers are pending. The patient’s postural hypotension resolves with intravenous saline and transfusion of

packed red blood cells. Arrangements have been made for a colonoscopy.

Transplantation Question 1A

Which ONE of the following statements regarding the differential diagnosis is MOST correct (Figure 1)?

- A. The negative PCR for CMV rules out CMV enteritis.
- B. CMV is unlikely because it rarely occurs more than 5 months after transplantation.
- C. CMV disease would have been less likely if prophylaxis with valganciclovir had been extended for 6 months.
- D. EBV-related lymphoma of the gastrointestinal tract is unlikely this early after transplantation.
- E. Her illness is most likely due to treatment with enteric-coated mycophenolate sodium.

Discussion of Case 1 (Question 1A)

The best answer is choice C. Infection with CMV remains an important cause of morbidity in solid organ kidney transplant recipients (1–3). CMV is a member of the Herpesvirus group and shares with this family the characteristic ability to remain latent in the body over long periods of time (2). Although CMV disease can result from an acute primary infection, most cases in transplantation reflect latent infections that are reactivated in the presence of immunosuppression. The risk of developing either CMV viremia or tissue-invasive disease after transplantation is influenced by the organ transplanted (lung, small intestines > pancreas, heart > liver, kidney) and by the intensity of immunosuppression. How-

*David Geffen School of Medicine at UCLA, Los Angeles, California; [†]Wake Forest University School of Medicine, Winston-Salem, North Carolina; [‡]Division of Nephrology and Hypertension, Department of Medicine, University Hospitals Case Medical Center, Cleveland, Ohio; and [§]Department of Internal Medicine, University of Texas Southwestern Medical Center, Dallas, Texas

Correspondence: Dr. Richard J Glassock, 8 Bethany, Laguna Niguel, CA 92677. Phone: 949-388-8885; Fax: 949-388-8882; E-mail: Glassock@cox.net

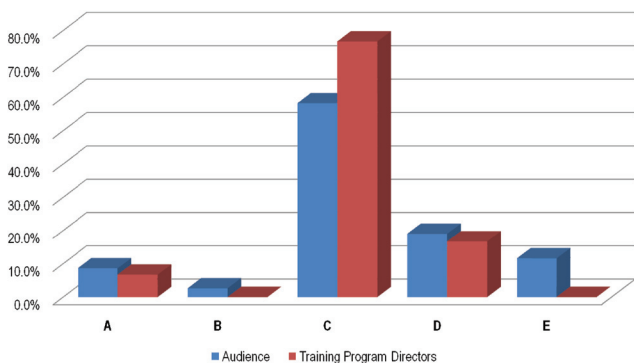


Figure 1. | Answers from the membership, question 1A, Transplantation.

ever, the most important risk factor is a serologic mismatch between the donor and recipient in which the donor (D) has detectable IgG antibodies for CMV whereas the recipient (R) does not (i.e., D+/R-) (see Table 1) (4). In the absence of preventive therapy, CMV reactivation can occur in more than 75% of D+/R- kidney transplant recipients (4).

Preventive therapy for CMV consists either of a *preemptive approach* in which antiviral therapy is withheld until surveillance studies indicate the development of viremia or *universal prophylaxis* in which the patient is treated with an antiviral drug for some arbitrary period of time to prevent viral reactivation. Both approaches have proved to be effective in preventing CMV disease (5–7). However, only the prophylactic approach has proved to be beneficial in preventing some of the indirect effects of CMV infections, such as co-infections with other Herpes viruses and super-infections with bacteria and fungi (5). The American Society of Transplantation’s Infectious Disease Community of Practice now recommends universal prophylaxis for high-risk D+/R- transplant recipients (8).

For centers using universal prophylaxis, the choice of antiviral drugs and the duration of prophylactic therapy are subjects of some controversy. Oral valganciclovir has largely replaced intravenous or oral ganciclovir as the agent of choice. Valganciclovir is rapidly hydrolyzed to the active ganciclovir compound, exhibits substantially better oral bioavailability (9), and proved to be noninferior to oral ganciclovir in a randomized trial in which the two drugs were used for 100 days (10). More recently, to test the hypothesis that a longer duration of prophylaxis is beneficial in preventing CMV disease, the IMPACT trial randomized 320 D+/R- kidney transplant recipients to either 100 or 200 days of prophylaxis with oral valganciclovir (900 mg/d, adjusted for renal function) (11). The incidence of CMV disease 12 months after transplantation was 37%

Risk Category	Donor (D) or Recipient (R) Sero-reactivity (+/-)
High	D+/R-
Intermediate	D+/R+, D-/R+
Low	D-/R-

in the group randomized to 100 days of prophylaxis, and 17% in the group randomized to 200 days ($P < 0.0001$) (11). Although these data suggest that a longer duration of prophylaxis is preferable for high-risk patients, the benefits of extended prophylaxis must be weighed against the cost and toxicities of antiviral therapy, as well as the likelihood that prolonged therapy will promote the emergence of ganciclovir resistance. Moreover, the design and conclusions of the IMPACT trial have recently been challenged (12).

Regarding the incorrect answers to Question 1A: (A) The gastrointestinal tract is a known sanctuary for CMV infection. When the infection is isolated to involvement of the intestinal tract, the blood PCR may be negative in the early stages of the disease. (B) At one time, before the availability of effective antiviral drugs, CMV infection occurred most commonly in the first 3 months after transplantation. With preventive therapies, most cases occur well beyond the third post-transplant month. Indeed, many cases have been described years after transplantation (8). (D) The patient was also a serologic mismatch for Epstein Barr virus (i.e., D+/R-), putting her at high risk for early post-transplant lymphoproliferative disease. (E) Mycophenolate derivatives are a common cause of diarrhea and leukopenia, but are rarely a direct cause of bloody stools or fever.

Transplantation Question 1B

Presuming that the colonoscopy reveals CMV colitis, which of the following statements regarding treatment is MOST correct (Figure 2)?

- A. Because resistance to ganciclovir is likely, initial treatment should consist of foscarnet and CMV Ig, pending the results of cultures.
- B. Treatment should consist of 4 to 6 weeks of intravenous ganciclovir, the exact duration depending on resolution of symptoms.
- C. Treatment should consist of intravenous ganciclovir until serologic evidence for CMV has subsided.
- D. Treatment should consist of intravenous ganciclovir followed by oral valganciclovir once the patient’s fever and bloody diarrhea have resolved.

(Note: This Question was not contained in the Program Director’s Questionnaire.)

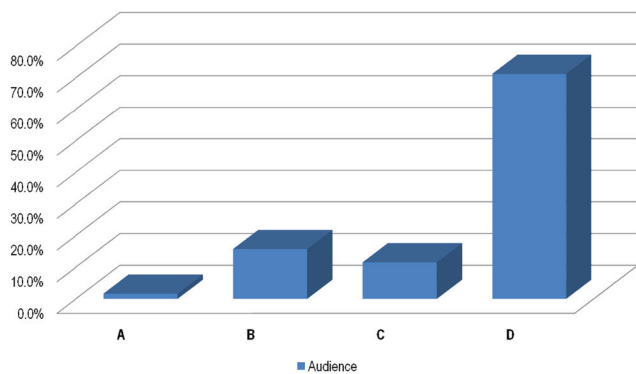


Figure 2. | Answers from the membership, question 1B, Transplantation.

Discussion of Case 1 (Question 1B)

The best answer is choice D. Intravenous ganciclovir has been the “gold standard” for CMV disease treatment for many years. However, results of the VICTOR trial indicated that oral valganciclovir may be a safe alternative. VICTOR was an open-label multicenter study that enrolled adult solid organ transplant recipients with both CMV viremia and symptoms consistent with CMV disease (13). Participants were randomized to receive induction treatment with either oral valganciclovir 900 mg twice daily or intravenous ganciclovir 5 mg/kg twice daily, for 21 days. After 21 days, patients in both groups underwent maintenance treatment with valganciclovir 900 mg/d for 28 days. By day 21, CMV viremia had been eradicated in 45.1% of the valganciclovir-treated patients and in 48.4% of the ganciclovir-treated patients, suggesting that oral valganciclovir was noninferior to intravenous ganciclovir. Rates of viral eradication remained comparable for valganciclovir and ganciclovir after 12 months (13). Recent guidelines suggest that either intravenous ganciclovir or oral valganciclovir treatment should be initiated for treatment of CMV disease and continued for at least 2 weeks, with weekly monitoring of viral loads, until one to two consecutive negative samples are obtained (8,14).

Regarding the incorrect answers to Question 1B: (A) Ganciclovir resistance occurs in less than 3% of organ transplant recipients with CMV disease (15). In the VICTOR trial, there was equal development of resistance in the intravenous ganciclovir and oral ganciclovir groups at 1 year (13). Recent guidelines suggest that resistance should be considered and immunosuppression reduced, only after 2 weeks of adequate dosing with an unchanged or increasing viral load (14). (B and C) Prolonged therapy with intravenous ganciclovir may be reasonable, but it is usually in patients with life-threatening disease and whenever oral absorption of valganciclovir is problematic, as is often the case in young children (8,14).

Transplantation Case 2: Donald E. Hricik

A 59-year-old man with ESRD from autosomal dominant polycystic kidney disease had a living donor kidney transplant from his haplo-identical brother 13 years ago. His current immunosuppression consists of cyclosporine (Neoral), generic mycophenolate mofetil (MMF), and prednisone. His transplant allowed him to return to a successful landscaping business. During the past 3 years, serum creatinine concentration gradually rose from 0.9 to 1.5 mg/dl, prompting a transplant renal biopsy 3 months ago, revealing interstitial fibrosis and tubular atrophy. Cyclosporine dose was reduced by 50%, but the serum creatinine has not changed. Recent laboratory studies have included a spot urine protein/creatinine ratio of 0.35 g protein/g creatinine. Estimated GFR is 42 ml/min per 1.73 m². For the past 6 years, he has noted innumerable warts on his hands, arms, and face. During the same time period, his dermatologist has resected three basal cell carcinomas. He has required surgery for six squamous cell carcinomas involving his scalp, nose, left ear, and right hand—each resulting in significant disfigurement. Physical examination reveals multiple keratoses on the scalp, face, upper trunk, arms, and feet.

Transplantation Question 2A

Which ONE of the following changes in the patient’s immunosuppressive regimen would be MOST helpful in dealing with the patient’s clinical presentation (Figure 3)?

- A. Convert MMF to azathioprine
- B. Convert MMF to enteric-coated mycophenolate sodium
- C. Convert prednisone to everolimus
- D. Convert cyclosporine to sirolimus
- E. Convert MMF to sirolimus

Discussion of Case 2 (Question 2A)

Choice D is the best answer for this patient who has two common post-transplant problems: (1) progressive deterioration of renal function with biopsy evidence of interstitial fibrosis and tubular atrophy (IFTA), and (2) multiple skin keratoses and nonmelanoma skin cancers. The importance of fibrosis *per se*, and of calcineurin inhibitor-induced fibrosis as a cause of renal allograft loss has become increasingly controversial. Nevertheless, it well known that these agents are commonly associated with IFTA (16). Moreover, experience with extrarenal organ transplant recipients indicates that as many as 30% of such patients develop renal impairment that has been attributed primarily to this class of agents (17). For kidney transplant recipients with renal dysfunction, the wisdom of conversion from calcineurin inhibitors to a mammalian target of rapamycin (mTOR) inhibitor (specifically sirolimus) was best assessed in the CONVERT trial in which 930 patients with abnormal allograft function were randomized in a 2:1 ratio either to convert from their calcineurin inhibitor to sirolimus or to remain on the calcineurin inhibitor (18). Patients were stratified according to baseline estimated GFRs (Nankivell formula) of 20 to 40 ml/min or greater than 40 ml/min. Enrollment of patients into the former group was aborted because of an excess of adverse events including graft loss. Among the remaining 743 patients with baseline eGFRs >40ml/min/1.73m², GFR increased significantly in patients who were randomized to the conversion group and who remained on therapy. Unexpectedly, this beneficial effect on GFR was not observed in patients exhibiting even modest proteinuria at baseline (18). Thus, conversion from a calcineurin inhibitor to sirolimus appears to be most helpful to patients with a baseline eGFR >40ml/min/1.73m² and urine protein excretion less than 500 mg/d.

Nonmelanoma skin cancers are the most common ma-

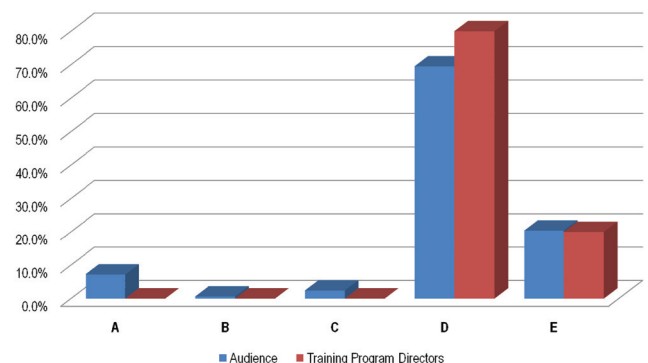


Figure 3. | Answers from the membership, question 2A, Transplantation.

lignancies experienced by kidney transplant recipients, occurring 50 to 200 times more frequently than in the general population. Nonrandomized studies as well as retrospective analyses of randomized trials have suggested that nonmelanoma skin cancers may be less common in transplant recipients treated with sirolimus-based immunosuppression than in control groups (18,19). In a recent multicenter German trial, 44 patients with multiple skin keratoses and skin cancers were randomized either to remain on conventional immunosuppression or to convert to sirolimus (20). After 12 months, there was a significant improvement in keratosis scores and in the incidence of new skin cancers, providing some credibility for offering this conversion to patients plagued with recurrent skin cancers after transplantation.

Regarding the incorrect answers to Question 2A: (A and B) There have been no good studies comparing the incidence of skin cancers among patients taking mycophenolate mofetil *versus* azathioprine or mycophenolate sodium *versus* mycophenolate mofetil. Conversions between these agents would likely have little impact on the patient’s renal dysfunction. (C) Corticosteroids actually exhibit some anti-neoplastic effects, and it is not clear if they increase or decrease the risk of skin cancer. Late withdrawal of prednisone certainly would not improve renal dysfunction and might even pose a risk of superimposed acute rejection. (E) Conversion from mycophenolate mofetil to sirolimus might provide a benefit in reducing subsequent skin cancers but would not likely lead to improved kidney function. Conversion from mycophenolate mofetil to sirolimus would leave the patient on cyclosporine and sirolimus, a combination that would have to be used with great caution as sirolimus tends to enhance the nephrotoxicity of cyclosporine.

Transplantation Question 2B

Which ONE of the following is the MOST likely consequence of the changes in his immunosuppression (Figure 4)?

- A. Decrease in LDL cholesterol
- B. Decrease in urine protein excretion
- C. Increase in fasting blood sugars
- D. Increase in the size of the cysts in his native kidneys
- E. Increase in hemoglobin concentration

Discussion of Case 2 (Question 2B)

The best answer is choice C. A number of studies in animals and humans suggest that the mTOR inhibitors can be

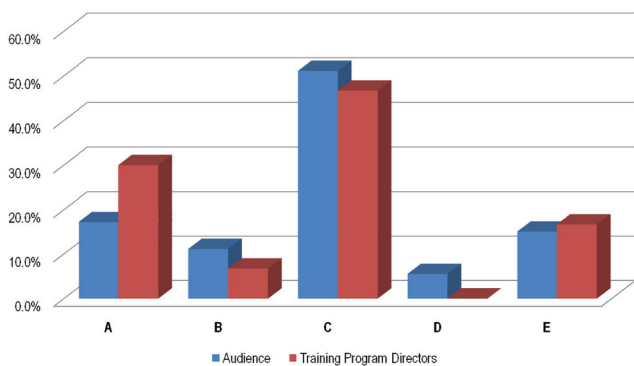


Figure 4. | Answers from the membership, question 2B, Transplantation.

Table 2. Transplantation case 2: complications of treatment with sirolimus

Hematologic	thrombocytopenia
	leukopenia
	microcytic anemia
Metabolic	hyperlipidemia (increased LDL, VLDL, and HDL levels)
	hyperglycemia
Renal effects	proteinuria
	enhanced nephrotoxicity of concomitantly administered calcineurin inhibitors
Miscellaneous	impaired wound healing
	peripheral edema
	mouth ulcers
	prolongation of delayed graft function
	oligospermia
	interstitial pneumonitis

diabetogenic (21–23), although the exact mechanisms remain to be elucidated. In one clinical study of patients being converted from cyclosporine to sirolimus, elimination of the calcineurin inhibitor and/or introduction of sirolimus was associated with a significant decrease in insulin sensitivity and a 30% increase in glucose intolerance (24). Fasting blood sugars or other parameters of glycemic control should be monitored when patients are converted to sirolimus.

The mTOR inhibitors are associated with a variety of side effects (25). Metabolic and other complications of treatment with sirolimus are listed in Table 2, which suffices to explain most of the wrong answers to Question 2B. Regarding answer D, the mTOR inhibitors (rapamycin) are not associated with an *increase* in the size of cysts of patients with polycystic kidney disease. If anything, these agents may *reduce* the size of cysts, but two recent trials have suggested no short-term benefit in retarding the progression of kidney disease in patients with adult polycystic disease (26,27).

Disclosures

None.

References: Transplantation

1. Fishman JA, Rubin RH: Infection in organ-transplant recipients. *N Engl J Med* 338: 1741–1751, 1998
2. Razonable RR, Emery VC: Management of CMV infection and disease in transplant patients. *Herpes* 11: 77–86, 2004
3. Ljungman P, Griffiths P, Paya C: Definitions of cytomegalovirus infection and disease in transplant recipients. *Clin Infect Dis* 34: 1094–1097, 2002
4. Fishman JA, Emery V, Freeman R: Cytomegalovirus in transplantation—Challenging the status quo. *Clin Transplant* 21: 149–158, 2007
5. Hodson EM, Jones CA, Webster AC, Strippoli GF, Barclay PG, Kable K, Vimalachandra D, Craig JC: Antiviral medications to prevent cytomegalovirus disease and early death in recipients of solid-organ transplants: A systematic review of randomised controlled trials. *Lancet* 365: 2105–2115, 2005
6. Kalil AC, Levitsky J, Lyden E, Stoner J, Freifeld AG: Meta-analysis: The efficacy of strategies to prevent organ disease

- by cytomegalovirus in solid organ transplant recipients. *Ann Intern Med* 143: 870–880, 2005
7. Small LN, Lau J, Snyderman DR: Preventing post-organ transplantation cytomegalovirus disease with ganciclovir: A meta-analysis comparing prophylactic and preemptive therapies. *Clin Infect Dis* 43: 869–880, 2006
 8. Humar A, Snyderman D, and the AST Infectious Diseases Community of Practice: Cytomegalovirus in solid organ transplant recipients. *Am J Transplant* 9[Suppl 4]: S78–S86, 2009
 9. Wiltshire H, Paya CV, Pescovitz MD, Humar A, Dominguez E, Washburn K, Blumberg E, Alexander B, Freeman R, Heaton N, Zuideveld KP and the Valganciclovir Solid Organ Transplant Study Group: Pharmacodynamics of oral ganciclovir and valganciclovir in solid organ transplant recipients. *Transplantation* 79: 1477–1483, 2005
 10. Paya C, Humar A, Dominguez E, Washburn K, Blumberg E, Alexander B, Freeman R, Heaton N, Pescovitz MD and the Valganciclovir Solid Organ Transplant Study Group: Efficacy and safety of valganciclovir vs. oral ganciclovir for prevention of cytomegalovirus disease in solid organ transplant recipients. *Am J Transplant* 4: 611–620, 2004
 11. Humar A, Lebranchu Y, Vincenti F, Blumberg EA, Punch JD, Limaye AP, Abramowicz D, Jardine AG, Voulgari AT, Ives J, Hauser IA, Peeters P: The efficacy and safety of 200 days valganciclovir cytomegalovirus prophylaxis in high-risk kidney transplant recipients. *Am J Transplant* 10: 1–10, 2010
 12. Kalil AC, Sun J, Florescu DF: IMPACT trial results should not change current standard of care of 100 days for cytomegalovirus prophylaxis. *Am J Transplant* 11: 18–21, 2011
 13. Asberg A, Humar A, Jardine AG, Rollag H, Pescovitz MD, Mouas H, Bignamini A, Toz H, Dittmer I, Montejo M, Hartmann A: VICTOR Study Group. Long-term outcomes of CMV disease treatment with valganciclovir versus IV ganciclovir in solid organ transplant recipients. *Am J Transplant* 9: 1205–1213, 2009
 14. Kotton CN, Kumar D, Caliendo AM, Asberg A, Chou S, Snyderman DR, Allen U, Humar A; Transplantation Society International CMV Consensus Group. International consensus guidelines on the management of cytomegalovirus in solid organ transplantation. *Transplantation* 89: 779–795, 2010
 15. Drew WL, Paya CV, Emery V: Cytomegalovirus (CMV) resistance to antivirals. *Am J Transplant* 1: 307–312, 2001
 16. Nankivell BJ, Borrowers RJ, Fung CL, O'Connell PJ, Chapman JR, Allen RD: Calcineurin inhibitor nephrotoxicity: Longitudinal assessment by protocol histology. *Transplantation* 78: 557–565, 2004
 17. Ojo AO, Held PJ, Port FK, Wolfe RA, Leichtman AB, Young EW, Arndorfer J, Christensen L, Merion RM: Chronic renal failure after transplantation of a nonrenal organ. *N Engl J Med* 349: 931–940, 2003
 18. Schena FP, Pascoe MD, Alberu J, del Carmen Rial M, Oberbauer R, Brennan DC, Campistol JM, Racusen C, Polinsky MS, Goldberg-Alberts R, Li H, Scarola J, Neylan J and the CONVERT Trial Study Group: Conversion from calcineurin inhibitors to sirolimus maintenance therapy in renal allograft recipients: 24-month efficacy and safety results from the CONVERT trial. *Transplantation* 87: 233–242, 2009
 19. Kauffman HM, Cheriakh WS, Cheng Y, Hanto DW, Kahan BD: Maintenance immunosuppression with target-of-rapamycin inhibitors is associated with a reduced incidence of de novo malignancies. *Transplantation* 80: 883–889, 2005
 20. Salgo R, Gossmann J, Schöfer H, Kachel HG, Kuck J, Geiger H, Kaufmann R, Scheuermann EH: Switch to a sirolimus-based immunosuppression in long-term renal transplant recipients: Reduced rate of (pre-)malignancies and non-melanoma skin cancer in a prospective, randomized, assessor-blinded, controlled clinical trial. *Am J Transplant* 10: 1385–1393, 2010
 21. Song HK, Han DH, Song JH, Ghee JY, Piao SG, Kim SH, Yoon HE, Li C, Kim J, Yang CW: Influence of sirolimus on cyclosporine-induced pancreas islet dysfunction in rats. *Am J Transplant* 9: 2024–2033, 2009
 22. Tanemura M, Saga A, Kawamoto K, Machida T, Deguchi T, Nishida T, Sawa Y, Doki Y, Mori M, Ito T: Rapamycin induces autophagy in islets: relevance in islet transplantation. *Transplant Proc* 41: 334–338, 2009
 23. Johnston O, Rose CL, Webster AC, Gill JS: Sirolimus is associated with new-onset diabetes in kidney transplant recipients. *J Am Soc Nephrol* 19: 1411–1418, 2008
 24. Teutonico A, Schena PF, Di Paolo S: Glucose metabolism in renal transplant recipients: Effect of calcineurin inhibitor withdrawal and conversion to sirolimus. *J Am Soc Nephrol* 16: 3128–3135, 2005
 25. Augustine JA, Bodziak KA, Hricik DE: Use of sirolimus in solid organ transplantation. *Drugs* 67: 369–391, 2007
 26. Walz G, Budde K, Manna M, Nürnberger J, Wanner C, Sommerer C, Kunzendorf U, Banas B, Hörl WH: Everolimus in patients with autosomal dominant polycystic kidney disease. *N Engl J Med* 363: 830–840, 2010
 27. Serra AL, Poster D, Kistler AD, Krauer F, Raina S, Young J, Rentsch KM, Spanaus KS, Senn O, Kristanto P, Scheffel H, Weishaupt D, Wüthrich RP: Sirolimus and kidney growth in autosomal dominant polycystic kidney disease. *N Engl J Med* 363: 820–829, 2010

Received: January 30, 2011 Accepted: June 13, 2011

Published online ahead of print. Publication date available at www.cjasn.org.

Fluid and Electrolyte Case 1: Biff F. Palmer (Discussant)

A 51-year-old man is seen in the emergency room after developing a seizure attributed to hypoglycemia. The patient was well until 3 days ago when he noticed the onset of nausea and decreased appetite. One day later he developed unsteadiness of gait and complained he felt the room was spinning around him. There was one episode of emesis. On the day of admission he experienced a witnessed generalized tonic clonic seizure. Paramedics found him unarousable upon arrival. A serum glucose was measured at 23 mg/dl by fingerstick. After administration of two ampoules of 50% dextrose in water his mental status rapidly improved, and he was transported to the hospital.

The past medical history is significant for type 2 diabetes mellitus, hypertension, psoriasis, and excessive alcohol intake (six beers daily) on weekends. His current medications include metformin 500 mg twice daily and losartan 100 mg every day. He had been training intensively for a 10K run over the last month. He applies Ben-Gay ointment and a heating pad over his lower extremities each evening after running due to nonspecific joint and muscle pain.

Physical examination shows a BP 110/72 mmHg, pulse 110 beats/min, and respiratory rate 26/min. There were skin changes typical of psoriasis on both elbows and knees. The remainder of the examination was normal. Upon completion of the physical examination, the patient was noted to become less arousable but quickly responded to an additional ampoule of 50% dextrose in water followed by a continuous infusion of 10% dextrose in water. Laboratory data obtained immediately after arrival to the emergency room are given in Table 1.

Fluid and Electrolyte Question 1

Which ONE of the following disorders can BEST explain the clinical findings in this patient (Figure 5)?

- A. Metformin toxicity
- B. Alcoholic ketoacidosis

Creatinine (mg/dl)	1.8
BUN (mg/dl)	34
Serum electrolytes (mEq/L):	
Na ⁺	143
K ⁺	2.5
Cl ⁻	107
HCO ₃	15
Glucose (mg/dl)	33
Urine electrolytes (mEq/L)	
Na ⁺	65
K ⁺	40
Cl ⁻	15
Urinalysis and urine culture	Specific gravity: 1.024, pH 5.5, trace protein, 2+ ketones, no cells or casts
Arterial blood gas	pH 7.45, pCO ₂ 20, pO ₂ 78 Torr
Other tests (serum)	Osmolality 298 mOsm/kg, uric acid 1.5 mg/dl, ketones 1+ (undiluted)

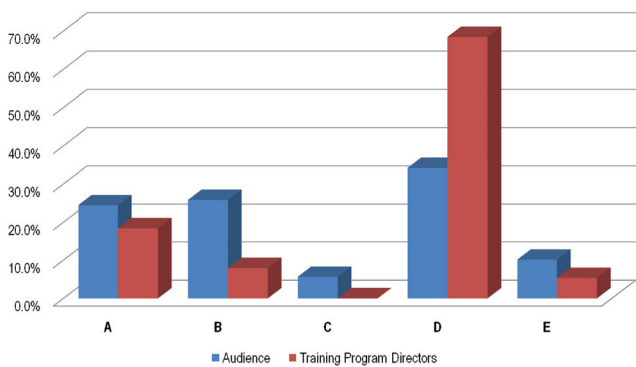


Figure 5. | Answers from the membership, question 1, Fluid and Electrolyte.

- C. Diabetic ketoacidosis
- D. Salicylate toxicity
- E. Isopropyl alcohol ingestion

Discussion of Case 1 (Question 1)

The correct answer is D. The clinical presentation of refractory hypoglycemia in association with the mixed acid-base disturbance of respiratory alkalosis and anion gap metabolic acidosis best fits with a diagnosis of salicylate toxicity. Aspirin (acetylsalicylic acid) is one of the most widely available therapeutic agents and is associated with the largest number of accidental or intentional poisonings. Less well appreciated is the potential for topical preparations to be the source for toxic levels of salicylate.

Methyl salicylate is found in many over-the-counter creams, ointments, and lotions that are used in the treatment of muscle aches and pains. The most potent form of methyl salicylate is oil of wintergreen, a liquid concentrate derived from wintergreen leaf fermentation or made synthetically. The oil is used medicinally in either herbal treatments or more traditional preparations. Oil of wintergreen contains 98% methyl salicylate and is highly toxic in its pure form. Ingestion of a teaspoon of the oil would be the equivalent of taking 22 adult 325-mg aspirin tablets. Whereas over-the-counter pain relief products contain a much lower percentage of methyl salicylate than is con-

tained in the parent oil, their potential for causing toxicity is well documented (1,2).

The active ingredient found in Ben-Gay varies by product version. BenGay “original” contains 15% methyl salicylate, whereas extra strength and ultra strength contain 30% of the compound. One of the warnings on the BenGay label is to avoid using the cream with a heating pad. Application of heat to the skin can cause the cream to melt causing dispersion of the compound to areas of skin beyond where the cream was directly applied. Heat-induced opening of skin pores combined with the greater surface area of exposure will enhance systemic absorption thus predisposing to toxic levels of methyl salicylate. Systemic absorption is further enhanced if the cream should come in contact with skin where the integrity of the epithelium is compromised as in this patient with psoriasis. In this regard refractory hypoglycemia and other manifestation of salicylate toxicity are well described as a complication of topical salicylate therapy given to patients with a variety of skin disorders (3–5).

Aspirin overdose is associated with a variety of acid-base and electrolyte disturbances. Salicylates have a direct stimulatory effect on the respiratory center such that respiratory alkalosis is a prominent feature in the overdose setting. An anion gap metabolic acidosis is also present due primarily to increased production and accumulation of ketoacids and lactic acid. Salicylic acid accumulation accounts for only a minor component of the increase in anion gap. Lactic acid production is increased due to the uncoupling effect of aspirin on oxidative phosphorylation in the mitochondria. Adult patients with aspirin overdose usually present with a mixture of respiratory alkalosis and anion gap metabolic acidosis as was the case in this patient.

A pure metabolic acidosis is unusual in adults. By contrast, children with aspirin overdose may present with an anion gap metabolic acidosis alone particularly soon after ingestion. Hypokalemia is the result of increased renal K⁺ excretion. Renal K⁺ wasting is the result of increased distal delivery of Na⁺ in combination with increased circulating aldosterone (secondary to volume depletion). Urinary Na⁺ excretion is increased due to urinary excretion of Na⁺-salicylate as well as Na⁺-keto-acids. The low urinary Cl⁻

excretion reflects increased renal reabsorption of NaCl in response to contraction of extracellular fluid volume.

With high-dose aspirin therapy or in the setting of an aspirin overdose, the renal excretion of uric acid is increased and hypouricemia may be present. In this setting, the hepatic glucuronidation of salicylic acid is saturated and large quantities of free salicylate are filtered into the tubule. Free salicylate interferes in the reabsorption of uric acid by the proximal tubule, accounting for the uricosuric effect (6).

The clinical manifestations of salicylate intoxication usually begin with headache, tinnitus, and vertigo. More severe intoxication can lead to a noncardiogenic form of pulmonary edema (notice the decreased pO₂ in the case), hyperpyrexia, seizures, and coma. Neurologic toxicity can be exacerbated by the presence of systemic acidemia. In the setting of a low serum pH, a greater fraction of salicylic acid will exist in the unionized form. This form of the drug can readily cross the cell membrane, thus leading to increased intracellular concentrations in the brain. Hypoglycemia can be prominent and refractory to correction as it was in this case. Salicylic acid has been shown to increase insulin secretion, impair gluconeogenesis, and increase glucose consumption by uncoupling oxidative phosphorylation (Figure 6).

In addition to conservative management, the initial goal of therapy is to correct systemic acidemia and to alkalinize the urine pH. By increasing systemic pH, the ionized fraction of salicylic acid will increase, and as a result there will be less accumulation of the drug in the central nervous system. Similarly, an alkaline urine pH will favor increased urinary excretion since the ionized fraction of the drug is poorly reabsorbed by the tubule. At serum concentrations of >80 mg/dl or in the setting of severe clinical toxicity, hemodialysis can be used to accelerate the removal of the drug from the body.

Metformin toxicity (choice A) can be associated with an anion gap metabolic acidosis due to lactic acidosis particularly when used in the setting of decreased renal function. However, the respiratory alkalosis and hypokalemia in this

case are not features of metformin toxicity. In addition, hypoglycemia of this severity is not a complication of metformin when used as monotherapy. Metformin lowers plasma glucose primarily by decreasing hepatic glucose production as well as enhancing peripheral tissue uptake as opposed to stimulating endogenous insulin secretion.

Hypoglycemia is well described in alcoholics, typically occurring in the time period immediately after cessation of alcohol intake and in the setting where food intake is minimal. In addition, the presence of ketones in the blood and urine raise the possibility of alcoholic ketoacidosis (choice B). In this setting, however, an anion gap metabolic acidosis is the primary disturbance, whereas in this case respiratory alkalosis was most prominent. Furthermore, the findings of hypouricemia and the overall clinical presentation make alcohol ketoacidosis incorrect.

Isopropyl alcohol (choice E) is associated with positive testing for ketones in the blood and urine. However, the metabolism of this alcohol does not consume HCO₃ and is not associated with the development of metabolic acidosis. In addition, this disorder is associated with an increase in the osmolar gap due to the accumulation of acetone. Diabetic ketoacidosis (choice C) is not a consideration in this case given the lack of hyperglycemia.

Fluid and Electrolyte Case 2: Biff F. Palmer

A 32-year-old woman presents to the emergency room with a 2-day history of increasing generalized weakness that progressed to the point of not being able to stand without assistance. The patient is known to have bipolar disorder with episodes of depression and manic episodes for which she is treated with quetiapine 300 mg daily. Approximately 1 week ago risperidone was added to her regimen due to severe depression manifested as psychomotor retardation. One day before admission she had one episode of emesis but denied diarrhea. The past medical history is significant for peptic ulcer disease for which she takes pantoprazole. An accompanying family member states the patient has been taking a large quantity of an over-the-counter analgesic for chronic headache.

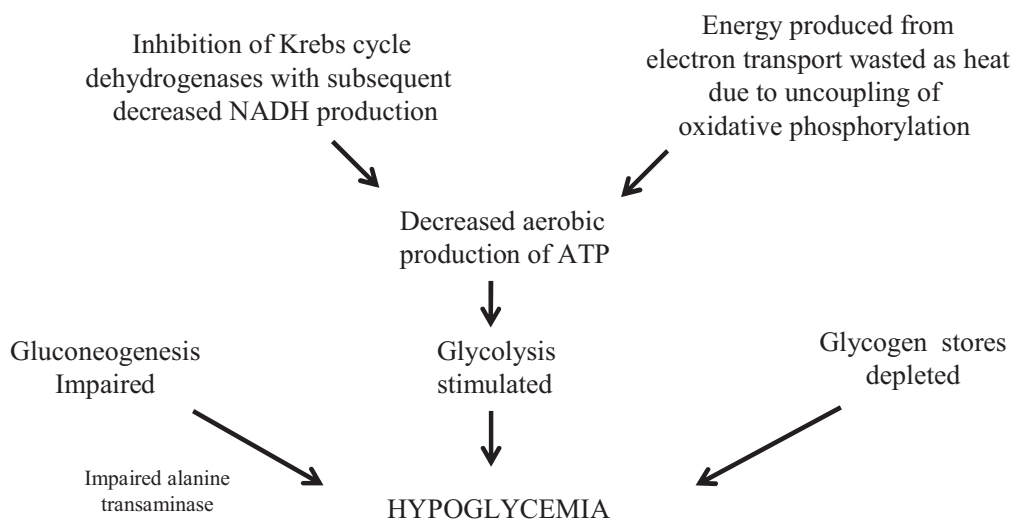


Figure 6. | Fluid and Electrolyte: Case 1. Pathogenic mechanisms of hypoglycemia in salicylate intoxication.

On physical examination: temperature 37°C, BP 116/78 mmHg, pulse 104 beats/min, and respiratory rate 20/min. Strength is noted to be symmetrically reduced in all extremities with proximal weakness greater than distal. The remainder of the exam is normal. The laboratory data are given in Table 2.

Fluid and Electrolyte Question 2

Which ONE of the following disorders BEST accounts for the clinical findings in this patient (Figure 7)?

- A. Quetiapine toxicity
- B. Risperidone toxicity
- C. Ibuprofen toxicity
- D. Acetaminophen toxicity
- E. Pantoprazole toxicity

Discussion of Case 2 (Question 2)

The correct answer is C. This patient presents with progressive weakness in association with hypokalemic normal gap metabolic acidosis. This acid-base disturbance along with hypophosphatemia and glycosuria in the setting of a normal serum glucose concentration are consistent with generalized dysfunction of the proximal tubule or the Fanconi syndrome. Acute ingestion of large quantities of ibuprofen is the most likely cause of these abnormalities.

The most common renal syndromes associated with use of nonsteroidal anti-inflammatory drugs (NSAIDs) are those that occur when normal doses are given to patients who have identifiable risk factors (7). For example, in patients with a low effective arterial blood volume vasodilatory prostaglandins serve to counterbalance the vasoconstrictor effects of effectors such as angiotensin II and sympathetic nerves. NSAIDs can precipitate a hemodynamic form of acute kidney injury in this setting. NSAIDs can worsen hyponatremia in the setting of high circulating levels of arginine vasopressin by inhibiting renal prostaglandins that normally antagonize the hydro-osmotic effect of arginine vasopressin. These drugs increase the risk for developing hyperkalemia particularly when given to patients with an impaired renin-angiotensin-aldosterone axis. Inhibition of renal prostaglandins cause decreased

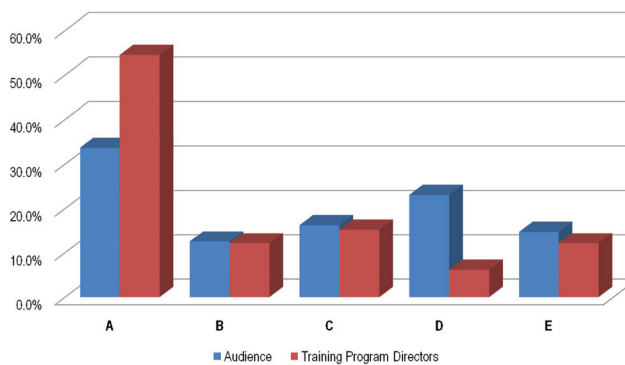


Figure 7. | Answers from the membership, question 2, Fluid and Electrolyte.

renin release from the juxta-glomerular cells in the kidney and therefore predispose to further drops in the downstream production of aldosterone. Tubulo-interstitial renal disease accompanied by the nephrotic syndrome is the one syndrome associated with NSAID use where an identifiable risk factor is not present.

In contrast to the renal syndromes that occur with normal doses of NSAIDs described above, there are several reports describing the development of severe hypokalemia, proximal renal tubular acidosis, and Fanconi syndrome in association with acute ingestion of large quantities of ibuprofen (Table 3) (8–11). In three cases Nurofen Plus tablets (200 mg ibuprofen and 12.8 codeine phosphate) was the source of ibuprofen (8–10). The degree of hypokalemia was severe, with serum K⁺ values ranging from 1.4 to 2.6 mEq/L. In each instance the abnormalities resolved over the course of several days after ingestion.

In addition to ibuprofen, aspirin overdose has also been associated with reversible proximal tubule dysfunction (12,13). In one case a 17-year-old girl took 25 tablets of aspirin (12.5 g acetylsalicylic acid) and 12 hours later was noted to have generalized proximal tubular dysfunction with normoglycemia, glycosuria, aminoaciduria, uricosuria, and normal gap metabolic acidosis. Interestingly, the serum K⁺ remained normal.

Creatinine (mg/dl)	1.2
BUN (mg/dl)	24
Serum electrolytes (mEq/L):	
Na ⁺	138
K ⁺	2.6
Cl ⁻	110
HCO ₃	14
Albumin (g/dl)	4.2
Ca (mg/dl)	9.0
PO ₄ (mg/dl)	1.8
Glucose (mg/dl)	104
Urine electrolytes (mEq/L):	
Na ⁺	45
K ⁺	40
Cl ⁻	80
Arterial blood gas	pH 7.35, pCO ₂ 29 torr, pO ₂ 98 torr
Urinalysis	Specific gravity 1.012, pH 5.5, 1 + glucose, trace protein, trace blood, no cells

Table 5. Fluid and electrolyte case 2: clinical cases in which proximal tubular dysfunction developed in association with acute ingestion of large quantities of a nonsteroidal anti-inflammatory drug

Case (reference)	Substance	Clinical Features	Outcome
28-year-old woman (8)	40 to 60 tablets Nurofen Plus	Fanconi syndrome, K ⁺ 1.4, ↓ PO ₄	Reversible
49-year-old man (9)	30 tablets Nurofen Plus	Fanconi syndrome, K ⁺ 2.0, ↓ PO ₄	Reversible
45-year-old woman (10)	"Large quantity" Nurofen Plus	Fanconi syndrome, K ⁺ 2.6, ↓ PO ₄	Reversible
17-year-old woman (12)	25 tablets acetylsalicylate	Fanconi syndrome	Reversible
Single case (age and sex not reported) (13)	"Acute salicylate intoxication"	Aminoaciduria	Reversible

Nurofen Plus (ibuprofen 200 mg, codeine phosphate 12.8 mg); K⁺ (mEq/L).

Reversible aminoaciduria has also been reported as a manifestation of salicylate poisoning (13).

The mechanism by which these anti-inflammatory drugs give rise to proximal tubule dysfunction is not known. Impairment of mitochondrial function is likely to play a contributory role. Such an effect would decrease the energy source for the active transporters in this segment, thus contributing to a global decline in reabsorption of solutes.

Acetaminophen (paracetamol) toxicity (choice D) was a consideration in this case given the history that large quantities of an over-the-counter analgesic were being used for chronic headache. Renal dysfunction in the setting of acetaminophen overdose is most commonly a secondary complication of concomitant liver failure but can also occur in the absence of liver disease due to direct nephrotoxicity (14). Although there are no published reports of reversible proximal renal tubular acidosis with acetaminophen overdose, hypokalemia is a common electrolyte derangement observed in this setting (15–18). In a retrospective study of 155 patients with paracetamol overdose a dose-dependent relationship was found between the admission paracetamol concentration and the fall in serum K⁺ concentration (18). A similar finding was found in a prospective study of 41 cases of paracetamol overdose (18). In this study the fractional excretion of K⁺ and the transtubular K⁺ gradient 12 hours after ingestion were significantly correlated with the paracetamol concentration measured on admission, suggesting renal K⁺ loss was the source of hypokalemia.

Quetiapine is a dibenzothiazepine atypical antipsychotic with high affinity for serotonin 5-HT₂ receptors. A side effect of this drug is hyperventilation and development of respiratory alkalosis. The acid-base findings in this case exclude quetiapine (choice A) as the correct answer (19,20).

The neuroleptic malignant syndrome and secondary rhabdomyolysis (choice B) is a consideration given the recent addition of the antipsychotic risperidone to the patient's medical regimen. This disorder is characterized by muscle rigidity, tachycardia, skin cyanosis, and development of rhabdomyolysis typically 1 to 2 weeks after administration of an antipsychotic drug. Acid-base disturbances typically include an anion gap metabolic acidosis due to increased lactate production and respiratory acidosis due to increased CO₂ production. Hyperkalemia is commonly present due to leakage of K⁺ from damaged skeletal muscle. These features were not present in this case.

Pantoprazole is a proton pump inhibitor. Renal effects of this drug include the development of tubulointerstitial

renal disease, hyponatremia, and hypokalemia (21,22). The clinical features of the case make this choice an incorrect answer.

Disclosures

None.

References: Fluid and Electrolyte

- Bell AJ, Duggin G: Acute methyl salicylate toxicity complicating herbal skin treatment for psoriasis. *Emerg Med (Fremantle)* 14: 188–190, 2002
- Joss JD, LeBlond RF: Potentiation of warfarin anticoagulation associated with topical methyl salicylate. *Ann Pharmacother* 34: 729–733, 2000
- Maurer TA, Winter ME, Koo J, Berger TG: Refractory hypoglycemia: A complication of topical salicylate therapy. *Arch Dermatol* 130: 1455–1457, 1994
- Raschke R, Arnold-Capell PA, Richeson R, Curry SC: Refractory hypoglycemia secondary to topical salicylate intoxication. *Arch Intern Med* 151: 591–593, 1991
- Brubacher JR, Hoffman RS: Salicylism from topical salicylates: Review of the literature. *J Toxicol Clin Toxicol* 34: 431–436, 1996
- Yu T, Gutman A: A study of the paradoxical effects of salicylate in low, intermediate, and high dosage on the renal mechanism for excretion of urate in man. *J Clin Invest* 38: 1298–1315, 1959
- Palmer BF: Renal complications associated with use of non-steroidal antiinflammatory agents. *J Invest Med* 43: 516–533, 1995
- Chetty R, Baoku Y, Mildner R, Banerjee A, Vallance D, Had-don A, Labib M: Severe hypokalaemia and weakness due to Nurofen misuse. *Ann Clin Biochem* 40: 422–423, 2003
- Dyer BT, Martin JL, Mitchell JL, Sauven NC, Gazzard B: Hypokalaemia in ibuprofen and codeine phosphate abuse. *Int J Clin Pract* 58: 1061–1062, 2004
- Lambert AP, Close C: Life-threatening hypokalaemia from abuse of Nurofen Plus. *J R Soc Med* 98: 21, 2005
- Gaul C, Heckmann JG, Druschky A, Schocklmann H, Neundorfer B, Erbguth F: Renal tubular acidosis with severe hypokalemic tetraparesis after ibuprofen intake. *Dtsch Med Wochenschr* 124: 483–486, 1999
- Tsimihodimos V, Psychogios N, Kakaidi V, Bairaktari E, Elisaf M: Salicylate-induced proximal tubular dysfunction. *Am J Kidney Dis* 50: 463–467, 2007
- Andrews BF, Bruton OC, Knoblock EC: Aminoaciduria in salicylate intoxication. *Am J Med Sci* 242: 411–414, 1961
- Mazer M, Perrone J: Acetaminophen-induced nephrotoxicity: Pathophysiology, clinical manifestations, and management. *J Med Toxicol* 4: 2–6, 2008
- Waring WS, Stephen AF, Malkowska AM, Robinson OD: Acute acetaminophen overdose is associated with dose-dependent hypokalaemia: a prospective study of 331 patients. *Basic Clin Pharmacol Toxicol* 102: 325–328, 2008
- Zyoud S, Awang R, Syed Sulaiman SA, Al-Jabi S: High prevalence of hypokalemia after acute acetaminophen overdose:

- Impact of psychiatric illness. *Hum Exp Toxicol* 29: 773–778, 2010
17. Godber IM, Jarvis SJ, Maguire D: Hypokalaemia following paracetamol overdose in two teenage girls. *Ann Clin Biochem* 44: 403–405, 2007
 18. Pakravan N, Bateman DN, Goddard J: Effect of acute paracetamol overdose on changes in serum and urine electrolytes. *Br J Clin Pharmacol* 64: 824–832, 2007
 19. Shelton PS, Barnett FL, Krick SE: Hyperventilation associated with quetiapine. *Ann Pharmacother* 34: 335–337, 2000
 20. Jhaveri KD, Webber AB: The Case Triple acid-base disorder after drug abuse. *Kidney Int* 74: 1363–1364, 2008
 21. Hoorn EJ, van der Hoek J, de Man RA, Kuipers EJ, Bolwerk C, Zietse R: A Case series of proton pump inhibitor-induced hypomagnesemia. *Am J Kidney Dis* 56: 112–116, 2010
 22. Brewster UC, Perazella MA: Proton pump inhibitors and the kidney: Critical review. *Clin Nephrol* 68: 65–72, 2007

Presented at the Annual Meeting of the American Society of Nephrology on November 20, 2010

Published online ahead of print. Publication date available at www.cjasn.org.