

# Extended Follow-Up of Unruptured Intracranial Aneurysms Detected by Presymptomatic Screening in Patients with Autosomal Dominant Polycystic Kidney Disease

Maria V. Irazabal,\* John Huston III,<sup>†</sup> Vickie Kubly,\* Sandro Rossetti,\* Jamie L. Sundsbak,\* Marie C. Hogan,\* Peter C. Harris,\* Robert D. Brown, Jr.,\* and Vicente E. Torres\*

## Summary

**Background and objectives** Autosomal dominant polycystic kidney disease (ADPKD) patients have an increased risk for intracranial aneurysms (IAs). The importance of screening for unruptured IAs (UIAs) depends on their risks for growth and rupture.

**Design, setting, participants, & measurements** ADPKD patients with UIAs found by presymptomatic screening with magnetic resonance angiography (MRA) during 1989 to 2009 were followed initially at 6 months and annually, and less frequently after demonstration of stability.

**Results** Forty-five saccular aneurysms were detected in 38 patients from 36 families. Most were small (median diameter 3.5 mm) and in the anterior circulation (84%). Median age at diagnosis was 49 years. During cumulative imaging follow-up of 243 years, one *de novo* UIA was detected and increased in size from 2 to 4.4 mm over 144 months and two UIAs grew from 4.5 to 5.9 mm and 4.7 to 6.2 mm after 69 and 184 months, respectively. Seven patients did not have imaging follow-up. No change was detected in the remaining 28 patients. During cumulative clinical follow-up of 316 years, no aneurysm ruptured. Five patients died from unrelated causes and two were lost to follow-up after 8 and 120 months. Three patients underwent surgical clipping.

**Conclusions** Most UIAs detected by presymptomatic screening in ADPKD patients are small and in the anterior circulation. Growth and rupture risks are not higher than those of UIAs in the general population. These data support very selective screening for UIAs in ADPKD patients, and widespread screening is not indicated.

*Clin J Am Soc Nephrol* 6: 1274–1285, 2011. doi: 10.2215/CJN.09731110

## Introduction

Autosomal dominant polycystic kidney disease (ADPKD) is a common (prevalence 1 in 400 to 1000) multisystem, monogenic disorder, characterized by progressive development of bilateral renal cysts and specific extrarenal abnormalities including intracranial aneurysms (IAs). The rupture of an IA resulting in subarachnoid hemorrhage (SAH) is the most devastating extrarenal complication often resulting in premature death or disability (1). The prevalence of unruptured IAs (UIAs) in ADPKD has been estimated at approximately 8%; approximately five times higher than in the general population (1).

The high mortality and morbidity associated with rupture of an IA has prompted extensive discussion regarding the benefits of screening ADPKD patients for UIAs (1). High-resolution three-dimensional time-of-flight magnetic resonance angiography (MRA) is most commonly used (2,3). Although there is a significant volume of literature on the risk of rupture of asymptomatic UIAs in the general population (4,5), the risk of rupture in ADPKD patients is

less well defined. It is now known that patients with polycystic kidney disease 1 (PKD1) or polycystic kidney disease 2 (PKD2) are at risk of developing IAs. However, the relative risk of vascular complications in PKD1 compared with PKD2 is not known (6).

Data from our previous study in 2004 on 21 ADPKD patients with asymptomatic UIAs who underwent serial MRA showed that only one aneurysm increased in size without rupture and one additional aneurysm was first detected during a mean imaging and clinical follow-ups of 81 and 92 months, respectively (7). Since then, 19 additional ADPKD patients have been found to have an asymptomatic UIA by MRA screening. The aim of this study was to evaluate the rate of growth or rupture in this enriched cohort, to extend the observation period, and to genetically characterize the cohort.

## Materials and Methods

### Study Participants

We reviewed the medical records and MRA studies of all the patients with ADPKD and a diagnosis of

\*Division of Nephrology and Hypertension, and Departments of <sup>†</sup>Radiology and <sup>‡</sup>Neurology, Mayo Clinic, Rochester, Minnesota

### Correspondence:

Dr. Vicente E. Torres, Division of Nephrology and Hypertension, Mayo Clinic, Rochester, MN 55901. Phone: 507-284-7527; Fax: 507-266-9315; E-mail: torres.vicente@mayo.edu

**Table 1. Prevalence of UIA by age group**

Age Group (years)	Patients Screened (Men:Women) Number	Patients with UIA Number (Men:Women)	Prevalence by Age (%)
<20	2 (0:2)	0	0
20 to 29	24 (7:17)	1 (1:0)	4.2
30 to 39	43 (15:28)	4 (0:4)	9.3
40 to 49	135 (58:77)	15 (5:10)	11.1
50 to 59	114 (48:66)	10 (5:5)	8.8
≥60	89 (43:46)	8 (4:4)	9.0
Total	407 (171:236)	38 (15:23)	9.3 <sup>a</sup>

<sup>a</sup>95% CI, 6.9% to 12.6%.

UIA established by presymptomatic screening at the Mayo Clinic between 1989 and 2009. Exclusion criteria included all patients with a new UIA that had a past history of SAH or surgical clipping of a previous UIA, patients that had

neurologic symptoms at the time of the UIA diagnosis, or patients in whom the UIA diagnosis was made elsewhere. During 2009, two patients were found to have 1.4- and 1.5-mm lesions on a presymptomatic MRA screening.

**Table 2. Baseline clinical parameters and genetic analysis**

Pedigree	Mutation	Age	Gender	Family History UIA/SAH	Smoker	Hypertension	Hyperlipidemia
<i>PKD1</i>							
M42	L3682Q	63	M	SAH	N	Y	N
M69	Q164R	45	F	SAH	N	Y	Y
M32*	Q2243X	49	F	UIA	Y	Y	N
M32**	Q2243X	29	M	UIA	N	Y	Y
M32***	Q2243X	51	F	UIA	Y	Y	Y
M72	6726delAC	45	F	SAH	N	Y	N
M35	C508R	36	F	None	Y	Y	Y
M234	IVS17 + 4del4	41	M	UIA	N	Y	Y
M135	Y2336X	52	M	None	N	Y	Y
M93	F3168L	67	F	SAH	N	Y	Y
M540	S2423F	44	F	SAH	N	Y	N
M538	W3603X	58	M	SAH	N	Y	N
M541	IVS3 + 2T>C	48	F	None	Y	Y	N
M368	108_109insC	48	F	SAH	N	Y	N
M80	F3168L	45	F	UIA + SAH	Y	Y	Y
M536	T2250M, S1619F <sup>a</sup>	42	M	None	Y	Y	N
M539	R2430X	58	M	None	N	Y	Y
M532	Q2637X	51	F	UIA	N	Y	Y
M524	9240_9241delAT	44	F	SAH	Y	Y	Y
M374	Q266X	44	F	None	N	Y	N
M521	Y528C	60	M	None	N	Y	Y
<i>PKD2</i>							
M13	825delC	72	F	SAH	N	Y	Y
M393	IVS13-1G>A	39	F	None	Y	Y	N
M533	R872X	70	F	None	N	Y	Y
M528	R654X	68	M	SAH	Y	Y	Y
Mutation not detected							
M542	NA	66	F	None	N	Y	Y
Not determined							
P4	NA	52	M	None	Y	Y	N
P7	NA	37	F	None	N	Y	N
P8	NA	47	F	SAH	Y	Y	N
P9	NA	59	F	None	N	Y	Y
P13	NA	33	F	None	N	Y	Y
P18	NA	61	M	SAH	Y	Y	Y
P19	NA	58	F	SAH	Y	N	N
P22	NA	54	M	None	Y	Y	Y
P31	NA	49	M	None	N	Y	Y
P32	NA	43	M	None	Y	Y	Y
P34	NA	45	M	None	Y	Y	N
P36	NA	59	F	None	Y	Y	N

Y, yes; N, no; NA, not applicable.

<sup>a</sup>Two weakly scoring mutations, possible hypomorphic alleles, were detected.

These two patients were not included in the results of this study because their lesions do not qualify under our definition of new UIAs. However, because of the characteristics of the lesions, these patients will be followed with the same criteria used for the patients in the study. Two patients from our previous report (3,7) were excluded after their MRA studies were reviewed and the lesions initially thought to be UIAs were shown to be infundibula. To estimate the prevalence of UIAs detected by presymptomatic screening in ADPKD patients, we reviewed all ADPKD patients who were screened for asymptomatic UIAs with MRA between 1989 and 2009 at the Mayo Clinic.

Possible risk factors for aneurysmal growth/rupture such as positive family history of UIAs or SHA, presence of hypertension, hyperlipidemia, or the use of tobacco were also reviewed.

#### MRA Screening and Intracranial Aneurysm Assessment

MRA screening was offered to all ADPKD patients seen between 1989 and 1992 (8). After 1992, screening was performed for clinical indications, usually a family history of IA or SAH or preparation for major elective surgeries. The screening technique was three-dimensional time-of-flight MRA. Patients were examined using 1.5- and 3.0-T Super-

**Table 3. Baseline and follow-up MRA findings**

Pedigree	Aneurysm Location	Dia Meter (mm)	Number of MRA Follow-Up Studies	MRA Follow-Up Months	Clinical Follow-Up Months	Change in Imaging Findings (Y/N)
<i>PKD1</i>						
M42	Right MCA	3	3	36	44	N
M69	Basilar tip	2	10	253	273	N
M32*	Right ICA	6	5	223	223	N
M32**	Right MCA	3	7	208	215	N, new left MCA; increased from 2 to 4.4 mm
M32***	Right MCA	3	3	94	100	N
	Left MCA	3	–	–	–	N
M72	Left superior cerebellar	4.7	10	184	184	Increased to 6.2 mm
M35	Right ICA	3.5	5	186	186	N
	Right ophthalmic	2	–	–	–	N
M234	ACoA	3	8	172	176	N
M135	ACoA	6	0	0	70	Not restudied
M93	Right ACA	3.5	0	0	11	Not restudied
M540	Left carotid siphon	3	6	164	164	N
M538	Left MCA	4	3	28	34	N
	Right MCA	6.0	–	–	–	N
M541	Left ICA	5.7	1	57	63	N
M368	Right superior cerebellar	2	1	15	21	N
	Right ICA	3	–	–	–	N
M80	Right superior cerebellar	2.0	10	216	228	N
M536	Left superior cerebellar	3	2	15	128	N
M539	ACoA	10	2	15	37	N
M532	Left ICA	3	1	58	58	N
M524	Right MCA	3	4	42	50	N
M374	Right MCA	5.2	4	38	46	N
M521	Right MCA	4	3	63	73	N
	Left MCA	5	–	–	–	N
<i>PKD2</i>						
M13	Left carotid siphon	2.0	6	132	160	N
M393	Basilar tip	3	3	38	56	N
M533	Left ICA	3.3	2	35	84	N
M528	Right MCA	4	1	13	24	N
Mutation not detected						
M542	Left MCA	6	0	0	9	Not restudied
Not determined						
P4	Left carotid siphon	6.5	0	0	1	Not restudied
P7	Left carotid siphon	3	3	48	120	N
P8	Right MCA	5	0	0	75	Not restudied
P9	Right carotid siphon	4.0	5	210	227	N
P13	Right MCA	6.5	3	126	132	N
P18	Right pericallosal	6.0	4	61	72	N
	Right MCA	3.0	–	–	–	N
P19	Basilar tip	3	1	17	72	N
P22	Left ICA	3	0	0	39	Not restudied
P31	Left MCA	3	0	0	33	Not restudied
P32	ACoA	5	2	36	48	N
P34	ACoA	4.5	3	99	171	Increased to 5.9 mm
P36	Left MCA	9.8	1	32	78	N
	Right ICA	3.5	–	–	–	N

conducting Imaging Systems (Signa, GE Medical Systems, Milwaukee, WI). Standard MR imaging of the head was performed with sagittal T1-weighted and transaxial T2-weighted sequences. In addition, high-resolution 3-mm transaxial T1-weighted imaging through the circle of Willis was obtained. The 1.5-T time-of-flight technique includes a 38/3.4 (TR/TE), 1.4-mm section thickness (zero filled for 0.7 mm overlap), 32 sections per slab with 6-section overlap, 18-cm field of view, 25° flip angle, 384 × 224 matrix with 512 zero filling in frequency and phase encoding directions, and the use of magnetization transfer. MRA techniques have evolved during the period of this study. Currently, 3.0-T time-of flight MRA offers the highest quality imaging for detecting and characterizing UIAs.

Maximum intensity projection postprocessing was performed by isolating the right-carotid, left-carotid, and posterior circulations. Care was taken to include the anterior communicating artery (AcoA) in both carotid volumes. This subvolume technique was necessary to optimally display the arterial vasculature and to eliminate overlapping vessels. Correlation between viewing the subvolumes in a cine loop at an independent workstation and with the source images facilitated identification and characterization of the aneurysms. A saccular UIA was diagnosed when a focal, asymmetric outpouching of an artery with a discrete base was detected.

ADPKD patients found to have an UIA by MRA screening were followed initially at 6 months and annually, and

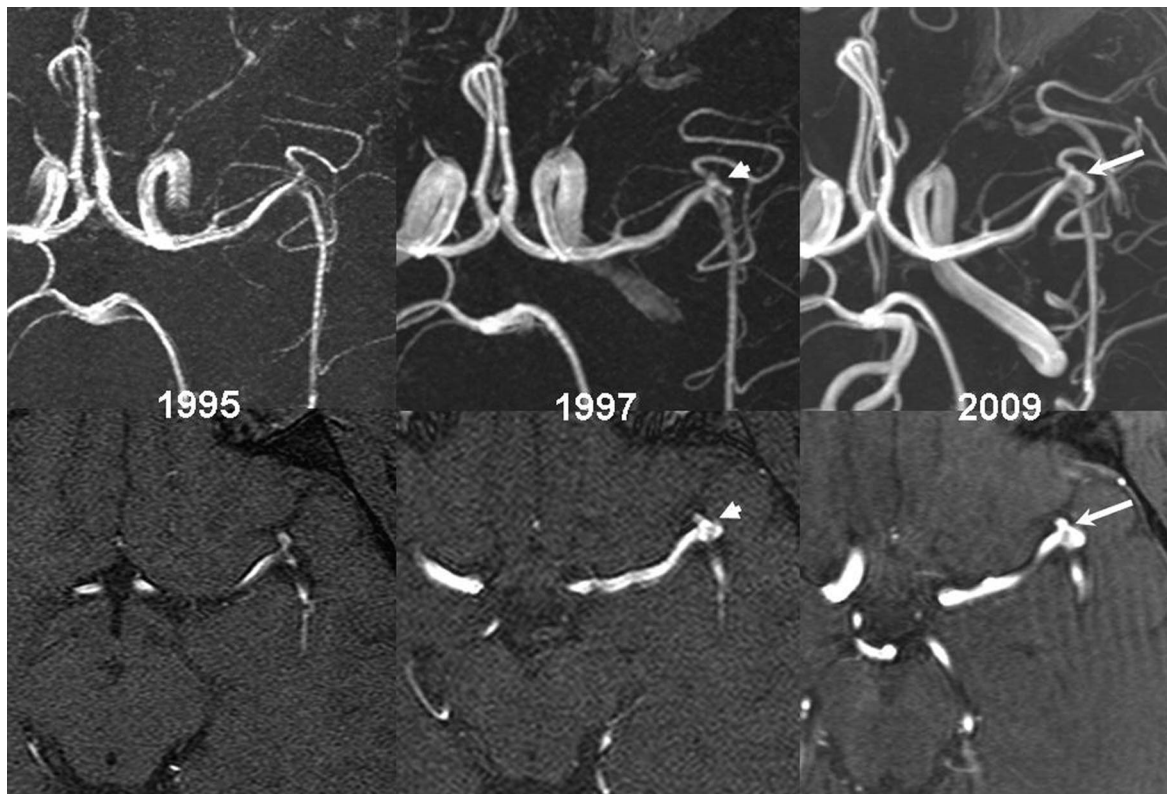
then less frequently after demonstration of stable UIA diameter. All MRA studies were reviewed and UIAs were remeasured to eliminate possible measurement technique differences with the previous report.

#### Mutation Analysis

Mutations were described previously (6,9) or were newly detected here. The technique utilized for mutation analysis has been described previously (9). Briefly, all *PKD1* and *PKD2* exons were amplified as 68 separate fragments from genomic DNA or from *PKD1*-specific fragments for the duplicated region of *PKD1*. Fragments were analyzed by direct sequencing. Where samples were available, segregation analysis was used to confirm that the sequence change segregated with the disease. Putative missense changes were evaluated as described previously (ADPKD Mutation Database 2010 [http://pkdb.mayo.edu]) (9).

#### Data Handling and Statistical Considerations

A new UIA was defined as a previously undetected IA if it was  $\geq 2$  mm in diameter. A previously existing UIA was considered to have enlarged if the maximum transverse measurement had increased by  $\geq 1$  mm on a follow-up MRA. Imaging follow-up was defined as the period from the first MRA at which the UIA was detected to the date of the last MRA. Clinical follow-up was defined as the period from the first MRA at which the UIA was detected to the



**Figure 1.** | Twenty-nine-year-old man (M32\*\*) found to harbor a 3-mm right MCA trifurcation aneurysm in 1995. The patient returned in 1997 for a follow-up MRA that demonstrated stability of the right MCA trifurcation aneurysm but development of a *de novo* 2-mm mirror left MCA trifurcation aneurysm (arrowhead). Subsequent imaging showed enlargement of the left MCA trifurcation aneurysm to a size of 4.4 mm in 2009 (arrow).

date at which time subjects were last seen at the clinic or contacted by telephone to confirm their survival and provide information regarding any new neurologic event, including aneurismal rupture or surgery. Family history of UIA or SAH was considered positive only when present in first-degree relatives. Hypertension was defined as a history of treatment of elevated BP or the continuing presence of a BP  $\geq$ 130/80 mmHg before UIA diagnosis. Hyperlipidemia was defined as a history of treatment of elevated blood lipids or the presence of serum total cholesterol  $\geq$  240mg/dl, serum triglycerides  $\geq$  200 mg/dl, or serum LDL  $\geq$  160 mg before the time the UIA was diagnosed.

Data are presented as means ( $\pm$ SD) or medians (range) when appropriate. All statistics were performed using JMP software, version 8.0 (SAS Institute, Inc., Cary, NC).

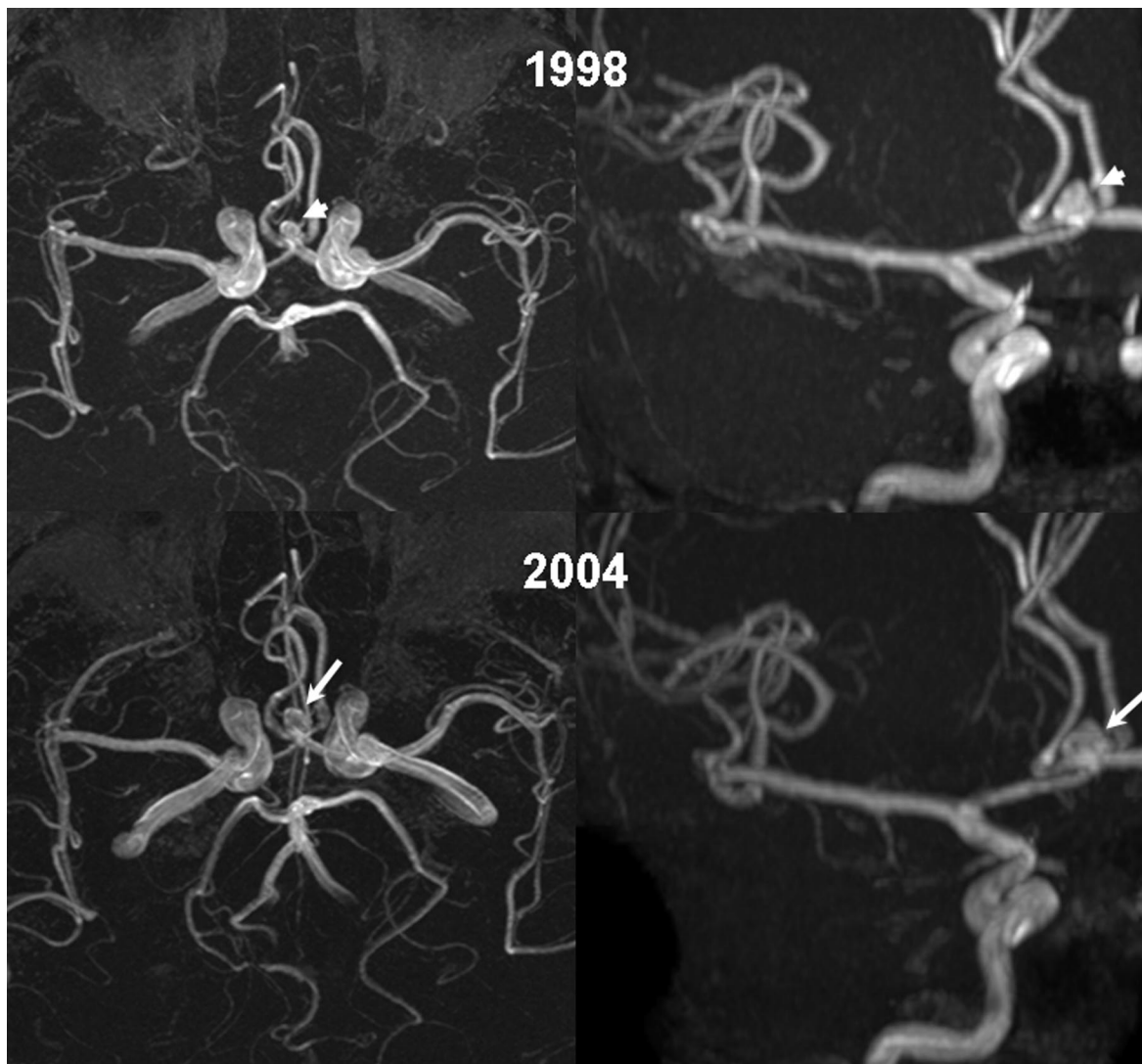
## Results

### Baseline Clinical Parameters and Genetic Analysis

Four hundred and seven ADPKD patients (171 men and 236 women) were screened with MRA for asymptomatic

IA between 1989 and 2009 at the Mayo Clinic. Ninety (22.1%) of the patients had at least one family member with history of IA or SAH (19 patients had two or more), 300 (73.7%) patients did not have such a history, and in 17 (4.2%) patients family history of IA or SAH could not be determined. One hundred and seventy-one (42.0%) of the patients had been smokers or were active smokers at the time of the screen. Thirty-seven patients (9.1%) were/had been smokers and had a family history of IA or SAH.

The prevalence of asymptomatic IA detected by presymptomatic screening with MRA in ADPKD patients was estimated at 9.3% (95% confidence interval [CI] 6.9% to 12.6%). Nineteen patients had family history of UIA ( $n = 5$  [13.1%]), SAH ( $n = 13$  [34.2%]), or both ( $n = 1$  [2.6%]) at the time of the UIA diagnosis. These 19 patients were among the 90 patients that had family history of IA or SAH at the time of the screen. Therefore, the prevalence of UIA among ADPKD patients with a family history of IA, SAH, or both was estimated at 21.1% (95% CI, 14.0% to 30.6%) and the prevalence of UIA



**Figure 2.** | Forty-five-year-old man (P34) was found to have a 4.5-mm AcoA aneurysm identified on screening MRA in 1998 (arrowhead). Subsequent MRA demonstrated enlargement to 5.9 mm in 2004 (arrow).

among ADPKD patients without such a history was estimated at 6.3% (95% CI, 4.1% to 9.7%).

The median age of the study population at the screening time was 50 (range 17 to 82) years of age. Thirty-eight patients (15 men and 23 women) from 36 families were found to have UIAs. The median age at diagnosis of the patients found to have an UIA was 49 (range 29 to 72) years: 48 (range 33 to 72) years for women and 52 (range 29 to 68) years for men. The prevalence rate of UIAs by age group is presented in Table 1.

The baseline clinical and genetic characteristics for all of the study participants are shown in Table 2. The genotype was *PKD1* in 21 patients (80.8% of the 26 screened patients), *PKD2* in four patients (15.4%), and in one (3.8%) patient the mutation could not be identified. The genotype was not determined in 12 patients because of no DNA availability. Seventeen patients were or had been smokers at the time of the first MRA, and of those five continued to be active smokers. Hypertension was present in 37 patients (32 treated with angiotensin I converting enzyme inhibitors, angiotensin II receptor blockers, or both, and five with other antihypertensive medications). Twenty-two patients had hyperlipidemia (16 treated with statins and the remaining were managed with diet alone).

#### Baseline MRA Findings

The baseline and follow-up MRA findings are summarized in Table 3. Forty-five saccular aneurysms were detected at the time of the initial evaluation (27 UIAs in 23 women, 18 UIAs in 15 men). Seven patients (18.4%) had two aneurysms on their first MRA (four were women, three were men). Most UIAs were small, with a median diameter of 3.5 mm at diagnosis (range 2.0 to 10.0 mm). In women, the median diameter was 3 mm (range 2.0 to 9.8 mm), and in men the median diameter was 4 mm (range 3.0 to 10.0 mm) at the time of diagnosis. Two UIAs had a diameter  $\geq 7$  mm at baseline (a 9.8-mm middle cerebral artery [MCA] aneurysm in a woman with another UIA in the internal carotid artery (ICA), a 10-mm ACoA aneurysm in a man). Neither of them had a family history of UIA or SAH, but both were hypertensive. Thirty-eight (84.4%)

UIAs were in the anterior circulation, with 17 located in the MCA, 13 in the ICA, five in the ACoA, two in the anterior cerebral artery (ACA), and one in the ophthalmic artery. Only seven (15.6%) of the UIAs were in the posterior circulation (four in the superior cerebellar artery and three in the basilar artery). Of the 27 UIAs detected in women, 21 (77.8%) were in the anterior circulation and 6 (22.2%) were in the posterior. Of the 18 UIAs in men, 17 (94.4%) were in the anterior circulation and one (5.5%) was in the posterior ( $P = 0.22$ ).

#### Long-Term MRA and Clinical Follow-Up

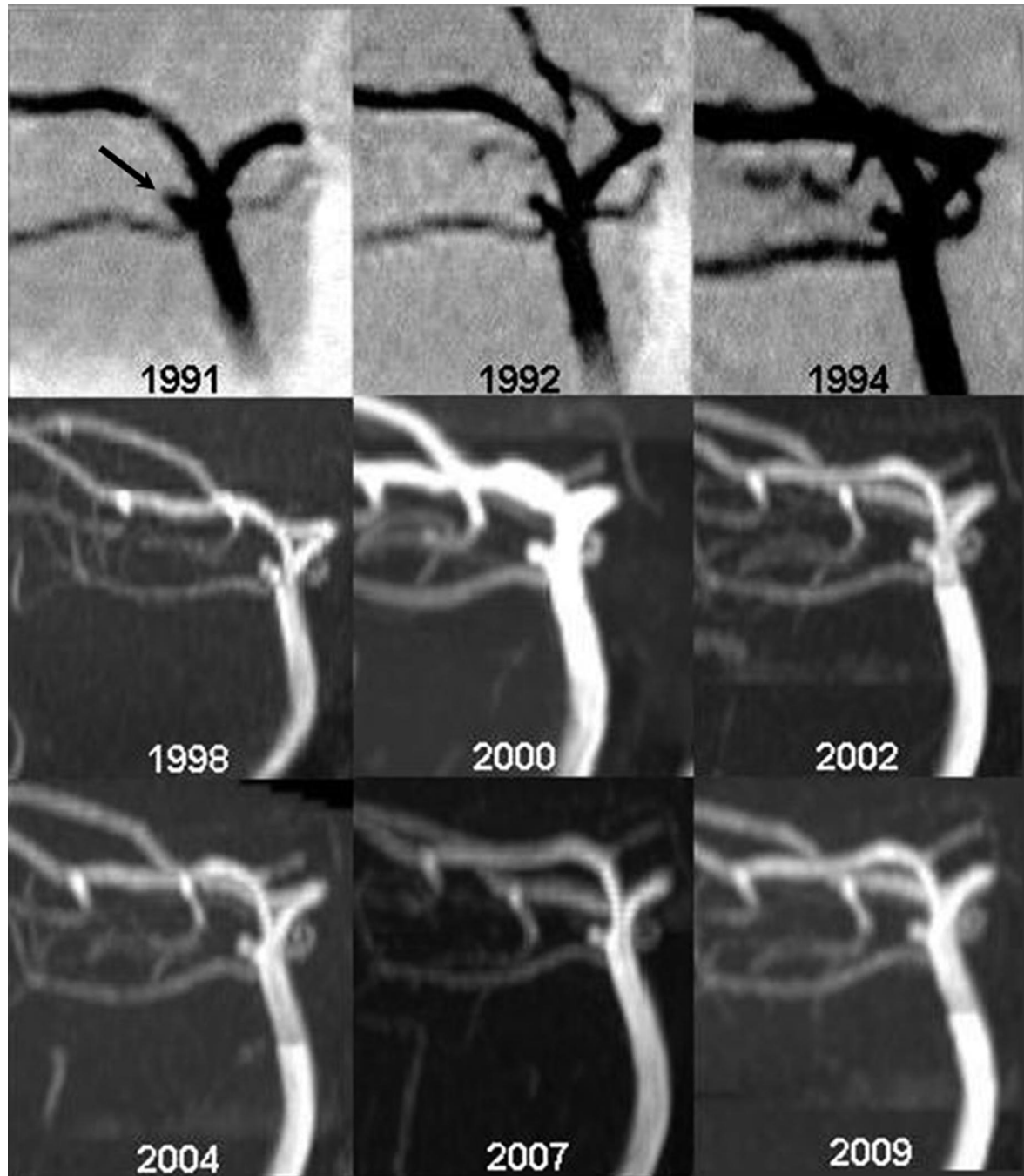
During a cumulative imaging follow-up of 243 years, one *de novo* UIA (MCA) was detected and increased in size from 2 to 4.4 mm over 144 months (M32\*\*) (Figure 1). An UIA (ACoA) in a second patient grew from 4.5 to 5.9 mm after a follow-up of 69 months (P34) (Figure 2), and another UIA (superior cerebellar) in a third patient grew from 4.7 to 6.2 mm after a follow-up of 184 months (M72) (Figure 3). No change was detected in the other 28 patients who had at least two MRA studies. The mean number of MRA follow-up studies in these 31 patients was  $4.0 \pm 2.7$  (median 3.0, range 1 to 10). Figures 4 and 5 show serial MRAs of four patients performed over intervals of 17 to 18 years illustrating the stability of these aneurysms. Seven patients did not have imaging follow-up (two died from unrelated causes shortly after diagnosis, two had only clinical follow-up, and three were recently diagnosed).

During a cumulative clinical follow-up of 316 years (mean  $7.9 \pm 6.2$  years), no aneurysm ruptured. Five patients died from unrelated causes (two from posttransplant lymphoproliferative disorder, two after discontinuation of dialysis, and one in a motor vehicle accident) and two patients were lost to follow-up (one after a clinical follow-up of 8 months and the other after 48 and 120 months of imaging and clinical follow-up, respectively).

Three patients underwent surgical clipping of their UIA during the period of the study: a 10-mm ACoA, a 3-mm basilar, and a 5-mm MCA UIA (Table 4). No growth or new UIAs were detected in these three patients before or after surgical clipping of their UIAs. A 59-year-old patient

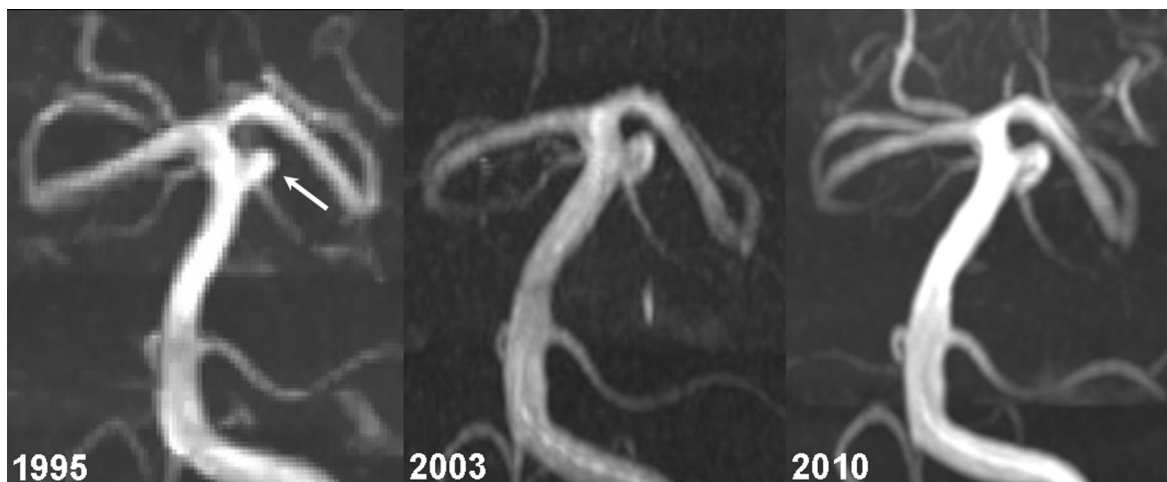

Figure 3. | Forty-five-year-old woman (M72) with a family history of SAH was found to have a 4.7-mm left superior cerebellar artery aneurysm during screening in 1995. Subsequent imaging demonstrated slight enlargement to a maximal size of 6.2 mm in 2010.

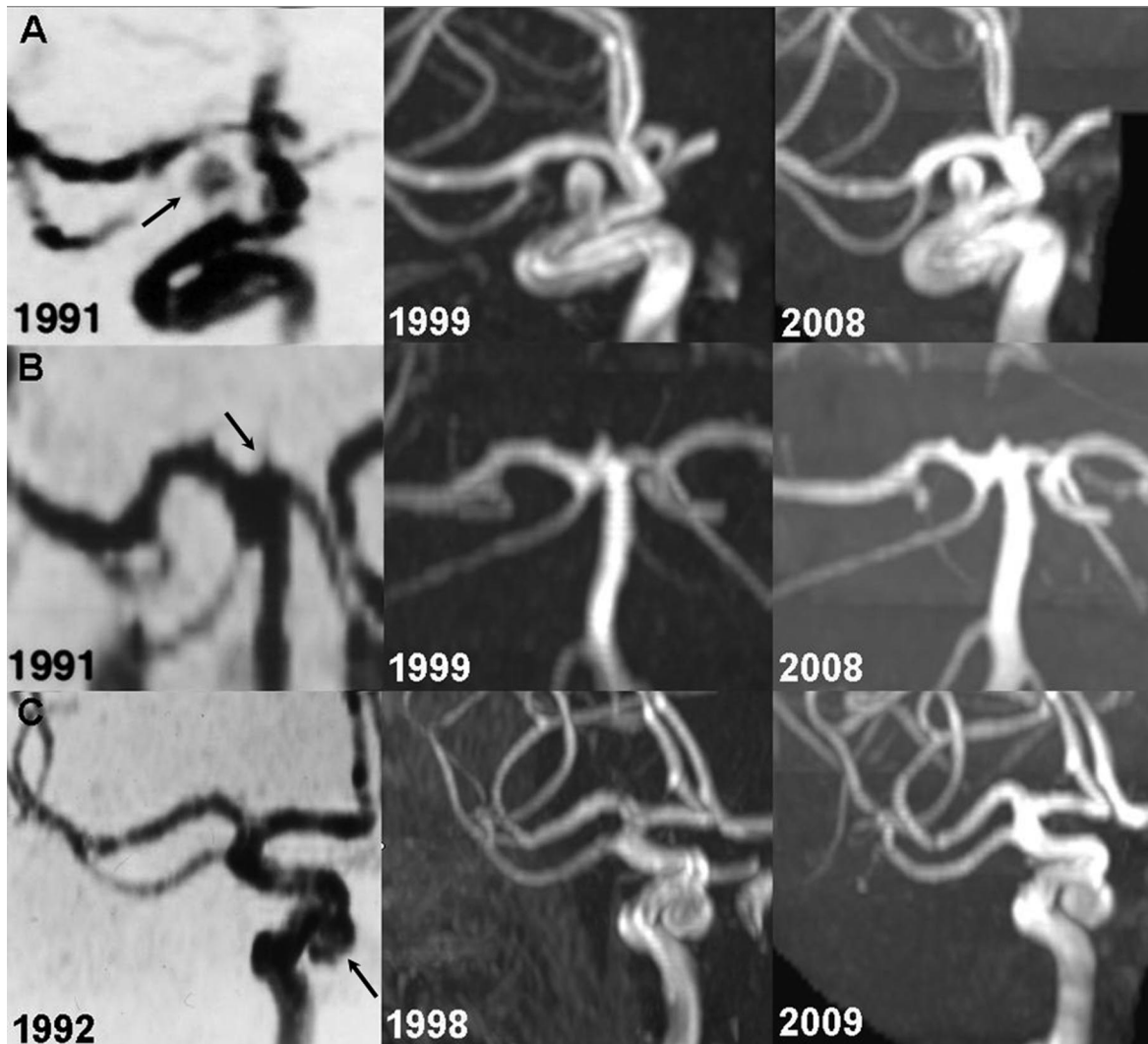


**Figure 4.** | Serial MRAs of a 2.0-mm right superior cerebellar aneurysm (arrow) in a 45-year-old woman (M80). No change was seen in aneurysm size or morphology between 1991 and 2009. Before 2000, MRAs were performed using a magnetic field strength of 1.5 T; subsequent studies were performed at 3.0 T.

with a 9.8-mm MCA and a 3.5-mm ICA decided not to have endovascular embolization or surgery after neurologic consultation and a thorough discussion of indications, risks, and benefits of the interventions. There was no significant change in the UIAs on a follow-up MRA 31 months later and the patient declined further imaging studies. At the time of the last clinical follow-up 78 months after diagnosis, she had not developed any neurologic symptoms.

### Discussion

Intracranial, thoracic aortic, and other aneurysms are among the most common manifestations of ADPKD (1). They are characterized by the disruption of elastic tissue in the aneurismal wall, the internal elastic lamina at the neck of a saccular aneurysm, and the elastic lamellae in the tunica media of a thoracic aortic aneurysm. Strong polycystin-1 and polycystin-2 expression in the vascular smooth muscle (10–12) and endothelium (13) and in-



**Figure 5.** | A series of patients with stable aneurysms (arrows). (A) A 59-year-old woman (P9) before a major surgery in 1991 was found to have a 4.0-mm right carotid siphon aneurysm that was unchanged during 17 years of follow-up. (B) A 45-year-old woman (M69) with a family history of SAH screened with MRA was found to have a 2.0-mm basilar tip aneurysm that remained unchanged between 1991 and 2008. (C) A 49-year-old woman (M32\*) with a family history of IA who underwent screening before a kidney transplant was found to have a 6.0-mm right carotid siphon aneurysm in 1992. Subsequent follow-up has not shown a significant change in the size of the aneurysm.

creased development or susceptibility to develop aneurysms in *Pkd1* and *Pkd2* mouse models (14,15) suggest that these vascular lesions are directly linked to the *PKD* mutations and polycystin dysfunction in the arterial wall and are not just a secondary manifestation because of arterial hypertension associated with ADPKD.

The association of IA and ADPKD was established first by a large autopsy series and was more recently confirmed by conventional and MRA studies (8,16–18). The prevalence in ADPKD has been estimated at approximately 8%, 5 times that in the general population. In our study, the estimated prevalence of UIA detected by presymptomatic screening was 9.3% (95% CI 6.9% to 12.6%). In addition, it has been previously reported that the prevalence of IA is higher in ADPKD patients with a family history of IA or SAH (approximately 16%) than in those without such a history (approximately 6%) (1). Our findings of a prevalence of 21.1% in patients with family history of IA or SAH

and 6.3% in patients without history are in accordance with the previous reports. These are slightly higher than those reported in non-ADPKD patients with one (2.6% to 5.8%) or two or more (3.9% to 14%) first-degree family members with a history of IA or SAH (19). The 16% to 21% prevalence in ADPKD patients with a family history of IA or SAH is similar to that observed in non-ADPKD individuals with two or more first-degree relatives with a history of IA or SAH plus a personal history of smoking or hypertension (approximately 19%) (20).

Given the catastrophic nature of aneurysmal rupture, with a mortality of 30% to 40% and serious sequelae in an additional 30% of patients, early detection and pre-emptive treatment of UIAs has attracted much attention. The goal of presymptomatic screening is to identify patients with a risk for SAH that exceeds the risk of an interventional procedure to prevent rupture. Quantification of these risks is difficult because of the lack of randomized



**Table 4. Baseline clinical parameters, genetic analysis, and baseline follow-up MRA findings on patients with clipped UIAs**

	Pedigree		
	M393	M539	M374
Genotype/mutation	<i>PKD2/IVS13-1G&gt;A</i>	<i>PKD1/R2430X</i>	<i>PKD1/Q266X</i>
Age	39	58	44
Gender	F	M	F
Family history IA/SAH	None	None	None
Smoker	Y	N	N
Hypertension	Y	Y	Y
Hyperlipidemia	N	Y	N
Indication for MRA screen	Preparation for major surgery	Preparation for major surgery	Preparation for major surgery
Aneurysm location	Basilar tip	ACoA	Right MCA
Diameter (mm)	3	10	5.2
Time from diagnosis to clipping (months)	38	3	38
Number MRA studies follow-up (after diagnosis)	3	2	4
MRA follow-up months	38	15	38
Clinical follow-up months	56	37	46
Change in imaging findings before or after clipping (Y/N)	N	N	N

controlled trials. The available data are derived from retrospective or from prospective but not randomized studies. Most of the data are from studies in the general population that may or may not be applicable to patients with ADPKD.

The study presented here suggests that the risk of growth of small UIAs detected by presymptomatic screening in a relatively young population of ADPKD patients is very low. A few studies have ascertained the risk of growth of UIAs in non-ADPKD individuals using MRA (21–24). Patients in these studies were in general older, and many had a previous history of SAH or various neurologic symptoms and therefore are not comparable to the ADPKD patients in the study presented here, who were strictly diagnosed by presymptomatic screening. Two Japanese studies, in 140 and 130 patients with mean ages of 62.8 and 68.8 years, respectively, demonstrated aneurysmal growth in 6.4% (22) and 10.8% (23), respectively, after mean follow-up of 17.7 and 29.3 months, respectively. The risk of growth correlated with the size of the aneurysm and was less in those <5 mm in diameter. A Dutch study in 93 patients with a mean age of 51 years and 125 UIAs measuring <5 mm (67 with a history of SAH, 16 with at least two relatives with UIA or SAH, and ten with both) showed slight enlargement (0.5 to 1.5 mm) in 3.2% of the patients after a mean follow-up of 15 months (24). Recently we (J.H, III, R.D.B.) retrospectively identified 165 patients with 191 UIAs and a mean age of 64 years and followed with serial MRA. Ten percent of aneurysms grew over a median follow-up of 47 months. The frequency of enlargement was 6.9%, 25%, and 83% for aneurysms <8 mm, 8 to 12 mm, and ≥13 mm, respectively (21). Aneurysm diameter was the only independent predictor of enlargement. These studies suggest that the risk of growth of UIAs detected by presymptomatic screening in ADPKD patients, as re-

ported herein, is not higher than that of UIAs in the general population.

The risk of rupture of UIAs remains controversial. Table 5 summarizes the published studies with more than 1000 patient-years of follow-up. A landmark study by Wiebers *et al.* excluded patients with a previous history of SAH from another aneurysm (25). The overall rupture risk was 1.4% per year, but strikingly no aneurysm measuring <10 mm in diameter ruptured. This publication was followed by several reports from neurosurgical centers in Japan and Finland (26–28). Patients in these studies were mostly identified when a ruptured aneurysm was clipped and other UIAs were left untreated. The overall risk of rupture ranged from 1.3% to 2.3% per year and correlated with the size of the aneurysms. In contrast to the study by Wiebers *et al.*, small aneurysms, even those measuring ≤5 mm in diameter, also ruptured. The International Study of Unruptured Intracranial Aneurysms (ISUIA) is the largest study that addressed the risk of rupture of UIAs. ISUIA I was retrospective in nature, with 12,023 patient-years of follow-up (4). Approximately one-half of the patients had a history of SAH. The overall risk of rupture was 0.3% per year. The yearly risk was very small (0.05%) for aneurysms measuring <10 mm in diameter without a previous history of SAH and (0.5%) in those with a previous history of SAH. ISUIA II was prospective, but not randomized, with 6544 patient-years of follow-up (5). The cumulative 5-year risk of rupture for patients without a history of SAH and with aneurysms located in the ICA, ACoA, ACA, or MCA were 0%, 2.6%, 14.5%, and 40% for aneurysms <7, 7 to 12, 13 to 24, and ≥25 mm, respectively, compared with rates of 2.5%, 14.5%, 18.4%, and 50%, respectively, for the same size categories involving the posterior circulation or posterior communicating artery. Although the study presented here with only 316 patient-years of follow-up is much smaller than those listed in Table 5, the absence of rupture in UIAs

Table 5. Risk of rupture of UIAs in studies with more than 1000 patient-years

Study	Type	Patients (n)	Patient-Years	History of SAH (%)	Rupture Risk (% per year)	Rupture Risk per Size and History of SAH (% per year)
Wiebers, 1987 (25)	Retrospective	130	1079	0	1.4	0 (<10 mm) 3.3 (10 to 15 mm) 5.6 (16 to 25 mm) 8.9 (>25 mm)
Yasui, 1997 (28)	Retrospective	234	1465	60	2.3	Size effect not studied
Juvela, 2000 (27)	Retrospective	142	2575	90	1.3	1.1 (2 to 6 mm) 2.3 (7 to 9 mm) 2.8 (10 to 26 mm)
Ishibashi, 2009 (26)	Prospective, nonrandomized	419	1312	NA	1.4	0.8% ( $\leq$ 4.9 mm) 1.2% (5 to 9.9 mm) 7.1% (10 to 25 mm) 43.1% (>25 mm)
ISUIA I, 1998 (4)	Retrospective	1449	12,023	50	0.3	0.05 (<10 mm, no SAH) 0.5 (<10 mm, history SAH)
ISUIA II, 2003 (5)	Prospective, nonrandomized	1692	6544	36	0.7	Depending on size, history of SAH, and location

in these patients, mainly in the anterior circulation and measuring <7 mm in diameter, is consistent with the observations of ISUIA II. Our study suggests that the risk of rupture of UIAs discovered by presymptomatic screening in ADPKD patients is low and likely not markedly different from that of UIAs in the general population.

Other factors that affect the risk of aneurysmal rupture are a family history of SAH, smoking, and hypertension (29). In the Swedish Inpatient Registry Study, the risk of SAH in individuals with one or two or more affected relatives was 2.15 and 51 times higher, respectively, than that of individuals with no affected relatives (30). In the Familial Intracranial Aneurysm Study, the yearly risk of rupture of patients with at least two siblings or three relatives with known history of IA or SAH who were also smokers or had hypertension was 1.2%, approximately 17 times higher than the rupture rate for subjects with an UIA in the ISUIA with a matched distribution of IA size and location (31). In the study presented here, 50% of the patients had a family history of IA or SAH, a high frequency because a strong family history of IA or SAH is an indication for presymptomatic screening at our center. Forty-five percent of the patients had been or were active smokers and 97.4% had hypertension. The absence of aneurysmal rupture despite these risk factors further suggests that the risk of rupture of UIAs in ADPKD patients is not markedly increased compared with that of UIAs in the general population. Nevertheless, it is important to recognize these risk factors as additional reasons for emphasizing strict BP control and smoking cessation in the management of these patients.

The effectiveness of presymptomatic screening for IAs depends not only on the risk of rupture, but also on the risk and effectiveness of the interventions (surgical clipping or intravascular coiling) to exclude them from the circulation. Mortality and major morbidity for surgery in different studies range between 0.6% and 3.5% and between 4.1% and 25.4%, respectively (5,32–36). They are somewhat higher than those for endovascular coiling that range between 0.5% and 3.1% and between 6.4% and 9.7%, respectively. The risk of intervention increases with size and location of the aneurysm in the posterior circulation and with the age of the patient. None of these studies were prospective, randomized studies and the rates likely depend on the expertise of the centers. Whether the risk of intervention in ADPKD patients is different from that in patients without ADPKD is not known.

The fact that these interventions do not entirely eliminate the risk of SAH adds another layer of complexity. Incomplete occlusion occurs in 5% of clipped and 15% to 30% of coiled aneurysms (37,38). The risk of regrowth of a successfully clipped aneurysm is 0.26% to 0.52% per year (39). In addition, patients with aneurysms have a 0.89% to 1.8% risk of *de novo* aneurysm formation (40).

On the basis of the observations during this extended follow-up of UIAs detected by presymptomatic screening in ADPKD patients and new information published since our previous report in 2004 (7), our approach to presymptomatic screening and management of UIAs in ADPKD patients remains essentially the same. Because most aneurysms detected by presymptomatic screening are small and have a low risk of rapid growth or rupture, we do not recommend presymptomatic screening for UIAs for patients with a negative family history of SAH or family

members with multiple UIAs. Screening MRA (or computer tomographic angiography) is offered to those patients with a family history of documented aneurysmal rupture because of the higher prevalence of UIAs and possible increased risk of aneurysmal rupture in this population. We also offer screening with MRA or computer tomographic angiography to those with multiple family members with IAs. If the screening MRA is negative, re-screening of patients with good life expectancy at 5-year intervals seems reasonable. We also recommend screening before major elective surgeries and in patients with high-risk occupations (e.g., airline pilot, bus driver), in whom a loss of consciousness because of a ruptured IA would place the life of others at risk.

If an aneurysm is detected by presymptomatic screening, recommendations are dependent on patient age, overall medical status, and numerous aneurysmal factors. Decisions regarding the management of UIAs are complex, and multiple factors need to be considered, including size, site, prior history of SAH from another aneurysm, aneurysm morphology, patient age and general health, and whether the aneurysm is coilable or clippable (41). The results of this study support conservative management of ADPKD patients with small (particularly those measuring <7 mm), anterior circulation asymptomatic IAs detected by presymptomatic screening. After considering all aneurysm and patient characteristics, should intervention be indicated, then the decision regarding endovascular or surgical management should be based on a multidisciplinary review. For untreated small aneurysms, annual or semiannual repeat imaging studies are appropriate initially, but re-evaluation at less frequent intervals may be sufficient once the stability of the size of the UIA has been documented. Patients should be advised to eliminate tobacco use and aggressively treat hypertension to minimize the risk for aneurysm formation and rupture.

#### Acknowledgments

Supported in part by grants from the National Institute of Diabetes and Digestive and Kidney Diseases, National Institutes of Health (DK058816 and DK090728).

#### Disclosures

None.

#### References

- Pirson Y, Chauveau D, Torres VE: Management of cerebral aneurysms in autosomal dominant polycystic kidney disease: Unruptured asymptomatic intracranial aneurysms. *J Am Soc Nephrol* 13: 269–276, 2002
- Campeau NG, Huston J III, Bernstein MA, Lin C, Gibbs GF: Magnetic resonance angiography at 3.0 Tesla: Initial clinical experience. *Top Magn Reson Imaging* 12: 183–204, 2001
- Gibbs GF, Huston J 3rd, Bernstein MA, Riederer SJ, Brown RD Jr: Improved image quality of intracranial aneurysms: 3.0-T versus 1.5-T time-of-flight MR angiography. *AJNR Am J Neuroradiol* 25: 84–87, 2004
- Unruptured intracranial aneurysms—risk of rupture and risks of surgical intervention. International Study of Unruptured Intracranial Aneurysms Investigators. *N Engl J Med* 339: 1725–1733, 1998
- Wiebers DO, Whisnant JP, Huston J III, Meissner I, Brown RD Jr, Piepgras DG, Forbes GS, Thielen K, Nichols D, O'Fallon WM, Peacock J, Jaeger L, Kassell NF, Kongable Beckman GL, Torner JC: Unruptured intracranial aneurysms: Natural history, clinical outcome, and risks of surgical and endovascular treatment. *Lancet* 362: 103–110, 2003
- Rossetti S, Chauveau D, Kubly V, Slezak JM, Saggat-Malik AK, Pei Y, Ong AC, Stewart F, Watson ML, Bergstralh EJ, Winearls CG, Torres VE, Harris PC: Association of mutation position in polycystic kidney disease 1 (PKD1) gene and development of a vascular phenotype. *Lancet* 361: 2196–2201, 2003
- Gibbs GF, Huston J III, Qian Q, Kubly V, Harris PC, Brown RD Jr, Torres VE: Follow-up of intracranial aneurysms in autosomal-dominant polycystic kidney disease. *Kidney Int* 65: 1621–1627, 2004
- Huston J, Torres V, Wiebers D, Schievink W: Follow-up of intracranial aneurysms in autosomal dominant polycystic kidney disease by magnetic resonance angiography. *J Am Soc Nephrol* 7: 2135–2141, 1996
- Rossetti S, Consugar MB, Chapman AB, Torres VE, Guay-Woodford LM, Grantham JJ, Bennett WM, Meyers CM, Walker DL, Bae K, Zhang QJ, Thompson PA, Miller JP, Harris PC: Comprehensive molecular diagnostics in autosomal dominant polycystic kidney disease. *J Am Soc Nephrol* 18: 2143–2160, 2007
- Griffin MD, Torres VE, Grande JP, Kumar R: Vascular expression of polycystin. *J Am Soc Nephrol* 8: 616–626, 1997
- Qian Q, Li M, Cai Y, Ward CJ, Somlo S, Harris PC, Torres VE: Analysis of the polycystins in aortic vascular smooth muscle cells. *J Am Soc Nephrol* 14: 2280–2287, 2003
- Torres VE, Cai Y, Chen X, Wu GQ, Geng L, Cleghorn KA, Johnson CM, Somlo S: Vascular expression of polycystin 2. *J Am Soc Nephrol* 12: 1–9, 2001
- Ibraghimov-Beskrovnaia O, Dackowski WR, Foggensteiner L, Coleman N, Thiru S, Petry LR, Burn TC, Connors TD, Van Raay T, Bradley J, Qian F, Onuchic LF, Watnick TJ, Piontek K, Hakim RM, Landes GM, Germino GG, Sandford R, Klinger KW: Polycystin: *In vitro* synthesis, *in vivo* tissue expression, and subcellular localization identifies a large membrane-associated protein. *Proc Natl Acad Sci U S A* 94: 6397–6402, 1997
- Lantinga-van Leeuwen IS, Dauwerse JG, Baelde HJ, Leonhard WN, van de Wal A, Ward CJ, Verbeek S, Deruiter MC, Breuning MH, de Heer E, Peters DJ: Lowering of *Pkd1* expression is sufficient to cause polycystic kidney disease. *Hum Mol Genet* 13: 3069–3077, 2004
- Qian Q, Hunter LW, Li M, Marin-Padilla M, Prakash YS, Harris PC, Somlo S, Torres VE, Sieck GC: *Pkd2* haploinsufficiency alters intracellular calcium in vascular smooth muscle cells. *Hum Mol Genet* 12: 1875–1880, 2003
- Chapman AB, Rubinstein D, Hughes R, Stears JC, Earnest MP, Johnson AM, Gabow PA, Kaehny WD: Intracranial aneurysms in autosomal dominant polycystic kidney disease. *N Engl J Med* 327: 916–920, 1992
- Huston J III, Torres V, Sullivan P, Offord K, Wiebers D: Value of magnetic resonance angiography for the detection of intracranial aneurysms in autosomal dominant polycystic kidney disease. *J Am Soc Nephrol* 3: 1871–1877, 1993
- Ruggieri P, Poulos N, Masaryk T, Ross J, Obuchowski N, Awad I, Braun W, Nally J, Lewin J, Modic M: Occult intracranial aneurysms in polycystic kidney disease: Screening with MR angiography. *Radiology* 191: 33–39, 1994
- Rinkel GJ: Intracranial aneurysm screening: Indications and advice for practice. *Lancet Neurol* 4: 122–128, 2005
- Brown RD Jr, Huston J, Hornung R, Foroud T, Kallmes DF, Kleindorfer D, Meissner I, Woo D, Sauerbeck L, Broderick J: Screening for brain aneurysm in the Familial Intracranial Aneurysm study: Frequency and predictors of lesion detection. *J Neurosurg* 108: 1132–1138, 2008
- Burns JD, Huston J III, Layton KF, Piepgras DG, Brown RD Jr: Intracranial aneurysm enlargement on serial magnetic resonance angiography: Frequency and risk factors. *Stroke* 40: 406–411, 2009
- Matsubara S, Hadeishi H, Suzuki A, Yasui N, Nishimura H: Incidence and risk factors for the growth of unruptured cerebral aneurysms: Observation using serial computerized tomography angiography. *J Neurosurg* 101: 908–914, 2004
- Miyazawa N, Akiyama I, Yamagata Z: Risk factors for growth of unruptured intracranial aneurysms: Follow-up study by

- serial 0.5-T magnetic resonance angiography. *Neurosurgery* 58: 1047–1053, discussion 1047–1053, 2006
24. Wermer MJ, van der Schaaf IC, Velthuis BK, Majoie CB, Albrecht KW, Rinkel GJ: Yield of short-term follow-up CT/MR angiography for small aneurysms detected at screening. *Stroke* 37: 414–418, 2006
  25. Wiebers DO, Whisnant JP, Sundt TM Jr, O'Fallon WM: The significance of unruptured intracranial saccular aneurysms. *J Neurosurg* 66: 23–29, 1987
  26. Ishibashi T, Murayama Y, Urashima M, Saguchi T, Ebara M, Arakawa H, Irie K, Takao H, Abe T: Unruptured intracranial aneurysms: Incidence of rupture and risk factors. *Stroke* 40: 313–316, 2009
  27. Juvela S, Porras M, Poussa K: Natural history of unruptured intracranial aneurysms: Probability of and risk factors for aneurysm rupture. *J Neurosurg* 93: 379–387, 2000
  28. Yasui N, Suzuki A, Nishimura H, Suzuki K, Abe T: Long-term follow-up study of unruptured intracranial aneurysms. *Neurosurgery* 40: 1155–1159, discussion 1159–1160, 1997
  29. Rinkel GJ: Natural history, epidemiology and screening of unruptured intracranial aneurysms. *J Neuroradiol* 35: 99–103, 2008
  30. Bor AS, Rinkel GJ, Adami J, Koffijberg H, Ekblom A, Buskens E, Blomqvist P, Granath F: Risk of subarachnoid haemorrhage according to number of affected relatives: A population based case-control study. *Brain* 131: 2662–2665, 2008
  31. Broderick JP, Brown RD Jr, Sauerbeck L, Hornung R, Huston J III, Woo D, Anderson C, Rouleau G, Kleindorfer D, Flaherty ML, Meissner I, Foroud T, Moomaw EC, Connolly ES, Investigators FIAS: Greater rupture risk for familial as compared to sporadic unruptured intracranial aneurysms. *Stroke* 40: 1952–1957, 2009
  32. Higashida RT, Lahue BJ, Torbey MT, Hopkins LN, Leip E, Hanley DF: Treatment of unruptured intracranial aneurysms: A nationwide assessment of effectiveness. *AJNR Am J Neuroradiol* 28: 146–151, 2007
  33. Johnston SC, Wilson CB, Halbach VV, Higashida RT, Dowd CF, McDermott MW, Applebury CB, Farley TL, Gress DR: Endovascular and surgical treatment of unruptured cerebral aneurysms: Comparison of risks. *Ann Neurol* 48: 11–19, 2000
  34. King JT Jr, Berlin JA, Flamm ES: Morbidity and mortality from elective surgery for asymptomatic, unruptured, intracranial aneurysms: A meta-analysis. *J Neurosurg* 81: 837–842, 1994
  35. Lanterna LA, Tredici G, Dimitrov BD, Biroli F: Treatment of unruptured cerebral aneurysms by embolization with Guglielmi detachable coils: Case-fatality, morbidity, and effectiveness in preventing bleeding—A systematic review of the literature. *Neurosurgery* 55: 767–775, discussion 775–768, 2004
  36. Raaymakers TW, Rinkel GJ, Limburg M, Algra A: Mortality and morbidity of surgery for unruptured intracranial aneurysms: A meta-analysis. *Stroke* 29: 1531–1538, 1998
  37. Standhardt H, Boecher-Schwarz H, Gruber A, Benesch T, Knosp E, Bavinzski G: Endovascular treatment of unruptured intracranial aneurysms with Guglielmi detachable coils: Short- and long-term results of a single-centre series. *Stroke* 39: 899–904, 2008
  38. Thornton J, Bashir Q, Aletich VA, Debrun GM, Ausman JI, Charbel FT: What percentage of surgically clipped intracranial aneurysms have residual necks? *Neurosurgery* 46: 1294–1298, discussion 1298–1300, 2000
  39. David CA, Vishteh AG, Spetzler RF, Lemole M, Lawton MT, Partovi S: Late angiographic follow-up review of surgically treated aneurysms. *J Neurosurg* 91: 396–401, 1999
  40. Tsutsumi K, Ueki K, Morita A, Usui M, Kirino T: Risk of aneurysm recurrence in patients with clipped cerebral aneurysms: Results of long-term follow-up angiography. *Stroke* 32: 1191–1194, 2001
  41. Burns J, Brown RJ: Treatment of unruptured intracranial aneurysms: Surgery, coiling, or nothing? *Curr Neurol Neurosci Rep* 9: 6–12, 2009

**Received:** November 1, 2010 **Accepted:** January 21, 2011

Published online ahead of print. Publication date available at [www.cjasn.org](http://www.cjasn.org).

Access to UpToDate on-line is available for additional clinical information at [www.cjasn.org](http://www.cjasn.org).