

Rituximab Treatment of Adult Patients with Steroid-Resistant Focal Segmental Glomerulosclerosis

Gema Fernandez-Fresnedo,* Alfonso Segarra,[†] Ester González,[‡] Simona Alexandru,[§] Ramon Delgado,^{||} Natalia Ramos,[†] Jesús Egido,[§] Manuel Praga,[‡] for the Grupo de Trabajo de Enfermedades Glomerulares de la Sociedad Española de Nefrología (GLOSEN)

*Department of Nephrology, Hospital Marqués de Valdecilla, Santander, [†]Department of Nephrology, Hospital Vall d'Hebrón, Barcelona, and [‡]Department of Nephrology, Hospital 12 de Octubre, [§]Department of Nephrology, Fundación Jiménez Díaz, and ^{||}Department of Nephrology, Hospital Ruber, Madrid, Spain

Background and objectives: Isolated case reports have shown a beneficial effect of rituximab on pediatric patients with primary FSGS, but there is no information about rituximab treatment of FSGS in adults.

Design, setting, participants, & measurements: All patients who had biopsy-proven FSGS and were treated with rituximab in Spain were identified, independent of their positive or negative response, among the nephrology departments that belong to the Spanish Group for the Study of Glomerular Diseases (GLOSEN). Their characteristics and outcome after rituximab treatment were studied.

Results: Eight patients were identified. Rituximab failed to improve nephrotic syndrome in five of eight patients, who continued to show massive proteinuria and exhibited a rapidly deteriorating renal function in two cases. Among the remaining three patients, two of them showed an improvement of renal function and a remarkable proteinuria reduction and one experienced a beneficial but transitory effect after rituximab. There were no differences in clinical or laboratory characteristics or in the CD20 B lymphocyte count after rituximab between these three patients and the five who had a negative response. The only difference was in the regimen of rituximab administration: Whereas the five patients with a negative response received only four weekly consecutive infusions of 375 mg/m², the three remaining patients received additional doses of rituximab.

Conclusions: Only a minority (three of eight) of patients in our series of adult patients with FSGS showed a positive influence of rituximab. More studies are necessary to characterize further the optimal dosages and the mechanisms of action of rituximab in FSGS.

Clin J Am Soc Nephrol 4: 1317–1323, 2009. doi: 10.2215/CJN.00570109

The treatment of idiopathic steroid-resistant FSGS remains a worrying challenge for nephrologists. Cyclosporine has demonstrated a beneficial effect in some prospective, randomized studies, inducing partial or complete remission in a majority of treated patients (1); however, relapses are common after cyclosporine withdrawal, and the risk for chronic nephrotoxicity when the drug is maintained for long periods remains an important concern. Some observational studies have suggested a beneficial effect of tacrolimus, mycophenolate, sirolimus, ACTH, or plasmapheresis on some patients, but prospective, controlled studies are lacking.

Rituximab is a mAb directed against the cell surface antigen CD20 of B lymphocytes. It is an effective therapy for non-Hodgkin's lymphoma and other B cell malignancies (2). Several reports of successful use of rituximab in systemic diseases and immune-mediated renal disorders have been published, in-

cluding membranous glomerulonephritis, lupus nephritis, vasculitis, mixed cryoglobulinemia, and thrombotic thrombocytopenic purpura (3,4).

Some case reports have suggested that rituximab could be effective to resolve recurrent nephrotic syndrome after renal transplantation in patients whose primary renal disease was FSGS (5–9). The potential usefulness of rituximab has also been explored in patients with steroid-dependent or steroid-resistant forms of nephrotic syndrome. Several case reports and observational studies strongly suggest that rituximab could be an effective treatment for steroid-dependent nephrotic syndrome because the great majority of treated patients (most of them children) have experienced long-lasting periods of remission without steroids or other immunosuppressive drugs (10–12). Nevertheless, no prospective, randomized trials have been performed to compare the efficacy of this treatment with other available therapies for steroid-dependent nephrotic syndrome. Regarding steroid-resistant nephrotic syndrome, a few case reports of children with biopsy-proven FSGS and one adult with minimal-change disease in whom rituximab induced a complete or partial remission of nephrotic syndrome have been reported (13–16). As far as we know, no studies about rituximab treatment of adult patients with steroid-resistant ne-

Received January 26, 2009. Accepted June 3, 2009.

Published online ahead of print. Publication date available at www.cjasn.org.

Correspondence: Dr. Manuel Praga, Servicio de Nefrología, Hospital 12 de Octubre, Avda de Córdoba s/n Madrid 28041, Spain. Phone: 34-91-3908383; Fax: 34-91-4692422; E-mail: mpragat@senefro.org

phrotic syndrome as a result of FSGS in their native kidneys have been published. Moreover, in the absence of prospective, controlled trials, anecdotal case reports tend to publish preferably patients with a positive response to innovative treatments. For all of these reasons, we collected the experience with rituximab-treated patients with FSGS among the nephrology departments that belong to the Spanish Group for the study of Glomerular Diseases (GLOSEN).

Materials and Methods

Patients included in the study met the following criteria: (1) Biopsy-proven FSGS; (2) nephrotic syndrome resistant to corticosteroids and several other immunosuppressive treatments, including cyclosporine, tacrolimus, mycophenolate, cyclophosphamide, and chlorambucil; (3) absence of concomitant infections, comorbid conditions, or systemic diseases that could have a pathogenic relationship with the nephrotic syndrome; and (4) documented rituximab treatment and regular follow-up after rituximab infusions. Steroid resistance was defined by the persistence of nephrotic syndrome despite prednisone therapy (1 mg/kg per d) for >4 mo. This study was an initiative of GLOSEN, and all of the nephrology departments that belonging to this group were asked to identify patients who had biopsy-proven idiopathic FSGS and had been treated with rituximab. For each patient, the following data were extracted from patient records: Demographic characteristics, clinical data (BP, body weight, edema), time elapsed since the diagnosis of FSGS by renal biopsy, and previous immunosuppressive treatments. Immunosuppressive and general treatment at the time of rituximab administration and thereafter were also carefully recorded. A careful analysis of familial history of renal diseases, including nephrotic syndrome, was performed in every case. Renal biopsies were reviewed at every participating center for this study. The pathologic variant of FSGS (collapsing, tip lesion, cellular variant, perihilar, and FSGS not otherwise specified) was recorded, as well as the percentage of glomeruli showing a global sclerosis. The severity of tubulointerstitial fibrosis was graded as absent (0), mild (+), moderate (++), and severe (+++).

For all patients, the following clinical and laboratory parameters were recorded at baseline (onset of rituximab administration), weekly during the treatment period, and then every 3 to 6 mo after treatment: BP, body weight, complete blood counts, electrolytes, and routine serum biochemistry profile (including total proteins, albumin, a lipid panel, and serum creatinine). Creatinine clearance and proteinuria were measured by 24-h urine collections at each time point. For all patients, B cell flow cytometry was performed after every rituximab treatment. For statistical analysis, the data were summarized using proportions or means (\pm SD) as appropriate. Comparisons were performed by paired *t* test.

Results

Eight patients who had biopsy-proven primary FSGS and had received rituximab because of persistent nephrotic syndrome that was resistant to other therapies were identified. The main demographic and clinical characteristics of the patients are summarized in Table 1. Patients were one woman and seven men, with a mean age of 31 ± 14 yr (range 19 to 55 yr) and a mean disease duration of 50 ± 35 mo (range 24 to 107 mo). Several immunosuppressive regimens had been attempted without success in all of the patients (Table 1), including steroids, cyclosporine, tacrolimus, mycophenolate, and cyclophosphamide. All patients had severely nephrosis at the time of rituximab treatment (mean proteinuria 14.0 ± 4.4 g/24

h; range 9.4 to 23.0 g/24 h), and their mean serum creatinine was 1.4 ± 0.5 mg/dl (range 0.9 to 2.3 mg/dl). All of the patients were receiving immunosuppressive agents at the time of rituximab administration (Table 2), and this immunosuppressive treatment was maintained after rituximab administration. Supportive treatment of nephrotic syndrome (diuretics, statins, angiotensin-converting enzyme inhibitors, or angiotensin receptor blockers) that each patient was receiving at the time of rituximab administration was also maintained during follow-up.

Renal biopsies showed lesions of the not otherwise specified variant of FSGS (six cases), cellular variant (1), and tip lesion (1). The percentage of globally sclerosed glomeruli ranged from 0 to 30%. Interstitial fibrosis was absent in three cases, mild in four, and moderate in one (Table 1). No correlation between histologic features and response to rituximab treatment was found.

Most patients (patients 1 through 5) received four weekly consecutive intravenous infusions of 375 mg/m² rituximab. Patients 6 and 7 received four weekly consecutive infusions (375 mg/m²) at baseline followed by four more infusions at 12 mo (patient 6) and two more infusions at 6 mo (patient 7). In both cases, the decision for these additional rituximab doses was taken on the basis of a proteinuria increase (Figure 1). Patient 8 received eight weekly consecutive infusions of 375 mg/m² at baseline, following the protocol of rituximab infusions used by hematologists of the center in which this patient was treated. The tolerance to rituximab infusion was good, and no adverse effects were observed during the period of rituximab administration or during the follow-up. The mean duration of follow-up after rituximab therapy was 16.4 ± 5.1 mo (range 12 to 24 mo).

As shown in Table 2 and Figure 1, rituximab failed to resolve nephrotic syndrome in most of the patients. Patients 1 to 3 persisted with a massive proteinuria and a roughly stable serum creatinine. Patients 4 and 5 showed a clear worsening of renal function accompanied by a persistent massive proteinuria. Patient 6, who had clearly impaired renal function at baseline (serum creatinine 2.3 mg/dl), showed a transitory proteinuria decrease >50% of baseline values after the first rituximab course, but it increased thereafter. He received a second rituximab course at 12 mo, showing again a clear but transitory proteinuria decrease (Table 2, Figure 1). Although clinical improvement and a complete edema resolution were observed after rituximab treatment, serum creatinine had increased to 3.2 mg/dl and proteinuria to 9 g/24 h at last visit (22 mo after the first rituximab treatment).

Only two patients (patients 7 and 8) experienced a clear and sustained improvement after rituximab treatment. Patient 7, who showed severe proteinuria and deteriorated renal function at the onset of rituximab (12.9 g/24 h and 1.77 mg/dl, respectively) showed a clear proteinuria decrease to non-nephrotic values (3.2 g/24 h) accompanied by a slight improvement of renal function. Patient 8, who showed an impressive urinary protein loss above 20 g/24 h and clearly deteriorated renal function (serum creatinine 1.9 mg/dl) at the onset of rituximab therapy, experienced an improvement of renal function accom-

Table 1. Main clinical and laboratory data at baseline of individual patients^a

Patient	Age (yr)	Gender	Disease Duration (mo)	Renal Biopsy ^b	Previous Therapies ^c	Laboratory Characteristics at Baseline			
						Serum Creatinine (mg/dl)	Urinary Protein Excretion (g/24 h)	Serum Albumin (g/dl)	Serum Cholesterol (mg/dl)
1	19	M	24	NOS GGS 10% 0	ST 1 mg/kg per d (6) TAC 0.08 mg/kg per d (9) MMF 1.5 g/d (3)	1.2	16.0	1.8	520
2	29	M	36	Tip GGS 9% +	ST 1 mg/kg per d (6) Cycl 1.5 mg/kg per d (3) CsA 5 mg/kg per d (6) MMF 1 g/d (6)	0.9	16.5	1.4	690
3	34	M	36	NOS GGS 0% 0	ST 0.4 mg/kg per d (24) CsA 3.5 mg/kg per d (18) TAC 0.05 mg/kg per d (8) MMF 1 g/d (6)	1.4	9.4	2.2	262
4	19	M	25	NOS GGS 0% 0	ST 1 mg/kg per d (6) CsA 5 mg/kg per d (6) MMF 2 g/d (6)	0.9	12.0	1.8	550
5	55	M	24	NOS GGS 16% +	ST 1 mg/kg per d (6) CSA 5 mg/kg per d (12)	0.9	9.8	1.7	430
6	51	M	107	CELL GGS 15% +	ST 0.7 mg/kg per d (8) CsA 2.5 mg/kg per d (16) MMF 1 g/d (12)	2.3	12.7	1.8	–
7	20	M	30	NOS GGS 0% +	ST 0.4 mg/kg per d (12) CsA 3.5 mg/kg per d (1) TAC 0.05 mg/kg per d (30)	1.7	12.9	2.0	221
8	23	F	95	NOS GGS 30% ++	ST 0.3 mg/kg per d (30) Cycl 1 mg/kg per d (3) CsA 4 mg/kg per d (12) MMF 2 g/d (24)	1.9	23.0	1.3	263

^aCsA, cyclosporine; Cycl, cyclophosphamide; MMF, mycophenolate mofetil; ST, steroids; TAC, tacrolimus.

^bThe pathologic variant of FSGS is expressed (NOS, not otherwise specified; Tip, tip lesion; CELL, cellular variant), as well as the percentage of glomeruli showing global sclerosis (GGS) and the severity of interstitial fibrosis (0, absent; +, mild; ++, moderate; +++, severe).

^cMean dosages and duration in months (in parentheses) expressed after every drug.

panied by a remarkable proteinuria decrease. Fifteen months after rituximab therapy, serum creatinine was within normal values (1 mg/dl), and proteinuria, although still in nephrotic values (3.9 g/24 h) has shown a clear decrease, accompanied by an increase of serum albumin values.

In the whole group of patients, proteinuria had decreased from 14.0 ± 4.4 g/24 h at baseline to 10.5 ± 4.9 g/24 h at the end of follow-up, but serum creatinine had increased from 1.4 ± 0.5 to 2.2 ± 1.8 mg/dl (NS). CD20⁺ B lymphocytes decreased to undetectable numbers after the first course of rituximab in all of the patients. Time to recover a normal CD20⁺ count after rituximab treatment ranged between 6 and 12 mo (9.7 ± 2.1 mo). No differences were observed in CD20⁺ B lymphocyte count among patients with a positive response to rituximab treatment (patients 6 to 8) and the five remaining patients who showed no response.

Discussion

Several case reports and observational studies have created a considerable expectation about the therapeutic possibilities of rituximab in nephrotic syndrome (3,4). Uncontrolled studies have shown significant proteinuria decrease after rituximab treatment in patients with idiopathic membranous nephropathy (17,18). Conversely, several case reports and uncontrolled series suggested that rituximab could be a potentially effective and safe alternative for pediatric patients (and perhaps for adult patients) with steroid-dependent nephrotic syndrome (10–12).

Although genetic mutations involving components of the glomerular filtration barrier may account for a significant proportion of children with steroid-resistant forms of FSGS, the pathogenesis of the disease in most adult patients is thought to involve a yet-unidentified circulating permeability factor that

Table 2. Time course of SCr and proteinuria after rituximab treatment^a

Patient	Baseline		Month 1		Month 6		Month 12		Last Visit		Follow-up (mo)	IS Treatment ^b	
	BP (mm/Hg)	SCr (mg/dl)	Prot (g/24 h)	SCr (mg/dl)	Prot (g/24 h)	SCr (mg/dl)	Prot (g/24 h)	SCr (mg/dl)	Prot (g/24 h)	SCr (mg/dl)			Prot (g/24 h)
1	110/76	1.2	16	1.9	14.0	1.8	16.0	1.40	15.0	1.4	15.0	12	TAC (4) MMF (4)
2	92/64	0.9	16.5	0.8	21.0	0.9	14.2	0.8	15.8	1.1	15.8	12	CSA (3) MMF (3)
3	140/78	1.4	9.4	1.4	11.3	1.3	11.3	1.1	9.8	1.2	9.8	14	TAC (6)
4	110/62	0.9	12.0	1.1	14.0	1.8	12.0	2.6	10.6	6.5	14.0	18	CSA (3) MMF (3)
5	122/85	0.9	9.8	0.8	10.5	1.1	12.2	1.4	11.6	1.9	13.3	24	CSA (5)
6	114/64	2.3	12.7	2.5	5.7	2.5	10.0	2.7	13.0	3.2	9.0	24	ST (12) MMF (2)
7	124/72	1.7	12.9	1.6	6.3	1.5	8.1	1.4	3.2	1.4	3.2	12	ST (10) TAC (8)
8	110/60	1.9	23.0	1.6	7.8	1.1	7.5	1.0	3.9	1.0	3.9	15	MMF (8) CSA (4) MMF (12)

^aIS, immunosuppressive; Prot, proteinuria; SCr, serum creatinine.^bDuration (in months) of IS treatment after rituximab appears in parentheses after every IS drug.

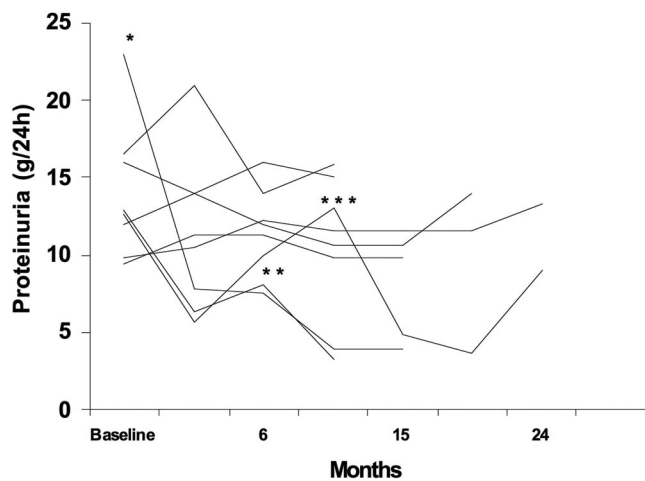


Figure 1. Evolution of proteinuria after rituximab therapy. *Patient 8 received eight weekly consecutive infusions (375 mg/m^2) of rituximab at baseline; **patient 7 received two more rituximab infusions (375 mg/m^2) at 6 mo; ***patient 6 received four more rituximab infusions (375 mg/m^2) at 12 mo.

damages podocytes and disrupts glomerular permeability (19). The participation of such a toxin is supported by the rapid recurrence of nephrotic syndrome in approximately 30% of patients who had primary FSGS and received a first renal transplant and in >80% of patients who received a second transplant after a previous recurrence (20).

The beneficial effect of plasmapheresis and immunoabsorption, reported in some cases of primary FSGS and in some recurrent FSGS, would also agree with the existence of a circulating permeability factor (21); however, a considerable proportion of patients who have primary FSGS and for whom steroids fail to resolve nephrotic syndrome are also resistant to these measures and to several other immunosuppressive therapies (cyclosporine, tacrolimus, mycophenolate, sirolimus, ACTH). The prognosis of patients who are resistant to multiple therapies is very poor, most of them showing rapid progression to end-stage renal failure.

The possibility of a beneficial effect of rituximab on primary FSGS was initially suggested for the publication of patients who had recurrent FSGS in renal grafts and had remission of nephrotic syndrome after treatment with rituximab. To date, six patients (four adults, two children) with such a successful response to rituximab have been reported (5–9). Nevertheless, some of these patients were treated with rituximab because of the development of lymphoproliferative disorders (5,6), introducing the doubt of a possible pathogenic relationship between such hematologic disorder and the pathogenesis of proteinuria. Conversely, two other recent reports, also of six patients (four adults, two children) communicated a failure of rituximab to improve nephrotic syndrome in renal transplant patients with recurrent FSGS (22,23).

To date, only six reports have included 10 patients who had primary FSGS in their native kidneys and were treated with rituximab (10–15). All of them had a positive response, achieving complete or partial remission of nephrotic syndrome, al-

though, in some cases, rituximab was administered when proteinuria was in non-nephrotic values. Of note, all of these patients were children or adolescents. Our series of eight patients, the largest so far collected, shows on the contrary poor efficacy of rituximab in adult patients with severe nephrotic syndrome as a result of primary FSGS and resistance to steroids and several other immunosuppressants. Five of eight patients continued to show massive nephrotic proteinuria, and renal function exhibited a rapid deterioration on follow-up in two of them; however, two other patients, who had a very poor renal prognosis (massive proteinuria accompanied by increasing serum creatinine), showed a partial but very important improvement of renal function accompanied by a remarkable reduction in proteinuria. The remaining patient, who received two rituximab courses, showed a clear proteinuria reduction after every rituximab treatment, but this beneficial effect was only transitory.

The reasons that rituximab seems to be effective in some patients with primary FSGS whereas it fails to induce any improvement in others (such as occurred in five of eight of our cases) remain unknown. All of the previously reported patients on whom rituximab had a positive influence were in the pediatric age, whereas all of our patients were adult >19 yr. A possible influence of age, therefore, could be postulated and investigated in future clinical studies. Conversely, the duration and severity of nephrotic syndrome could have an unrecognized influence on the effectiveness of rituximab. Fervenza *et al.* (18) performed a very rigorous and original analysis of rituximab treatment in patients with idiopathic membranous nephropathy. Complete or partial remission occurred in eight of 14 treated patients, but the remaining patients continued to show nephrotic proteinuria. They found that serum rituximab levels were lower and the recovery of CD19^+ B cells faster in these patients with nephrosis than in a group of patients who did not have proteinuria and had rheumatoid arthritis and were treated with the same rituximab regimen. The authors suggested that massive proteinuria may lead to losses of rituximab in the urine, reducing its therapeutic effectiveness. In this way, all of our patients had a very severe nephrotic syndrome (massive proteinuria with hypoalbuminemia) of considerable duration ($50 \pm 35 \text{ mo}$; range 24 to 107 mo) and persistent resistance to many types of immunosuppressive approaches.

The total dosage and the regimen of rituximab administration could also play a role in the variability of response that patients with nephrotic syndrome show to this drug. Zaja *et al.* (24) showed that whereas total depletion of CD19^+ B cells was observed in the circulation, depletion of CD20^+ B cells in the bone marrow occurred in only two of seven patients who had hematologic diseases and had been treated with rituximab (four weekly doses of 375 mg/m^2). These data suggest that bone marrow B cells are more resistant to depletion than circulating CD19^+ cells, although the significance of these data for patients with nephrotic syndrome is unknown. It is interesting that the only three patients in our series who had a positive response to rituximab had received more rituximab doses than the other five patients (patients 1 to 5; Tables 1 and 2), in whom four weekly consecutive intravenous infusions of 375 mg/m^2 of

rituximab had been administered. Patients 6 (who showed a transitory but clinically appreciable nephrotic syndrome improvement) and 7 (partial remission of nephrotic syndrome) had received additional rituximab infusions at 12 and 6 mo, respectively, and patient 8 (who experienced a remarkable proteinuria decrease accompanied by a recovery of normal renal function) had received eight weekly consecutive infusions of 375 mg/m² at baseline.

Another interesting finding in our study was that the immediate effect of rituximab infusions on B cells was similar in all patients, irrespective of their nephrotic syndrome response. Circulating CD20 (+) lymphocyte counts were undetectable in all of them after rituximab administration. Some clinical and experimental studies suggested that the circulating permeability factor that is involved in the pathogenesis of FSGS is produced by T cells (25). In this way, the deletion of B cells induced by rituximab apparently would be disconnected with this T cell–driven pathogenic hypothesis; however, some studies have shown that B cell depletion by rituximab increases the number of T regulatory cells throughout a downregulation of the T cell co-stimulatory molecule CD40 ligand (26). Conversely, rituximab could induce a proteinuria decrease through mechanisms independent of B cell depletion. Thus, recent studies have uncovered unexpected similarities between lymphocytes and podocytes (27), and some proteins shared by lymphocytes and podocytes are upregulated in patients with nephrotic syndrome (28).

Conclusions

Our results do not support a generalized effectiveness of rituximab treatment in FSGS. In our series of eight adult patients who had severe nephrotic syndrome that was unresponsive to several other immunosuppressive therapies, only two patients showed a sustained positive response, with renal function improvement and a remarkable reduction of proteinuria, whereas another patient showed a beneficial but transitory effect of rituximab. More studies are necessary to characterize further the type of patients who have FSGS and could benefit from rituximab administration, as well as the optimal dosages and the mechanisms of action of rituximab in this disease.

Disclosures

None.

References

- Catran DC, Appel GB, Hebert LA, Hunsicker LG, Pohl MA, Hoy WE, Maxwell DR, Kunis CL: A randomized trial of cyclosporine in patients with steroid-resistant focal segmental glomerulosclerosis. North America Nephrotic Syndrome Study Group. *Kidney Int* 56: 2220–2226, 1999
- Maloney DG, Grillo-Lopez AJ, White CA, Bodkin D, Schilder RJ, Neidhart JA, Janakiraman N, Foon KA, Liles TM, Dallaire BK, Wey K, Royston I, Davis T, Levy R: IDEC-C2B8 (Rituximab) anti-CD20 monoclonal antibody therapy in patients with relapsed low-grade non-Hodgkin's lymphoma. *Blood* 90: 2188–2195, 1997
- Salama AD, Pusey CD: Drug insight: Rituximab in renal disease and transplantation. *Nat Clin Pract Nephrol* 2: 221–230, 2006
- Jayne D: Role of rituximab therapy in glomerulonephritis. *J Am Soc Nephrol* September 17, 2008 [epub ahead of print]
- Nozu K, Iijima K, Fujisawa M, Nakagawa A, Yoshikawa N, Matsuo M: Rituximab treatment for posttransplant lymphoproliferative disorder (PTLD) induces complete remission of recurrent nephrotic syndrome. *Pediatr Nephrol* 20: 1660–1663, 2005
- Pescovitz MD, Book BK, Sidner RA: Resolution of recurrent focal segmental glomerulosclerosis proteinuria after rituximab treatment. *N Engl J Med* 354: 1961–1963, 2006
- Kamar N, Faguer S, Esposito L, Guitard J, Nogier MB, Durand D, Rostaing L: Treatment of focal segmental glomerular sclerosis with rituximab: 2 case reports. *Clin Nephrol* 67: 250–254, 2007
- Hristea D, Hadaya K, Marangon N, Buhler L, Villard J, Morel P, Martin PY: Successful treatment of recurrent focal segmental glomerulosclerosis after kidney transplantation by plasmapheresis and rituximab. *Transpl Int* 20: 102–105, 2007
- Gossmann J, Scheuermann E-H, Porubsky S, Kachel H-G, Geiger H, Hauser I: Abrogation of nephrotic proteinuria by rituximab treatment in a renal transplant patient with relapsed focal segmental glomerulosclerosis. *Transpl Int* 20: 558–562, 2007
- Benz K, Dötsch J, Rascher W, Stachel D: Change of the course of steroid-dependent nephrotic syndrome after rituximab therapy. *Pediatr Nephrol* 19: 794–797, 2004
- Gilbert RD, Hulse E, Rigden S: Rituximab therapy for steroid-dependent minimal change nephrotic syndrome. *Pediatr Nephrol* 21: 1698–1700, 2006
- Guignon V, Dallochio A, Baudouin V, Dehennault M, Hachon-Le Camus C, Afanetti M, Groothoff J, Llanas B, Niaudet P, Nivet H, Raynaud N, Taque S, Ronco P, Bouissou F: Rituximab treatment for severe steroid- or cyclosporine-dependent nephrotic syndrome: A multicentric series of 22 cases. *Pediatr Nephrol* 23: 1269–1279, 2008
- Bagga A, Sihna A, Moudgil A: Rituximab in patients with the steroid-resistant nephrotic syndrome. *N Engl J Med* 356: 2751–2752, 2007
- Nakayama M, Kamei K, Nozu K, Matsuoka K, Nakagawa A, Sako M, Iijima K: Rituximab for refractory focal segmental glomerulosclerosis. *Pediatr Nephrol* 23: 481–485, 2008
- Suri M, Tran K, Sharma AP, Filler G, Grimmer J: Remission of steroid-resistant nephrotic syndrome due to focal and segmental glomerulosclerosis using rituximab. *Int Urol Nephrol* 40: 807–810, 2008
- Yang T, Nast CC, Vo A, Jordan SC: Rapid remission of steroid and mycophenolate mofetil (MMF)-resistant minimal change nephrotic syndrome after rituximab therapy. *Nephrol Dial Transplant* 23: 377–380, 2008
- Ruggenti P, Chiurciu C, Brusegan V, Abbate M, Perna A, Filippi C, Remuzzi G: Rituximab in idiopathic membranous nephropathy: A one-year prospective study. *J Am Soc Nephrol* 14: 1851–1857, 2003
- Fervenza FC, Cosio FG, Erickson SB, Specks U, Herzenberg AM, Dillon JJ, Leung N, Cohen IM, Wochos DN, Bergstralh E, Hladunewich M, Catran DC: Rituximab treatment of idiopathic membranous nephropathy. *Kidney Int* 73: 117–125, 2008

19. Savin VJ, Sharma R, Sharma M, McCarthy ET, Swan SK, Ellis E, Lovell H, Warady B, Gunwar S, Chonko AM, Artero M, Vincenti F: Circulating factor associated with increased glomerular permeability to albumin in recurrent focal segmental glomerulosclerosis. *N Engl J Med* 334: 878–883, 1996
20. Vincenti F, Ghiggeri G: New insights into the pathogenesis and the therapy of recurrent focal glomerulosclerosis. *Am J Transplant* 5: 1179–1185, 2005
21. Dantal J, Bigot E, Bogers W, Testa A, Kriaa F, Jacques Y, Hurault de Ligny B, Niaudet P, Charpentier B, Souillou JP: Effect of plasma protein adsorption on protein excretion in kidney-transplant recipients with recurrent nephrotic syndrome. *N Engl J Med* 330: 7–14, 1994
22. Yabu JM, Ho B, Scandling JD, Vincenti F: Rituximab failed to improve nephrotic syndrome in renal transplant patients with recurrent focal segmental glomerulosclerosis. *Am J Transplant* 8: 222–227, 2008
23. Marks SD, McGraw M: Does rituximab treat recurrent focal segmental glomerulosclerosis post-renal transplantation? *Pediatr Nephrol* 22: 158–160, 2007
24. Zaja F, Iacona I, Masolini P, Russo D, Sperotto A, Prodocimo S, Patriarca F, de Vita S, Regazzi M, Baccarani M, Fanin R: B-cell depletion with rituximab as treatment for immune hemolytic anemia and chronic thrombocytopenia. *Haematologica* 87: 189–195, 2002
25. Koyama A, Fujisaki M, Kobayashi M, Igarashi M, Narita M: A glomerular permeability factor produced by human T cell hybridomas. *Kidney Int* 40: 453–460, 1991
26. Sfikakis PP, Boletis JN, Lionaki S: Remission of proliferative lupus nephritis following B cell depletion therapy is preceded by down-regulation of the T cell costimulatory molecule CD40 ligand: An open-label trial. *Arthritis Rheum* 52: 501–513, 2005
27. Mathieson PW: Proteinuria and immunity: An overstated relationship? *N Engl J Med* 359: 2492–2494, 2008
28. Grimbert P, Valanciute A, Audard V, Pawlak A, Le gouvelo S, Lang P, Niaudet P, Bensman A, Guellaën G, Sahali D: Truncation of C-mip (Tc-mip), a new proximal signaling protein, induces c-maf Th2 transcription factor and cytoskeleton reorganization. *J Exp Med* 198: 797–807, 2003

Access to UpToDate on-line is available for additional clinical information
at <http://www.cjasn.org/>