

Cyst Infections in Patients with Autosomal Dominant Polycystic Kidney Disease

Marion Sallée,* Cédric Rafat,* Jean-Ralph Zahar,[†] Benoît Paulmier,[‡] Jean-Pierre Grünfeld,* Bertrand Knebelmann,* and Fadi Fakhouri*

*Department of Nephrology and [†]Department of Microbiology, Hôpital Necker, [‡]Department of Nuclear Medicine, Hôpital Européen Georges Pompidou, Université Paris Descartes, Assistance Publique-Hôpitaux de Paris, Paris, France

Background and objectives: Cyst infection is a complex diagnostic and therapeutic issue in patients with autosomal dominant polycystic kidney disease (ADPKD); however, published data regarding the diagnosis and the management of cyst infections in patients with ADPKD are sparse.

Design, setting, participants, & measurements: A retrospective study was conducted in a referral center for patients with ADPKD in Paris, France. We identified using a computerized database all patients who had ADPKD and were admitted in the nephrology department of Hôpital Necker between January 1998 and August 2008 with likely or definite renal and/or hepatic cyst infection. Medical files of all included patients were reviewed.

Results: Among 389 identified patients with ADPKD, 33 (8.4%) had 41 episodes of cyst infection, including eight definite and 33 likely cases. The incidence of cyst infections in patients with ADPKD was 0.01 episode per patient per year. Microbiological documentation was available for 31 episodes (75%), *Escherichia coli* accounting for 74% of all retrieved bacterial strains. Positron emission tomography scan proved superior to ultrasound, Computed tomography scan, and magnetic resonance imaging for the detection of infected cysts. Clinical efficacy of initial antibiotic treatment was noted in 71% of episodes. Antibiotic treatment modification was more frequently required for patients who were receiving initial monotherapy compared with those who were receiving bitherapy. Large (diameter >5 cm) infected cysts frequently required drainage.

Conclusions: Positron emission tomography scan will probably make the diagnosis of cyst infections easier and more accurate. Antibiotic association, including a fluoroquinolone, and the drainage of large infected cysts remain the main treatment for cyst infections.

Clin J Am Soc Nephrol 4: 1183-1189, 2009. doi: 10.2215/CJN.01870309

Autosomal dominant polycystic kidney disease (ADPKD) represents the most common inherited disorder affecting one in 500 to one in 1000 live births and accounting for 4 to 10% of dialysis patients. The most striking feature of ADPKD is the occurrence of numerous renal and hepatic cysts, which arise from various renal tubule segments and lead to an increased kidney size. Cysts are also associated with some of the most common complications of ADPKD: Intracystic bleeding, gross hematuria, obstruction mainly caused by liver cysts, and, most important, infections. Kidney and liver cyst infection is a complex diagnostic and therapeutic challenge; however, the literature on the diagnosis and the management of urinary tract infections and particularly cyst infections in patients with ADPKD is relatively sparse. The clinical, microbiological, and radiologic features of cyst infections as well as treatment regimens remain ill-defined (1–3). We conducted a retrospective, single-center study to assess the

clinical and radiologic presentation and treatment outcomes of cyst infections in patients with ADPKD.

Materials and Methods

We identified using a computerized database all patients who had ADPKD and were admitted to the nephrology department of Hôpital Necker (Paris, France) between January 1998 and August 2008 with renal and/or hepatic cyst infection. Medical files of all included patients were reviewed, and relevant clinical, biologic, and radiologic data were collected.

Diagnostic criteria for ADPKD were the presence of polycystic kidney and a typical familial history or, in the absence of familial history, the presence of three or more (unilateral or bilateral) renal cysts for individuals aged between 15 to 39 yr, two or more cysts in each kidney for individuals aged 40 to 59 yr, and four or more cysts in each kidney for individuals aged >60 yr according to Pei *et al.* (4).

The diagnosis of cyst infections and radiologic evaluation were based on the following criteria commonly used in clinical practice:

- Cyst infection was considered as definite in the presence of a cyst aspiration showing evidence of infection (neutrophils debris and/or microorganism).
- Cyst infection was considered as likely in the presence of all of the following features: Fever (temperature >38.5°C for >3 d), abdominal pain (particularly a palpable area of renal or liver tenderness), increased C-reactive protein (CRP; >50 mg/L), and the absence of any

Received March 17, 2009. Accepted April 16, 2009.

Published online ahead of print. Publication date available at www.cjasn.org.

Correspondence: Dr. Fadi Fakhouri, Molecular Genetics and Rheumatology Section, Faculty of Medicine, Imperial College, Hammersmith Campus, London, UK. Phone: 00442083832315; Fax: 00442083832379; E-mail: f.fakhouri@imperial.ac.uk

significant recent intracystic bleeding (based on the results of an abdominal computed tomography [CT] scan) or other causes of fever.

- Kidney and liver ultrasound data were considered positive when debris with a thick wall and/or a distal acoustic enhancement were detected in at least one cyst.
- Kidney and liver CT scan and magnetic resonance imaging (MRI) data were considered positive when enhanced wall thickening and/or perilesional inflammation was detected in at least one cyst.
- Efficacy of antibiotic treatment and infection eradication were defined by the disappearance of fever, normalization of CRP levels, and at least two negative blood and/or urine cultures.

Results

We identified 389 patients who had ADPKD and were admitted to the nephrology department of Hôpital Necker between January 1998 and August 2008. Among these patients, 33 (8.4%) had 41 episodes of cyst infection, including eight definite and 33 likely cases. Twenty-nine patients had 31 episodes of renal cyst infections (six definite and 25 likely), and four patients had six episodes of hepatic cyst infections (two definite and four likely). The incidence of cyst infections in patients with ADPKD was 0.01 episode per patient per year, and cyst infections accounted for 11% of all causes of hospital admission of patients with ADPKD.

Clinical Presentation

Clinical and biologic characteristics at the time of cyst infection are summarized in Table 1. All patients except one presented with fever and abdominal pain.

Microbiological Data

Microbiological documentation was available for 31 (75%) episodes (Table 2): Positive urine culture in 16 (39%) episodes, positive blood culture in 10 (24%) episodes, and positive cyst fluid culture in five (12%) episodes. *Escherichia coli* accounted for 23 (74%) of 31 retrieved bacterial strains. Twenty-seven percent of *E. coli* strains (four of 11) were resistant to β -lactamine, and 50% of *Staphylococcus aureus* (one of two) and *Enterococcus* species (one of two) strains were resistant to methicillin and amoxicillin, respectively.

Radiologic Findings

Radiologic findings are summarized in Table 3. For all patients, at least one radiologic examination was performed: Ultrasound in 18 episodes, CT scan in 28, MRI in four, and positron emission tomography (PET) scan in eight. Ultrasound, CT scan, MRI, and PET scan yielded positive results in 6, 18, 40, and 100%, respectively.

Antibiotic Treatment

For all patients, antibiotic treatment was introduced at the time of cyst infection diagnosis for a mean duration of 5 wk (range 2 to 12 wk; Table 4). Duration of antibiotic treatment was empirically chosen by the clinicians who were in charge of the patients. Clinical efficacy of initial antibiotic treatment was noted in 29 (71%) of 41 cyst infection episodes.

During 24 episodes of cyst infections, initial treatment con-

Table 1. Characteristics of 36 patients who had ADPKD and experienced 41 episodes of renal and hepatic cyst infections^a

Infection (Patients/ Episodes)	Male Gender (%)	Age (yr; Median)	GER (ml/min per 1.73 m ² ; Median)	Patients on Dialysis (n [%])	Peripheral Blood Leukocyte Count (/mm ³ ; Median)	CRP (mg/L; Median)	Positive Urine Culture (n [%])	Positive Blood Culture (n [%])
Definite renal cyst infection (6/6)	67	53	33	2 (33)	17,400	205	2(33%)	1 (17)
Likely renal cyst infection (24/25)	46	44	60	4 (17)	10,700	168	14(56%)	2 (8)
Definite liver cyst infection (2/2)	50	67	HD	2 (100)	-	-	-	1 (50)
Likely liver cyst infection (4/8)	50	67	HD	4 (100)	7900	161	-	6 (75)

^aADPKD, autosomal dominant polycystic kidney disease; CRP, C-reactive protein; HD, hemodialysis.

Table 2. Bacterial strains retrieved during 41 episodes of cyst infection in 36 patients with ADPKD

Infection (patients/episodes)	Positive Culture		
	Urine	Blood	Cyst Fluid
Definite renal cyst infection (6/6)	<i>Escherichia coli</i> (1) <i>Staphylococcus aureus</i> (1)	<i>Escherichia coli</i> (1)	<i>Escherichia coli</i> (1) <i>Staphylococcus aureus</i> (1) <i>Streptococcus</i> (1) <i>Anaerobic</i> (1)
Likely renal cyst infection (24/25)	<i>Escherichia coli</i> (13) <i>Lactobacillus</i> (1)	<i>Escherichia coli</i> (2)	
Liver cyst infection (6/10)		<i>Escherichia coli</i> (5) <i>Enterococcus faecium</i> (2)	<i>Citrobacter freundii</i> (1)

Table 3. Radiologic findings during 41 episodes of cyst infections in 36 patients with ADPKD

Infection (patients/episodes)	Radiologic Examination Performed (<i>n</i> [%] of Positive Radiologic Findings)			
	Ultrasound	CT Scan	MRI	PET Scan
Definite renal cyst infection (6/6)	3 (33)	5 (40)	1 (100)	3 (100)
Likely renal cyst infection (24/25)	10 (0)	18 (6)	1 (0)	1 (100)
Definite liver cyst infection (2/2)	0 (0)	1 (100)	1 (0)	1 (100)
Likely liver cyst infection (4/8)	5 (0)	4 (25)	2 (50)	3 (100)
Total (33/41)	18 (6)	28 (18)	5 (40)	8 (100)

Table 4. Patient outcomes depending on the type of antibiotherapy used for cyst infections in patients with ADPKD

Antibiotherapy	Efficacy (<i>n</i> [%])	Need for Modification of Antibiotherapy (<i>n</i> [%])	Need for Cyst Drainage (<i>n</i> [%])
β -Lactamine alone (<i>n</i> = 6)	2 (33)	4 (67)	
Fluoroquinolone alone (<i>n</i> = 12)	8 (66)	4 (33)	1 (8)
β -Lactamine + fluoroquinolone (<i>n</i> = 8)	6 (75)	2 (25)	3 (38)
β -Lactamine + aminoside (<i>n</i> = 6)	6 (100)		
Fluoroquinolone + aminoside (<i>n</i> = 5)	4 (80)		1 (40)
Others (<i>n</i> = 3)	3 (100)		
All (<i>n</i> = 41)	29 (71)	10 (24)	5 (12)

sisted of a probabilistic association of at least two antibiotics for 2 to 5 d. Antibiotic association included a fluoroquinolone in 16 episodes, a β -lactamine in 16, an aminoside in 12, trimethoprim-sulfamethoxazole in two, and vancomycin in one. Subsequently, patients received an antibiotic monotherapy, chosen according to the antibiogram, for 3 to 6 wk.

Initial antibiotic monotherapy was used in 18 episodes: Fluoroquinolone in 12 and β -lactamine in six. In eight (44%) of 18 episodes, monotherapy had to be changed because of persistent infection (persistent fever and increased CRP serum level): β -Lactamine had to be replaced by a fluoroquinolone in one case, by fluoroquinolone and another β -lactamine in two cases,

and by a fluoroquinolone and an aminoside in one case. Fluoroquinolone had to be replaced by a β -lactamine in two cases, and an aminoside had to be introduced in two cases. In all, a switch from monotherapy to bitherapy was required in five cases.

Radiologic and Surgical Procedures

Because of persistent or recurrent cyst infection, radiologic and/or surgical procedures were required for eight patients: Cyst drainage in five cases (renal cyst in four cases and liver cyst in one case) and surgery in four patients (nephrectomy in two cases and partial hepatectomy in two cases). The clinical

history of all eight patients for whom drainage and/or surgery was required is summarized next:

Patient 1 is a 54-yr-old woman who has ADPKD and was admitted for an infection of a right kidney cyst (8 × 5 cm) documented by a urine culture yielding *E. coli* and positive findings on CT and PET scans. Fever persisted despite 2 mo of antibiotic treatment (ceftriaxone and ofloxacin), and percutaneous cyst drainage was performed. *E. coli* was identified in cyst fluid. Subsequently, fever subsided and antibiotic monotherapy (ofloxacin) was continued for 1 mo after drainage. No cyst infection recurred.

Patient 2 is a 54-yr-old man who has ADPKD and undergoes hemodialysis; he was admitted for hematuria, fever, and abdominal pain. Urine and blood culture were negative. CT scan data were suggestive of cholecystitis. During cholecystectomy procedure, the surgeon performed a puncture of an inflammatory cyst in the right kidney. Cyst fluid culture was positive for *Streptococcus B*. After a 2-mo antibiotic treatment (amoxicillin-clavulanic acid, ofloxacin, and netromycin for 1 wk followed by a monotherapy using amoxicillin), right nephrectomy was performed. Histologic analysis disclosed the presence of multiple cysts with an inflammatory wall and presence of pus.

Patient 3 is 69-yr-old man who undergoes hemodialysis. He has a history of ADPKD complicated by several episodes of liver cyst infections documented by positive blood cultures. He received a 2-yr prophylactic antibiotic treatment (ciprofloxacin), and cyst infection did not recur. In the 6 mo after the discontinuation of prophylactic antibiotic treatment, he had three episodes of liver cyst infections documented by positive CT and PET scan findings. Cyst puncture was not feasible because of the localization of the cyst close to the right ventricle. A partial right hepatectomy was performed; however, the patient subsequently presented with recurrent episodes of liver cyst infections leading to liver abscess.

Patient 4 is a 51-yr-old man who undergoes hemodialysis. He was admitted for a cyst infection in the left kidney documented by positive blood cultures (*E. coli*) and CT scan findings. Cyst infection was associated with a pleural transudative effusion and atelectasis. The initial antibiotic treatment combined ciprofloxacin and netromycin for 3 d, then ciprofloxacin alone. Nephrectomy was subsequently performed because of the severity of the cyst infection and before renal transplantation.

Patient 5 is a 74-yr-old woman who has ADPKD and undergoes hemodialysis. She was referred for a recurrence of a liver cyst infection. In the previous 3 yr, she had presented with four hepatic cysts and one renal cyst infection that required treatment with fluoroquinolones and β -lactamine. On admission, the patient was started on ceftriaxone, netromycin, and ciprofloxacin; however, persistent fever and increased serum CRP levels led to three consecutive drainages, combined with ethanol sclerotherapy, of a large liver cyst (10 × 8 cm). Prolonged (>3 mo) treatment with trimethoprim-sulfamethoxazole was started as cyst fluid grew positive for *Citrobacter freundii*; however, cyst infection recurred 10 d after antibiotic treatment discontinuation, and blood culture grew positive for *C. freundii*. Subsequently, the patient underwent partial right hepatectomy complicated by postoperative abdominal abscesses. Drainage

of the abscess was required twice. Linezolid and imipenem were started as abscess fluid grew positive for methicillin-resistant *Staphylococcus aureus* and *Enterococcus faecium*. After the drain removal, the abscess reappeared and the patient underwent a surgical removal of the abscess.

Patient 6 is a 62-yr-old woman who undergoes hemodialysis; she was admitted for fever and abdominal pain. Blood cultures were positive for *E. coli*. Ultrasound and CT scan were unremarkable, but a PET scan disclosed signs of infection in a right liver cyst. Antibiotic treatment (ofloxacin and ceftriaxone) was started for 6 wk. Cyst infection, documented by positive blood cultures (*E. coli*) and a second PET scan, recurred 5 mo later. An 8-wk treatment with amikacin and ceftazidime led to clinical remission, and a follow-up scan showed no sign of liver cyst infection (Figure 1).

Patient 7 is a 53-yr-old man who has ADPKD and was admitted for fever, abdominal and lumbar pain, and hematuria. Urine culture was positive for *S. aureus*. Abdominal CT scan was inconclusive. Despite a 7-d antibiotic treatment using ciprofloxacin, fever and abdominal pain persisted. A second abdominal CT scan disclosed the presence of an abscess in a right kidney cyst. Gentamycin was added to ciprofloxacin; cyst drainage was performed and apyrexia ensued. Cyst fluid drainage grew positive for *S. aureus*. Subsequently, the patient received a 4-wk course of ciprofloxacin.

Patient 8 is a 53-yr-old man who has ADPKD and was admitted for abdominal pain (left quadrant), fever, and hematuria. Urine and blood cultures were negative. Abdominal CT scan and MRI did not disclose any sign of infected cyst. Fever persisted despite 15 d of ofloxacin. A PET scan showed the presence of an ongoing infection in a left kidney cyst. Cyst drainage was then performed, and neutrophil debris was retrieved in the cyst fluid. Cyst fluid culture was negative. Ceftriaxone was started for 6 wk. Cyst infection did not recur.

Discussion

Even though cyst infection is reported in most nephrology textbooks as one of the most frequent complication of ADPKD, published data regarding this ADPKD complication are relatively scarce. We report on the largest series to date of cyst infection episodes in patients with ADPKD.

In this study, conducted in a referral center for ADPKD during an 11-yr period, cyst infections were relatively infrequent with an incidence estimated at 0.01 episode per patient per year. Cyst infections accounted for only approximately 10% of causes that led to hospitalization of patients with ADPKD.

Moreover, this report illustrates the clinical dilemma of cyst infections in patients with ADPKD. Definite diagnosis of cyst infection, defined by a positive culture of cyst fluid and/or presence of neutrophil debris, is relatively rare and was made in only one of five episodes in this study. In clinical practice, likely cyst infections are more frequent than definite cyst infections. The criteria for the diagnosis of likely cyst infections defined in this study are those commonly used by clinicians. These criteria rely solely on clinical and simple biologic features. Usual radiologic examinations are often of little help in the diagnosis of cyst infections. For instance, in our series,

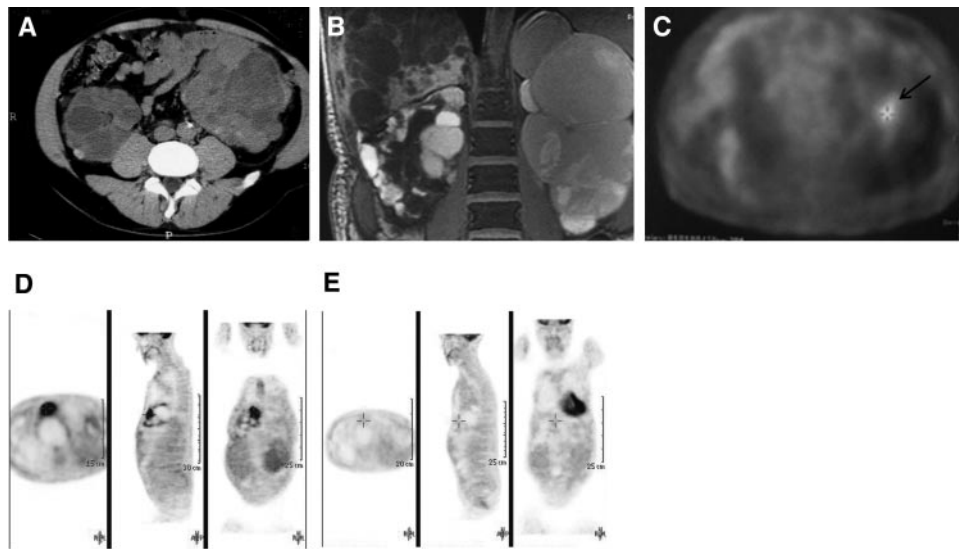


Figure 1. A 53-yr-old man with autosomal dominant polycystic kidney disease (ADPKD) and chronic kidney disease (GFR 30 ml/min per 1.73 m²) presented with fever, abdominal pain (upper left quadrant), and increased serum C-reactive protein level. A left kidney cyst infection was suspected. (A through C) A nonenhanced computed tomography (CT) scan (A) and magnetic resonance imaging (T2-weighted sequence; B) disclosed several renal cysts with variable fluid density in the absence of overt signs of cyst infection; however, a positron emission tomography (PET) scan (C) showed an area of increased FDG uptake (arrow) highly suggestive of ongoing infection in a left kidney cyst. (D) A 62-yr-old woman who had ADPKD and was undergoing hemodialysis (patient 6) was admitted for fever and abdominal pain (upper right quadrant). Blood cultures grew positive for *Escherichia coli*. Abdominal CT scan was inconclusive. A PET scan disclosed an ongoing infection in a liver cyst (arrow). (E) A control PET scan performed 1 mo after antibiotherapy (ciprofloxacin) showed the resolution of cyst infection (dashed arrow). Positive signal on the last frame occurs in the heart.

ultrasonography, CT, and MRI failed to detect the infected cyst in 94, 82, and 60% of cases, respectively, and most importantly yielded negative results in more than half of patients with a definite diagnosis of cyst infections. In contrast, PET scan proved highly efficient in identifying renal and hepatic infected cysts in all tested patients. Our data confirm recent reports underlining the high performance of PET scan in the diagnosis of cyst infections (5–7). PET scan is a reliable tool for the detection of tissue infection, on the basis of the high metabolic activity and increased uptake of the glucose analogue FDG in inflammatory cells. In this study, PET scan proved helpful in identifying infected cysts in patients with variable renal function ranging from mildly reduced GFR to ESRD. PET scan is probably the first-line optimal tool for the detection of infected cysts in patients with ADPKD and patient follow-up after antibiotherapy. It may also prove helpful for defining new diagnostic criteria for cyst infections in patients with ADPKD; however, to the best of our knowledge, PET scan has not been evaluated in intracystic bleeding, the main differential diagnosis of cyst infections in patients with ADPKD. Moreover, increased FDG uptake has been reported in the setting of hematoma occurring in various extrarenal sites (8,9). Thus, the specificity of PET scan for cyst infections remains to be assessed. Nonetheless, significant intracystic bleeding is easily detected on CT scan. Thus, significant intracystic bleeding usually had been ruled out by CT scan in patients who had ADPKD and were undergoing a PET scan for suspected cyst infection.

In our series, cyst infections occurred more frequently in

kidney compared with liver. Surprisingly, half of the patients who presented with liver cyst infections were male. Indeed, massive polycystic liver disease has been reported predominantly in women, and one would have expected liver cyst infections to occur almost exclusively in women (10). The other remarkable finding is that one of five episodes of renal cyst infection episodes and all liver cyst infection episodes occurred in patients who were undergoing dialysis. Renal infection has been reported in 12 to up to 26% of patients who had ADPKD and were undergoing hemodialysis (11), and predialysis history of cyst infections correlates with the occurrence of similar infectious events on hemodialysis. Thus, clinicians should not overlook the diagnosis of cyst infections in patients who have ADPKD and are undergoing hemodialysis and present with fever and/or abdominal pain.

Microbiological documentation was available for almost two thirds of episodes of cyst infections, allowing the modification of the initial probabilistic antibiotic treatment. In the case of renal cysts, isolated microorganisms included the usual Gram-negative bacteria involved in urinary tract infections, with *E. coli* accounting for three quarters of cases. This finding suggests an ascending mechanism for cyst infection, at least in the case of positive urine culture. In episodes of hepatic cyst infections, all isolated bacteria were commonly found in the digestive tract; however, bacteria less frequently encountered in urinary tract infections, such as *S. aureus*, *Enterococcus* species, lactobacillus, and anaerobic bacteria, accounted for 15% of all cyst infection episodes. Streptococcus (12), Staphylococcus (13), an-

aerobic gas-forming germs (14,15), and *Candida albicans* have been previously reported in infected cysts in patients with ADPKD (16). The low oxygen tension within cysts may support the potential for anaerobic infections. Repeated antibiotic courses and drainage and surgery procedures may also lead to the emergence of nosocomial bacterial strains, as in patient 5. These data underline the need for a bacteriologic documentation, by cyst aspiration if required, in cyst infection episodes that do not favorably respond to probabilistic treatment.

Fluoroquinolones and third-generation cephalosporins remain the standard treatment for cyst infections in patients with ADPKD and were used in 95% of the patients included in this study. Intracyst antibiotic diffusion and accumulation vary widely and probably depend on passive diffusion as well as active transepithelial transport. Fluoroquinolones are usually favored because of their lipophilic properties that lead to an increased diffusion in infected cysts and their bactericidal activity against Gram-negative enteric pathogens. In contrast, β -lactamines, mainly penicillins and cephalosporins, usually penetrate poorly into cysts (Table 5); however, available data regarding antibiotic intracystic diffusion have been partly obtained in noninfected cysts (17,18). Antibiotic diffusion may be

different in infected cysts as a result of inflammation-induced hyperpermeability in vessels that line the cyst wall. It proves hard to draw any definite conclusion regarding antibiotic treatment in cyst infections on the basis of our data because of the retrospective design of this study and the variable size and location of infected cysts; however, our data suggest that fluoroquinolones may be superior to β -lactamine and bitherapy superior to monotherapy in treating cyst infections in patients with ADPKD (Table 4). Moreover, on the basis of our experience, large (diameter >5 cm) infected cysts, particularly hepatic cysts, require early drainage, because antibiotics alone do not usually cure the infection. Our data are in accordance with previous reports suggesting that drainage and antibiotics prove more efficacious than antibiotics alone in hepatic cyst infections (7).

Conclusions

Cyst infections in patients with ADPKD remain a challenging diagnostic and therapeutic issue. PET scan will probably make the diagnosis of cyst infections easier and more accurate. Antibiotic association, including a fluoroquinolone, remains the main treatment for cyst infections. Large (diameter >5 cm)

Table 5. Published data regarding intracyst antibiotic diffusion in patients with ADPKD

Reference	No. of Patients	Cyst Location	Antibiotic	Intracystic Antibiotic Diffusion
Telenti <i>et al.</i> (7)	3	Liver	Ciprofloxacin	Good
	1		Chloramphenicol	Good
Bennett <i>et al.</i> (17)	10	Kidney	Amoxicillin	Poor on day 1/good on day 6
			Aminoside	Poor
			Clindamycin	Good
			Metronidazole	Good
			Bactrim	Good
			Vancomycin	Good
Elzinga <i>et al.</i> (18)	7	Kidney	Ciprofloxacin (oral)	Good
				Concentration ratio cyst/serum 2.5
Hiyama <i>et al.</i> (12)	1	Kidney	Ampicillin	Poor
			Levofloxacin	Good
Elzinga <i>et al.</i> (19)	8	Kidney	Trimethoprim	Good
				Concentration ratio cyst/serum >8
			Sulfamethoxazole	Poor
Schwab <i>et al.</i> (20)	1	Kidney	Trimethoprim	Good
			Sulfamethoxazole	Poor
Schwab <i>et al.</i> (21)	1	Kidney	Clindamycin	Good
				Concentration ratio cyst/serum 0.07 to 0.70
			Gentamycin	Poor
				Concentration ratio cyst/serum 2.4 to 8.7
				Concentration ratio cyst/serum 0.18 to 0.34

infected cysts, particularly liver cysts, require drainage associated with antibiotic treatment.

Disclosures

None.

References

1. Sklar AH, Caruana RJ, Lammers JE, Strauser GD: Renal infections in autosomal dominant polycystic kidney disease. *Am J Kidney Dis* 10: 81–88, 1987
2. Gardner KD Jr, Evan AP: Cystic kidneys: An enigma evolves. *Am J Kidney Dis* 3: 403–413, 1984
3. Gibson P, Watson ML: Cyst infection in polycystic kidney disease: A clinical challenge. *Nephrol Dial Transplant* 13: 2455–2457, 1998
4. Pei Y, Obaji J, Dupuis A, Paterson AD, Magistroni R, Dicks E, Parfrey P, Cramer B, Coto E, Torra R, San Millan JL, Gibson R, Breuning M, Peters D, Ravine D: Unified criteria for ultrasonographic diagnosis of ADPKD. *J Am Soc Nephrol* 20: 205–212, 2009
5. Migali G, Annet L, Lonneux M, Devuyst O: Renal cyst infection in autosomal dominant polycystic kidney disease. *Nephrol Dial Transplant* 23: 404–405, 2008
6. Bleeker-Rovers CP, de Sévaux RG, van Hamersvelt HW, Corstens FH, Oyen WJ: Diagnosis of renal and hepatic cyst infections by 18-F-fluorodeoxyglucose positron emission tomography in autosomal dominant polycystic kidney disease. *Am J Kidney Dis* 41: E18–E21, 2003
7. Telenti A, Torres VE, Gross JB Jr, Van Scoy RE, Brown ML, Hattery RR: Hepatic cyst infection in autosomal dominant polycystic kidney disease. *Mayo Clin Proc* 65: 933–942, 1990
8. Repko BM, Tulchinsky M: Increased F-18 FDG uptake in resolving atraumatic bilateral adrenal hemorrhage (hematoma) on PET/CT. *Clin Nucl Med* 33: 651–653, 2008
9. Ryan A, McCook B, Sholosh B, Pryma DA, Jablonowski E, Fuhrman C, Blodgett TM: Acute intramural hematoma of the aorta as a cause of positive FDG PET/CT. *Clin Nucl Med* 32: 729–731, 2007
10. Grunfeld JP, Albouze G, Jungers P, Landais P, Dana A, Droz D, Moynot A, Lafforgue B, Boursztyrn E, Franco D: Liver changes and complications in adult polycystic kidney disease. *Adv Nephrol Necker Hosp* 14: 1–20, 1985
11. Christophe JL, van Ypersele de Strihou C, Pirson Y: Complications of autosomal dominant polycystic kidney disease in 50 haemodialysed patients: A case-control study. The U.C.L. Collaborative Group. *Nephrol Dial Transplant* 11: 1271–1276, 1996
12. Hiyama L, Tang A, Miller LG: Levofloxacin penetration into a renal cyst in a patient with autosomal dominant polycystic kidney disease. *Am J Kidney Dis* 47: e9–e13, 2006
13. Chapman AB, Thickman D, Gabow PA: Percutaneous cyst puncture in the treatment of cyst infection in autosomal dominant polycystic kidney disease. *Am J Kidney Dis* 16: 252–255, 1990
14. Van Zijl PS, Chai TC: Gas-forming infection from *Clostridium perfringens* in a renal cyst of a patient with autosomal dominant polycystic kidney disease. *Urology* 63: 1178–1179, 2004
15. Erkok R, Sayarlioglu H, Ceylan K, Dogan E, Kara PS: Gas-forming infection in a renal cyst of a patient with autosomal dominant polycystic kidney disease. *Nephrol Dial Transplant* 21: 555–556, 2006
16. Hepburn MJ, Pennick GJ, Sutton DA, Crawford GE, Jorgensen JH: *Candida krusei* renal cyst infection and measurement of amphotericin B levels in cystic fluid in a patient receiving AmBisome. *Med Mycol* 41: 163–165, 2003
17. Bennett WM, Elzinga L, Pulliam JP, Rashad AL, Barry JM: Cyst fluid antibiotic concentrations in autosomal-dominant polycystic kidney disease. *Am J Kidney Dis* 6: 400–404, 1985
18. Elzinga LW, Golper TA, Rashad AL, Carr ME, Bennett WM: Trimethoprim-sulfamethoxazole in cyst fluid from autosomal dominant polycystic kidneys. *Kidney Int* 32: 884–888, 1987
19. Elzinga LW, Golper TA, Rashad AL, Carr ME, Bennett WM: Ciprofloxacin activity in cyst fluid from polycystic kidneys. *Antimicrob Agents Chemother* 32: 844–847, 1988
20. Schwab SJ, Weaver ME: Penetration of trimethoprim and sulfamethoxazole into cysts in a patient with autosomal-dominant polycystic kidney disease. *Am J Kidney Dis* 7: 434–438, 1986
21. Schwab S, Hinthorn D, Diederich D, Cuppage F, Grantham J: PH-dependent accumulation of clindamycin in a polycystic kidney. *Am J Kidney Dis* 3: 63–66, 1983

See related editorial, “Managing Cyst Infections in ADPKD: An Old Problem Looking for New Answers,” on pages 1154–1155.

Access to UpToDate on-line is available for additional clinical information at <http://www.cjasn.org/>