

Stent Placement in Hemodialysis Access: Historical Lessons, the State of the Art and Future Directions

Alexander Yevzlin* and Arif Asif[†]

*Department of Medicine, Section of Interventional Nephrology, University of Wisconsin School of Medicine and Public Health, Madison, Wisconsin; [†]Department of Medicine, Section of Interventional Nephrology, University of Miami Miller School of Medicine, Miami, Florida

Vascular access stenosis in patients undergoing chronic hemodialysis is a major issue that is associated with increased morbidity, mortality, and cost of medical care. Recent data have emphasized that endovascular stents could be used in the treatment of central as well as peripheral stenotic lesions. In general, a peripheral or central vein lesion that is elastic or recurs within a three-month period after an initially successful balloon angioplasty or a stenosis where surgical revision is not possible are some indications for intravascular stent placement. Recent reports have expanded the role of stents in the management of pseudoaneurysms associated with dialysis access. In this context, the utilization of these devices must take into account a fair comparison with the traditional (surgical) approaches regarding effectiveness as well as costs. This report describes the role of stents in arteriovenous dialysis access. In addition, some of the recent advances in the structure and complicating issues such as stent fracture, migration, and infection, as well cannulation through the stent, are discussed.

Clin J Am Soc Nephrol 4: 996–1008, 2009. doi: 10.2215/CJN.04040808

The word “stent” originates in the dentistry literature to describe a molding compound invented by Charles Stent in 1856 (1). Stents have since come to be known broadly as any structure that provides support for tissues *in vivo*. The concept of intravascular stent placement grew directly out of cardiology experience with early percutaneous transluminal angioplasty (PTA). Although the artery would be dilated successfully using a balloon, in a small percentage of cases, it collapsed shortly thereafter. This phenomenon came to be known as “elastic recoil” and necessitated emergency bypass graft surgery until the advent of the stent. In 1986, Puel and Sigwart (2) deployed the first coronary stent. This “scaffold” functioned to prevent vascular closure during PTA, and it reduces the incidence of coronary restenosis in the modern era (3). Indeed, coronary percutaneous intervention is currently the most common and largely successful medical procedure in the world, due in no small part to the advent of endovascular stent placement (3–5).

While the insertion of stents in the coronaries has been largely successful, conflicting data continue to surround their use in the discipline of hemodialysis access. Clinical scenarios such as insertion of a stent at the vein-graft anastomosis *versus* the creation of a secondary fistula when possible, continue to perplex the interventionalist (6,7). Such management uncertainties are particularly important for three main reasons. First, they can lead to underutilization and consequent loss of device-

associated benefit. Second, they can result in the overutilization of stents, resulting in an increase in device-associated complications in the absence of their undisputed benefit. Third, they can cause a tremendous increase in the cost of medical care. Indeed, recent information from United States Renal Data System (USRDS) is reporting a marked increase of stent placement in hemodialysis access (Figure 1) (8). While the total number of access interventions increased from 52,380 to 98,148 (a 1.8 fold increase), the number of stent placements has increased from 3792 to 8514, a 2.2 fold increase (Table 1) (8). Of note, the relative percentage growth of stent placement has outpaced that of angioplasty each year during the same time period (Figure 2) (8).

The concerns associated with use of intravascular stents are critically important as vascular access assumes a more central role in nephrology. This report familiarizes nephrologists with the current understanding of intravascular stent placement in the management of dialysis-access stenosis. The use of stents in the peripheral and central vasculature is addressed and the role of stents for the obliteration of aneurysms and ruptured vessels is also depicted. In addition, some recent advances in the structure and complicating issues, such as stent fracture, migration, infection, as well cannulation through the stent, are also discussed.

Stents and Peripheral Venous Stenosis

Some of the studies evaluating the role of stents in the treatment of peripheral hemodialysis access lesions are presented (Table 2). The insertion of an intravascular stent in a patient with dialysis access followed soon after coronary stent placement. Zollikofer *et al.* (9) were the first to report stent deployment in the outflow track of an arteriovenous fistula (AVF) or

Published online ahead of print. Publication date available at www.cjasn.org.

Correspondence: Dr. Arif Asif, Associate Professor of Medicine, Director, Interventional Nephrology, University of Miami Miller School of Medicine, Miami, FL 33136. Phone: 305-243-3583; Fax: 305-243-3506; E-mail: Aasif@med.miami.edu

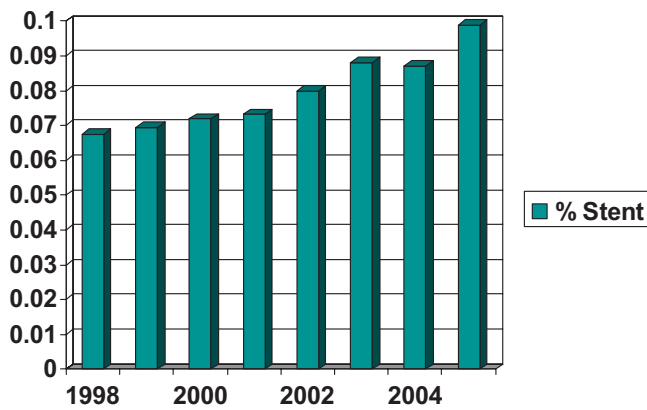


Figure 1. Stent placement increase (%) 1998–2005.

Table 1. Number of PTA^a and stent procedures performed in the US 1998–2005

Year	Number of PTA procedures	Number of stent procedures
1998	52,380	3792
1999	66,235	4953
2000	70,602	5468
2001	82,550	6518
2002	98,148	8514
2003	111,825	10,801
2004	128,745	12,327
2005	139,024	15,260

^aPTA, percutaneous transluminal angioplasty

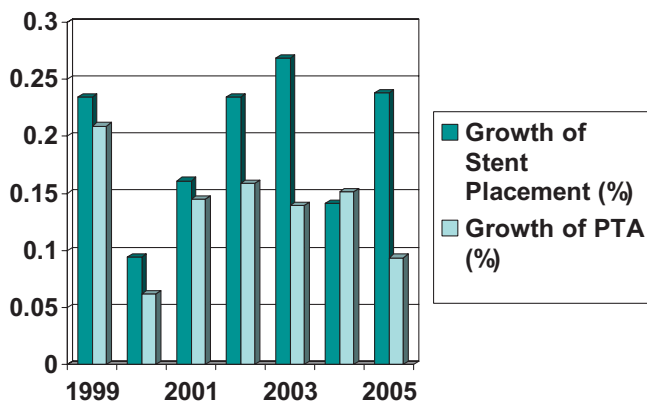


Figure 2. Relative growth of stent and PTA procedures 1999–2005.

an arteriovenous graft (AVG) in 1988. In this seminal work, the authors reported successful stent placement in four patients. Subsequently, the same group published a study in which seven patients received stents for 13 AVF outflow lesions (10). The mean assisted patency rate was 9.7 mo on follow-up angiography, although all patients were noted to have in-stent restenosis.

Based on these early studies, the 1990s witnessed several

randomized trials of stent *versus* PTA. The outcomes evaluated in these studies include primary patency (time from access creation to first intervention) and assisted patency (time from access creation to final failure of the access, also referred to as secondary and overall patency). Quinn *et al.* (11), in 87 patients, found the primary patency rates for PTA at 60, 180, and 360 d to be 55%, 31%, and 10%, respectively. For the stent group, the primary patency rates were 36%, 27%, and 11% at 60, 180, and 360 d, respectively ($P = 0.6528$). Also, no difference was noted in secondary patency rates between the PTA and stent groups (11). Similarly, Beathard *et al.* (12) evaluated 58 patients with 50% or greater stenosis who were randomly assigned to a stent or a PTA group. The results disclosed no significant difference in any parameter before treatment, in the response to intervention, or in the patency rates compared with the PTA group, with 90-, 180-, and 360-d survival of 85% to 92%, 72% to 82%, and 17% to 19% for stents and 79%, 64%, and 28% for PTA, respectively ($P > 0.07$) (12).

Another prospective randomized trial of 37 cases concluded that, despite significant added costs, there was no advantage to stent placement for recurrent AVG stenoses that were already adequately dilated with balloon angioplasty (13). The primary patency rates for PTA at 30, 60, 180, and 360 d were 89%, 53%, 23%, and 7%, respectively. The primary patency rates for the stents at 30, 60, 180, and 360 d were 81%, 56%, 12%, and 0%, respectively. The secondary patency rates for PTA were 100%, 81%, and 47%, and were 100%, 81%, 69%, and 60% for stents. The mean primary, primary assisted, and secondary patency for the PTA group was 137, 395, and 432 d, respectively; whereas for the stent group, these measures were 119, 327, and 431 d, respectively. The authors noted that the difference in patency rates between the two groups were not statistically significant (13).

Multiple recent observational studies with no comparative group were published from 2000 to the present time (14–23). Unfortunately, the observational nature of these investigations (the lack of comparison group), as well as the small sample size, remain fundamental limitations in applying these results to clinical practice.

Recent technological advances (*e.g.*, novel alloys, delivery systems) and improvement in interventional techniques have spurred some investigators to evaluate new stent technology in the management of access stenosis. Vogel *et al.* (24) performed a retrospective analysis of 64 patients with AVGs who were treated with the shape memory alloy stents at 69 locations in the venous outflow system. Twenty stents were deployed in cases of elastic recoil after PTA, venous rupture, or recurrent stenosis less than 3 mo after PTA. Stents were placed in 15 central veins and 54 peripheral veins, with a 97% clinical success rate. The primary access patency was 14.9 mo and 8.9 mo in patients who received central and peripheral stents. In 19 patients whose central or peripheral venous stenoses were previously treated with angioplasty, the mean primary access patency was increased from 2.5 mo to 10.6 mo after placement of the stents ($P < 0.005$). Angiography in 29 patients showed 55% mean in-stent restenosis after an average of approximately 1 yr.

Table 2. Some studies evaluating the role of stents in the treatment of peripheral hemodialysis access lesions are presented

Author (Reference)	Study Design	Year of Publication	Number of Cases	Primary Patency	Secondary Patency	Notes
Chan, MP (28)	Retrospective	2007	211	91% versus 80% at 30 d, 69% versus 24% at 90 d, and 25% versus 3% at 180 for AVG	N/A	The primary assisted AVF patency did not differ significantly between the stent and angioplasty groups.
Vesely, TM (27)	Retrospective	2007	70	81%, 70%, and 54% at 1, 3, and 6 mo for PTA, respectively, 96%, 93%, 87%, and 47% at 1, 3, 6, and 12 mo for stent, respectively	89%, 82%, and 74% at 3, 6, and 12 mo for stent, respectively	Multiple stent types
Maya ID (28)	Retrospective	2006	48	median survival, 85 versus 27 d, $P = 0.02$	median survival, 1215 versus 46 days, $P = 0.049$	Thrombosed AVG only
Vogel PM (24)	Prospective, non-randomized	2005	60	5.6 mo after PTA and 8.2 mo after stent treatment ($P = 0.050$)	N/A	
Haage P (35)	Observational (no control group)	1999	50	3-, 6-, 12-, and 24-mo rates were 92%, 84%, 56%, and 28%, respectively	97% after 6 and 12 mo, 89% after 24 mo, and 81% after 36 and 48 mo	
Hoffer EK (13)	Prospective, randomized	1997	37	Primary patency of 128 d and secondary patency of 431 d were similar for both groups.	Secondary patency required a mean of 1.8 and 1.6 additional interventions for the PTA and stent groups, respectively.	The adjunctive stent placement increased the cost of the procedure by 90%.
Quin SF (11)	Prospective, randomized	1995	87	PTA at 60, 180, and 360 d were 55%, 31%, and 10%, respectively, and for stents were 36%, 27%, and 11%, respectively ($P = 0.6528$)	PTA at 60, 180, and 360 d were 94%, 80%, and 71%, respectively, and for stents were 73%, 64%, and 64%, respectively ($P = 0.1677$)	No difference between stent and PTA was found.
Beathard GA (12)	Prospective, randomized	1993	58	100% at 30 d, 91% at 60 d, 85% at 90 d, 72% at 180 d, and 17% at 360 d	N/A	No difference between stent and PTA was found.

The authors concluded that this type of stent (nitinol alloy) is safe and effective for treating dialysis-access venous stenoses that are resistant to standard angioplasty.

While the results were encouraging, the study had several limitations. In addition to the lack of randomization, AVGs and AVFs were mixed in the analysis, the type of lesion (e.g., inflow, outflow, or central) was not uniform and patient characteristics (e.g., diabetic or not) were not accounted for in the analysis. The presence of these confounding factors does not conclusively establish the superiority of stents over percutaneous balloon angioplasty.

The same authors followed their initial investigation of the nitinol stent with a prospective study comparing stent placement with PTA (25). A nonrandomized study was conducted in 60 patients with AVG dysfunction. The indications for stent placement were similar to previous studies and included acute PTA failure, rapid restenosis, and vessel perforation. Thirty-five patients showed a response to PTA alone. The remainder received stents. Restenosis after intervention was less frequently observed in the stent group compared with angioplasty alone (7% versus 16%, $P = 0.001$). The primary graft patency was 5.6 mo after PTA and 8.2 mo after stent treatment ($P = 0.05$). Interestingly, the authors noted that the primary patency was similarly improved for stents placed across the level of the elbow joint.

Differences exist in patency rates between forearm and upper arm arteriovenous accesses. Kolakowski *et al.* (26) performed a prospective, nonrandomized study on 61 subjects comparing the use of stents in the forearm versus the upper arm. The primary patency rates at 3, 6, and 12 mo in the forearm group were 36.4%, 15.6%, and 0%, respectively. This did not compare favorably with the 59.5%, 34.0%, and 17.0% primary patency rate observed for upper arm grafts ($P = 0.0307$). Secondary patency rates did not differ between the distal and proximal arm with rates of 40.9%, 40.9%, and 30.7%, over the above-time interval, for forearm grafts, and 64.9%, 42.3%, and 19.7% for upper arm grafts ($p = \text{NS}$). Although the latter investigation was an important contribution in that it was prospective and attempted to define the role of access location, it did not compare stent outcomes with angioplasty directly.

While patency of the access circuit is crucial, the patency of the stent *per se* (target lesion) may also be an important consideration. In one study, 70 subjects were retrospectively evaluated with stent placement (27). The primary patency of the vascular access was 81%, 70%, and 54% at 1, 3, and 6 mo. Secondary patency of the vascular access was 89%, 82%, and 74% at 3, 6, and 12 mo. Interestingly, the primary patency of the stent *per se* was 96%, 93%, 87%, and 47% at 1, 3, 6, and 12 mo. This investigation suggests that other areas of the access circuit are the likely culprits in its ultimate demise.

Whereas the aforementioned studies have primarily focused on the patency rates, a recent study included the assessment of post-stent access blood flow and urea reduction ratio (URR) determination (28). In this retrospective study ($n = 211$), the primary assisted AVG patency was significantly longer for the stent group as compared with angioplasty, with a median survival of 138 versus 61 d, respectively ($P < 0.001$). The pri-

mary AVG patency for stent versus angioplasty was 91% versus 80% at 30 d, 69% versus 24% at 90 d, and 25% versus 3% at 180 d, respectively. The primary assisted AVF patency did not differ significantly between the stent and angioplasty groups. In patients dialyzing via AVF, multiple regression analysis revealed that stent placement was associated with improved after-intervention peak blood flow (Qa), 1627.50 ml/min versus 911.00 ml/min ($P = 0.008$), change in Qa from before to after intervention, 643.54 ml/min versus 195.35 ml/min ($P = 0.012$), and change in URR from before to after intervention, 5.85% versus 0.733% ($P = 0.039$). All of the stents in this study were uncovered, nitinol stents. Although limited by its retrospective design, these results suggest that stent placement in the modern era may be associated with improved AVG primary patency and improved AVF blood flow.

It is important to note that the use of stents in dialysis access stenosis has represented an off-label use of this device in dialysis applications. However, a recent multi-center, randomized study that evaluated the role of a covered stent (FLAIR; Bard Peripheral, Tempe, AZ) in the treatment of vein-graft anastomotic stenosis was the first to bring this device to approval by FDA (<http://www.fda.gov/cdrh/pdf6/p060002.html>). A total of 227 patients were included in this study at 16 US investigational sites. The safety and effectiveness of the covered stent compared with percutaneous balloon angioplasty was evaluated. Patients ($n = 97$) were randomized to the treatment (a covered stent [stent graft]) or balloon angioplasty procedure ($n = 93$). The results revealed that the treatment area primary patency at six months in the stent graft group was significantly higher than that found in the balloon angioplasty cohort (stent graft = 50.55%, angioplasty = 23.28%; $P < 0.001$). Importantly, this study also evaluated the primary patency of the entire access circuit. The access circuit primary patency ended when an intervention was performed anywhere within the circuit for stenosis or occlusion. A surgical intervention that excluded the index stenotic area from the access circuit also ended the access circuit primary patency. The results demonstrated that the primary patency for the access circuit at six months in the stent graft group was significantly higher than that found in the balloon angioplasty cohort (stent graft = 38.04%, angioplasty = 19.77%; $P < 0.001$). Based on the findings of this study, FDA has recently approved the use of this stent graft in the treatment of vein-graft anastomotic stenosis. This is the first and thus far the only stent graft that is approved by FDA for use in dialysis access.

Stent and Thrombosed Access

The above-cited studies have assessed the role of endovascular stent placement in patent accesses. Recently, however, stents have been employed in the treatment of thrombosed accesses. In one study, Maya *et al.* evaluated whether graft patency following thrombectomy is improved by placement of a stent in the stenotic lesion (29). Using a prospectively collected computerized vascular access database, the authors identified 14 patients with thrombosed AVGs treated with a stent at the venous anastomosis. The outcomes of these grafts were historically compared with those observed in 34 demographi-

cally matched control patients whose thrombosed AVGs were treated with PTA alone. The primary patency rate was greater for the stent group, with a median survival of 85 *versus* 27 d ($P = 0.02$). The secondary patency rate was also greater for the stent group, with a median survival of 1215 *versus* 46 d ($P = 0.049$). The strength of this investigation is that the authors focused only on AVGs, that only the subset of patients with thrombosed accesses was analyzed, and that the location of the stenoses was restricted to the venous anastomosis.

Why would the patency of a stent that was deployed in a thrombosed access be any different than the patency of a stent deployed in a patent access? To the best of the authors' knowledge, at present, there are no prospective studies comparing stent patency for thrombosed *versus* patent access. It is worth mentioning that, in general, patency for a thrombosed access (stent or no stent placed) is inferior to a patent access. Thrombosed and patients with patent accesses perhaps should be viewed as two different populations. For example, why do some individuals with stenosis thrombose and continue to experience recurrent thrombosis despite good treatment of stenosis, while others continue to remain patent for the same degree of stenosis. Certain differences exist in the thrombectomy procedure and percutaneous balloon angioplasty procedure. For example, a thrombectomy procedure is liable to cause more luminal damage and leave the luminal surface thrombogenic at the conclusion of the procedure. The nature of the procedure might make patients undergoing a thrombectomy procedure more vulnerable to subsequent thrombosis. The evidence for this was first provided by T.M. Vesely. Using angiography, Dr. Vesely inspected the inner surface of an arteriovenous graft and found it to be damaged due to the procedure. While stent in the target lesion might remain patent, the thrombogenic surface so created will cause the demise of the access and terminate patency of the circuit. Other factors such as coagulation abnormalities might lead to access thrombosis in certain patients.

Stents and Central Venous Stenosis

Some of the studies evaluating the role of stents in the treatment of peripheral hemodialysis access lesions are presented (Table 3). The role of stent placement in the treatment of central venous stenosis (CVS) is widely regarded as less controversial than in the peripheral veins. Indeed, the Society of Interventional Radiology (SIR) guidelines have indicated stent placement for central vein lesions (30). Some investigators have even argued that central venous lesions represent a primary indication for stent placement due to the poor outcome usually found with balloon dilation alone (18,31). The work of Gerald Beathard supports this assertion (32). In his seminal study, lesions were classified by location and type (32). Central lesions had the worst secondary patency with only 28.9% of all lesions remaining patent at 180 d, compared with a secondary patency 61.3% for peripheral lesions treated with PTA alone ($P < 0.01$) (32).

An earlier study from the 1990s evaluated the use of stents in 52 hemodialysis patients with 56 lesions (33). Thirty-two lesions were in central veins and 24 were in peripheral veins. Stents

were placed immediately after failed angioplasty in 39 patients. The primary patency rate was 46% at 6 mo and 20% at 12 mo. The assisted patency rate was 76% at 6 mo and 33% at 12 mo. In this study, the causes of recurrence included intimal hyperplasia in or near the stent, stent slippage, and stenosis in another part of the access circuit. Complications included two stent migrations due to central line placement and one stent-related pseudoaneurysm. Although in this study the outcomes were not reported separately for central *versus* peripheral lesions, the authors state that the patency rates were similar among the various lesion locations.

While intravascular stents have been inserted following failed angioplasty, Haage *et al.* (34), in 1999, analyzed the effectiveness of stent placement as the primary treatment for central venous obstruction in hemodialysis patients. Fifty-seven stents were placed in 50 patients with access dysfunction and arm swelling due to CVS. The primary patency rates were 92%, 84%, 56%, and 28% at 3, 6, 12, and 24 mo. Secondary patency was 97% at 6 and 12 mo, 89% after 24 mo, and 81% after 36 and 48 mo. Seventy-three episodes of restenosis occurred during the duration of the study. Nineteen cases (26%) necessitated additional stent placement. Aytakin *et al.* (18) evaluated the efficacy of stent placement for treating upper extremity CVS in 14 hemodialysis patients. The 1, 3, 6, and 12 mo primary patency rates were 92.8%, 85.7%, 50%, and 14.3%. Repeat interventions, including PTA and additional stent placement, were required in nine patients (64%). The 3-, 6-, 12-mo, and 2-yr secondary patency rates were 100%, 88.8%, 55.5%, and 33.3% (18). It is important to note that the investigators placed central vein stents as a primary treatment for central stenosis; there was no attempt at initial angioplasty.

In contrast to these relatively modest outcomes, one study achieved an enviable 70% primary patency at two years (16). Fifteen stainless steel stents were implanted in 10 hemodialysis patients for the treatment of symptomatic CVS. Stent deployment functioned to relieve symptoms in all cases. Although limited by its small sample size, this was the first study to describe the outcomes of stent placement exclusively in central lesions.

Sprouse *et al.* (35) similarly endeavored to determine the success of percutaneous therapy for relieving symptoms and maintaining central venous patency in hemodialysis patients with CVS. PTA or stent placement or both were performed as indicated in 32 lesions. PTA was followed by stent placement in six cases (19%). Patient symptoms were controlled for 6.5 mo after the initial intervention. Recurrent edema led to additional PTA in 20 cases (63%). Fifty percent of the patients in the study with an AVF experienced recurrent symptoms after initial intervention and required access ligation. Importantly, the authors observed that complete resolution after the initial PTA was predictive of long-term success (35).

While stent placement can resolve symptoms of CVS, restenosis within a previously deployed stent is a commonly observed phenomenon. Maya and colleagues (36) recently investigated the primary and secondary patency of stent placement in cases of symptomatic CVS. Using a prospective vascular access database, the authors retrospectively identified 23 pa-

Table 3. Some studies evaluating the role of stent placement in the treatment of central hemodialysis access lesions are presented

Authors (Reference)	Study Design	Year of Publication	Number of Central Lesions	Primary Patency	Secondary Patency	Notes
Bakken AM (41)	Retrospective	2007	75	30-d rates of 76% for both groups and 12-mo rates of 29% for PTA and 21% for stent ($P = 0.48$)	Secondary patency was also equivalent ($P = 0.08$), with a 30-d patency rate of 81% and 12-mo rate of 73% for the PTA group, <i>versus</i> stent secondary patency rates of 84% at 30 d, and 46% at 12 mo	
Rajan, DK (40)	Observational (no control group)	2007	89	In the fistula group were 88.5% \pm 4.8, 59.4% \pm 7.6, and 46% \pm 7.9 at 3, 6, and 9 mo, respectively. In the graft group, the rates were 78.1% \pm 7.3, 40.7% \pm 9, and 16% \pm 7.3, respectively.	n/a	
Maya, ID (38)	Observational (no control group)	2007	23	19% at 1 yr	64% at 1 yr	All stent had restenosis on follow-up venogram.
Haage, P (35)	Observational (no control group)	1999	50	3, 6, 12, and 24 mo were 92%, 84%, 56%, and 28	97% after 6 and 12 mo, 89% after 24 mo, and 81% after 36 and 48 mo	
Vesely, TM (46)	Observational (no control group)	1997	20	1 mo, 3 mo, 6 mo, and 1 yr: 90%, 67%, 42%, and 25%	at 3 mo, 6 mo, 1 yr, and 2 yr: 89%, 64%, 56%, and 22%	

tients who underwent stent placement due to residual stenosis following angioplasty. The median primary central vein patency was 138 d, with a 19% patency at 1 yr. Recurrence of ipsilateral edema was due to in-stent restenosis in 100% of the cases. The median secondary central vein patency was 1036 d, with a 64% patency at 1 yr. The authors concluded that stent deployment provides short-term relief of ipsilateral upper extremity edema due to CVS, but that long-term symptomatic relief can only be achieved with multiple subsequent interventions (36).

While Maya and Sprouse (35,36) investigated the role of stent placement in symptomatic central stenosis, the contemporary work of Levit *et al.* (37) speaks to the issue of asymptomatic central lesions. In this study, 86 patients with asymptomatic CVS were identified upon referral for venogram. The authors excluded patients with arm swelling, multiple CVS, indwelling catheters, and already indwelling stents at the first encounter. The mean degree of CVS before intervention was 71% (range, 50%–100%). No cases of untreated CVS progressed to symptoms. Meanwhile, mean progression was 0.21 percentage point per day in those patients whose asymptomatic CVS was treated with PTA ($P = 0.03$). Indeed, 80% of the interventions were followed by CVS escalation. The authors concluded that PTA of asymptomatic CVS greater than 50% in the setting of hemodialysis access maintenance procedures is associated with more rapid stenosis progression and escalation of lesions, compared with a nontreatment approach. These results, although very provocative, do not speak to the issue of stent placement *per se*; it is conceivable that stent placement in the intervention arm of the study would have demonstrated a better outcome than with angioplasty alone (37). Additionally, the small sample size and retrospective design of the study do not allow us to draw definitive conclusions.

Recently, investigators have endeavored to determine the difference in access patency for CVS between patients with AVF and those with AVG. Thirty-eight patients underwent 89 interventions (83 angioplasty procedures and six stent insertions). Technical and clinical success of the interventions was somewhat low at 93.3% and 94.4%. The primary patency rates at 3, 6, and 9 mo in the AVF group were 88.5%, 59.4%, and 46%. In the AVG group, the rates were 78.1%, 40.7%, and 16%. With multivariate analysis, intervention patency remained significantly longer for fistulas ($P = 0.014$) and in patients who did not have a previous catheter ($P = 0.001$). Unfortunately, stent and angioplasty were not directly compared in this study (38).

Similar to the studies already mentioned, several other investigations have been published, which suffer from a number of limitations (39–45). These include a small sample size, observational rather than controlled methodology, and a lack of uniform indication for stent placement. In many ways, the published data for central lesions are more problematic than for peripheral lesions. It is somewhat surprising, therefore, that the use of stents in the treatment of central stenosis is considered to be less controversial than their use in the peripheral vessels of hemodialysis patients. A closer look at the published literature argues persuasively that stent placement should be examined

further before it is embraced for central, while rejecting it for peripheral, lesions.

It is worth mentioning that perhaps the reason that the use of stents in the treatment of central stenosis is considered to be less controversial than in peripheral stenosis owes to the fact that surgery is simply not a good option for central lesions. Surgical management of central venous stenoses is difficult, expensive, and can be associated with significant morbidity. This is why percutaneous methods (PTA, stents) have supplanted surgery for management of central venous stenoses. Furthermore, Davidon *et al.* have suggested that the central vasculature may be more susceptible to elastic recoil than the peripheral vasculature (46). Despite these observations, no conclusive patency benefit for stent insertion has been found compared with angioplasty alone.

Advances in Stent Technology

Like many innovations in the field of percutaneous intervention, the first study on an endovascular stent was reported by Charles Dotter in 1969 (47). Due to the technological limitations of Dr. Dotter's time, further developments did not take place until the early 1980s, when Maas *et al.* (48–50) started experimenting with a self-expanding "double helix spiral prosthesis." Using heat-treated metal bands of inert steel in the form of a double helix spiral, an expandable prosthesis of variable diameters up to 35 mm was constructed. In animal experiments, the double helix spiral stents were completely endothelialized within 6 wk, and intimal reaction was largely insignificant. These early stents were introduced clinically for the first time in 1982 in two patients with aortic aneurysms, but applications in the venous system were soon to follow (51). Some of the commonly used stents are presented in Table 4.

Endovascular stents used for arteriovenous dialysis access fall into four major categories (54). These include balloon expandable, self-expanding, covered, and drug-eluting stents. Balloon expandable stents are mounted on a balloon and are deployed using balloon inflation. These stents can be crushed. Since many stents are placed in peripheral veins, these stents may not be suitable for this situation. However, they are particularly useful for highly elastic central venous stenosis where precise location is desired. Self-expanding stents come preloaded on a sheath and expand without a balloon. They can be made up of stainless steel or nitinol. Compared with stainless steel, nitinol stents do not shorten during placement. Nitinol is a nickel-titanium alloy with unique thermal recovery (commonly known as "smart metal") properties (53,54). If nitinol wire is initially formed into a desired shape and heated to 500 degrees Celsius, it will "memorize" that shape. When cooled, the wire will become soft again and can be deformed without changing the "memorized" shape. If the straightened wire is then warmed to its transition temperature (usually body temperature for most alloys of nickel-titanium), it resumes its initially formed shape (53,54). This concept, "shape memory," is of particular importance in vascular access stenosis, since many of the lesions that need to be stented occur at the elbow or at tortuous intersections of veins.

Endovascular stents can also be covered with PTFE or Da-

Table 4. Some endovascular stents in the treatment of vascular access stenosis

Device	Material	Deployment	Diameter	Recommended SheathSize
Wallstent (Boston Scientific; Natick, MA)	Stainless steel (bare stent)	Self-expanding	6-16 mm	7-9 French
Zilver stent (Cook; Bloomington, IN)	Nitinol (bare stent)	Self-expanding	4-14 mm	5-6 French
E-Luminexx Stent (Bard Peripheral; Covington, GA)	Nitinol (bare stent)	Self-expanding	4-14 mm	6 French
S.M.A.R.T. Control Stent; (Cordis, Miami Lakes, FL)	Nitinol (bare stent)	Self-expanding	5-14 mm	6-7 French
Fluency (Bard Peripheral; Tempe, AZ)	Nitinol Covered with PTFE material	Self-expanding	6-10 mm	8-9 French
Wallgraft (Boston Scientific; Natick, MA)	Stainless steel Covered with Dacron material	Self-expanding	6-14 mm	10-12 French
Viabahn (W L Gore; Flagstaff, AZ)	Nitinol Covered with PTFE material	Self-expanding	5-13 mm	7-12 French
Sentinol (Boston Scientific; Natick, MA)	Nitinol (bare stent)	Self-expanding	5-10 mm	6 French
Protege (EV3; Plymouth, MN)	Nitinol (bare stent)	Self-expanding	6-14 mm	6 French
Paramount (EV3; Plymouth, MN)	Stainless steel (bare stent)	Balloon expandable	5-8 mm	6-7 French
Express (Boston Scientific; Natick, MA)	Stainless steel (bare stent)	Balloon expandable	6-10 mm	6-7 French
Valeo (Bard Peripheral; Tempe, AZ)	Stainless steel (bare stent)	Balloon expandable	6-10 mm	6-8 French
Palmaz Genesis (Cordis, Miami Lakes, FL)	Stainless less	Balloon expanding	~3-25 mm	4->12 French

cron (stent grafts or covered stents) and can be used in a variety of situations discussed below. Drug-eluting stents provide one possible means for delivering pharmacologic interventions to the site of stenosis. Indeed, an animal study indicated that sirolimus-eluting stents may provide short-term effectiveness in porcine arteriovenous grafts (55).

Currently, clinicians have a great deal of variety to choose from when it comes to stent types, although most of the current designs are largely based on the initial concepts described above. The characteristics of various stent designs include the stent length, the stent diameter, the material composition of the wire mesh, the delivery system, and a host of more technical data. These features of the stent are critical to proper delivery and function, and are summarized in Table 4. Most of the current stents used for the treatment of vascular access stenosis are bendable (they can be placed at the elbow joint), noncrushable (they will not permanently collapse under direct pressure) (56–58), are covered and bare-metal, and can be cannulated for dialysis purposes (59).

Stents Grafts and Pseudoaneurysms

The treatment options for vascular access pseudoaneurysms have traditionally consisted of surgical revision or

ligation of the access. The stents grafts (covered stents) have a particularly useful role in the treatment of pseudoaneurysms. At present, three stents grafts are available. These include Wallgraft (consists of Dacron covering a flexible braided Elgiloy stent with platinum tracer wires on the inside; Boston Scientific, Natick, MA), Viabahn (constructed with internal PTFE material supported by an external metal stent; W.L. Gore, Flagstaff, AZ), and Fluency (consists of internal PTFE material supported by an external nitinol stent; Bard Peripheral, Phoenix, AZ). All are self-expanding stents. Recently, investigators have reported on the role of these stents in the percutaneous treatment of pseudoaneurysms (60,61). The first report described two patients who presented with an expanding mass over their AVG (60). The pseudoaneurysms were repaired in both cases by transluminally introducing a balloon-expandable stainless steel stent covered with PTFE material. The authors reported that after the procedure, both AVGs were patent at 5 and 6 mo, respectively. In the same year, Hausegger *et al.* (61) reported three cases in which pseudoaneurysms were walled off by percutaneous insertion of a stainless steel, PTFE covered stent. The authors reported a patency rate of the access as 8

to 9 mo, but, interestingly, in two of the cases the stent was punctured repeatedly during follow-up and the aneurysms recurred (61).

A more systematic evaluation of this percutaneous solution quickly followed. Najibi *et al.* (62) reported a series of ten patients with AVG or AVF pseudoaneurysms treated with covered stent placement to exclude the lesion. On initial follow-up, all patients had lost the palpable pseudoaneurysm pulsation. Moreover, the access remained patent in 9/10 patients. At six months, 7/10 patients had patent access and no further issues with pseudoaneurysms (62). More recently, 11 patients had undergone endoluminal insertion of a covered stent to repair (63). All 11 procedures were technically successful. The primary access patency rate reported in this study was 71% at 3 mo and 20% at 6 mo. While these studies demonstrated the exclusion of pseudoaneurysm, problems such as recurrence of the pseudoaneurysm and stent graft damage due to repeated cannulation continue to surround this approach.

Stent graft cannulation is a controversial area that deserves to be mentioned. To date, no study has conclusively established the safety of repeated cannulation of a stent graft. Some of the reports that have evaluated the role of stent grafts in the management of pseudoaneurysms have commented on the stent cannulation (61–63). These analyses, however, were limited by retrospective study design and a very small sample size (three to 11 patients). While cannulation of the stent graft was clearly possible, these studies have documented that repeated cannulation through the stent could cause damage to these devices (61–63). Indeed, stent damage by repeated cannulation has been documented by many investigators (61–63). It is for this reason that Vesely has clearly pointed out the inability of the current stent grafts to withstand repeated needle puncture and called for a new stent graft design for cannulation application specifically (64). The broken stent struts observed by Vesely (63) can potentially protrude through the skin and pose a threat of injury to the staff placing the patient on dialysis (Figure 3). Additionally, such a scenario also exposes the device to the development of infection. A recent report highlighted two cases where cannulation was performed through the stent. Both developed infection and required surgical removal of the access to combat infection (65). Indeed, the safety of cannulation through covered stent used to treat pseudoaneurysm has not been conclusively established in a prospective fashion.



Figure 3. Stent damage due to repeated cannulation for dialysis. From reference # 65 with permission.

Dialysis staff responsible for cannulating the access through the stent might require a specific order by the nephrologist. In this context, it is prudent for the interventionalist to communicate with the renal physician regarding the stented area and cannulation guidance. Dialysis staff should then be made aware of the stent and given specific instructions regarding cannulation to minimize infection and avoid injury. As an aside, patient education regarding the position of the stent might be important for the following reason. It is conceivable that for an access procedure, the patient might end up in a center that did not perform the original stent. In this context, the new interventionalist might find himself/herself cannulating the stented area and encountering problems. Patient education regarding vascular access is then critical. The above-cited issues gain more importance as these devices are not approved for this purpose. It is important to note that the use of covered stents in the treatment of pseudoaneurysm presents an “off label” use of these devices. While critically important, medico-legal ramifications of cannulation through a stent are unknown.

Stents and Vascular Access Emergencies

The ability of a stent to provide rescue therapy in the events of angioplasty-induced vessel rupture has been recognized for a number of years outside the field of vascular access intervention (66,67). This percutaneous rescue procedure is performed by keeping the guide wire across the intended lesion after the initial angioplasty is performed. If, on the postintervention angiogram, extravasation of contrast is detected, then the operator can elect to exclude the rupture by placement of a covered stent that opposes the walls of the vessel at the site of rupture. Alternatives to this form of therapy include surgical revision or ligation of the access.

The application of this technique to vascular access intervention was first rigorously described in 1997 (68). Funaki *et al.* (68) reported on 23 patients who were treated with covered stent placement after venous rupture attributed to balloon angioplasty during thrombectomy procedures. Twenty-one ruptures occurred in peripheral veins and two occurred in central veins. Stent placement allowed completion of the thrombectomy in all patients. Complications were limited to hematomas in four patients. The primary patency rate of the access was 52%, 26%, and 11% at 60, 180, and 360 d, respectively. The secondary patency rate was 74%, 65%, and 56% at 60, 180, and 360 d, respectively. A pseudoaneurysm developed 6 mo after stent placement in one patient.

The following year, Raynaud *et al.* (69) reported a larger series with similar results. Over a five-year period, the authors performed over 2000 angioplasty procedures. Vascular rupture occurred in 40 (1.7%) cases. Covered stents were deployed in 37 of these ruptures. Importantly, this was the first study to describe the technique in AVF rather than in AVG only. Stent placement stopped the bleeding immediately in 28 cases and after prolonged inflation within the stent in four cases. A second stent had to be deployed within the lumen of the first in one case of refractory bleeding. One hematoma was drained surgically and one access occluded on the second day post-stent

placement. The primary patency of the accesses at 1 yr was 48%. The 1-yr secondary patency was 86%.

More recently, an interesting case was reported in which an endovascular stent was used to repair an iatrogenic superior vena caval injury, which occurred in the setting of a catheter placement (70). The perforation in the vena cava occurred at the confluence of the innominate veins when left subclavian catheter was being inserted. The covered stent was delivered through a femoral approach while the catheter was simultaneously removed to attenuate hemorrhage. This case report represents a novel, percutaneous approach to a problem that in the past would have required emergent surgery.

The placement of an intravascular stent can effectively treat angioplasty-induced vascular rupture. Complete vascular rupture is one situation where stent placement is warranted beyond any doubt.

Complications of Stent Placement

Some of the complications associated with stent placement include shortening, migration, and fracture. Infectious complications are usually not evident until many days after the procedure.

Verstandig *et al.* (71) recently reported shortening and migration of covered stents after treatment of CVS in hemodialysis patients. In 70 percent of the cases there was significant stent shortening. All these cases required additional stents to be deployed to cover the target lesion. An additional two patients in this series experienced stent migration. Shortening tends to occur because, as a stainless steel stent is radially compressed, it becomes elongated (72). Thus, when deployed, it becomes relatively foreshortened. The normal expansion and contraction of the central veins during respiration, which when combined with the geometry of the stent, can lead to a sequence of shortening-lengthening-shortening of the stent. This sequence can lead to stent movement and migration.

Tsuji *et al.* (73) described stent fracture in the left brachiocephalic vein (73). The authors described a hemodialysis patient with severe left arm edema on the side of his AVF. A brachiocephalic vein stenosis was initially treated with a self-expanding stent. Eight months after this initial procedure, a stent fracture was discovered. A second stent was deployed in the lumen of the previously placed fractured stent. This technique proved efficacious over the next 9 mo, during which time the access remained patent. Similarly, a recent case report described fracture of two overlapping stents (9×80 -mm and 9×60 -mm) (74). After 6 mo, a fistulogram revealed stent fracture. Maleux *et al.* (75) also reported a case of collapsed stent in the cephalic vein that led to thrombosis of a vascular access approximately one month after initial deployment (75).

Shortly after placement of an uncovered stent, the metallic struts are covered by endothelium. The stent can become infected, however, before full endothelialization (76). Alternatively, if a covered stent is placed, endothelialization is delayed, and infection is a risk for a longer duration of time. One report describes a fatal outcome after a stent became infected (77). Another report described a similar infectious event that was treated conservatively (78). In the latter case, a *Staph aureus*

infection was treated by local delivery of antibiotic into the infected stent. Nevertheless, most cases of stent infection require surgical removal of the stent. Another recent report describes the development of fever and positive blood cultures three weeks after stent placement (79). A tagged white blood cell scan localized the infection to the stent. Due to the investigators' conviction that the patient would not tolerate surgery, six weeks of systemic antibiotics was successful in effecting complete clinical resolution of the infection. Although this last report offers a more optimistic perspective, stent infection, however rare, is a life-threatening complication that requires aggressive intervention.

Infection related to a covered stent inserted in an arteriovenous access has also been reported recently (65). Two diabetic patients with covered stent infection were described in this analysis. One patient was seen for left upper arm brachiocephalic graft dysfunction. An 8×40 mm stent graft was placed with excellent results. Two months later, the patient presented with signs of cellulitis at the area overlying the stent with strut wire palpable just under the skin. The staff had been cannulating through the stent. Antibiotic therapy was unsuccessful. Surgical intervention was performed to remove the stent and the arteriovenous graft. Another patient was seen for a dysfunctional right upper arm brachiocephalic fistula. An 8×60 mm stent graft was inserted with excellent results. The stented area was used for cannulation. The patient was admitted 5 mo later with sepsis and signs of cellulitis of the skin overlying the cannulated area of the stent. The blood cultures revealed *staphylococcus aureus*. Stent was surgically removed with loss of the access. The above-cited reports indicate that the stents can get infected particularly when they are used for cannulation. While stents are being used frequently to treat stenoses, cannulation through these devices can result infection and devastating consequences.

While the primary focus of the NKF/KDOQI guidelines as well as the National Vascular Access Improvement Initiative have been on fistula placement in incident hemodialysis patients (80,81), the creation of secondary AVFs has recently come to be viewed as an important strategy to maximize the use of fistulas in prevalent hemodialysis patients (7,82). A functional vascular access in the lower arm commonly results in dilation of the veins in the upper arm. These dilated veins can then be used to create an AVF when the primary access starts to malfunction. What is more, the ability of these already mature veins to accept immediate cannulation obviates the need for the catheter bridge in many cases. If, on the other hand, there is a stent in the outflow vein that prevents the relatively easy creation of a secondary AVF, the matter becomes much more complex.

The validity of a strategy to create secondary AVFs in patients with malfunctioning vascular accesses has been successfully demonstrated in a recent study (83). In this analysis, nine patients undergoing percutaneous interventions were evaluated for secondary AVF creation. All were found to have suitable vascular anatomy and had the AVF created. The secondary fistula was successful in all nine patients with a mean follow-up of 4.8 ± 1.4 mo in post-AVG cases and 5.6 ± 1.7 mo in the

post-AVF patients. Perhaps as important, it was possible to continue dialysis without the catheter bridge in 3/9 patients. Again, if there is a stent taking up “vascular real estate” in the upper arm, the methodology described above becomes extremely difficult. Indeed, a recent report described a scenario where multiple stents placed in the outflow tract of an access completely precluded subsequent creation of a secondary AVF (6). It is, therefore, prudent to consider the creation of secondary fistula before the insertion of an intravascular stent where a secondary fistula is a real possibility.

Summary

Despite the recent advances in knowledge, both technical and theoretical, the role of stent placement in the management of hemodialysis access dysfunction remains controversial. It will remain so until large, multi-center, prospective, randomized, controlled trials are conducted. Until studies are published that correct for the type of access (e.g., AVG or AVF), type of lesion (e.g., inflow, outflow, or central), patient characteristics (e.g., diabetic or not), and previous history of intervention, and take quality of delivered hemodialysis into account among a host of other variables that are believed to affect access outcomes, the hemodialysis access stent debate will be heard. The existing vascular access literature has attempted to address the question “to stent or not to stent.” The authors would suggest that the critical question should instead evolve to “under what circumstances and in what patients are stents useful?” It is further suggested that the historical lessons from the evolution of the field of cardiology be followed to establish a national registry to help guide investigation of such questions.

Acknowledgments

This project was not funded by any grants or funding agencies.

Disclosures

None.

References

1. Malvin RE: How a dentist's name became a synonym for a life-saving device: The story of Dr. Charles Stent. *Journal of the History of Dentistry* 49: 77–80, 2001
2. Sigwart U, Puel J, Mirkovitch V, Joffe F, Kappenberg L: Intravascular stents to prevent occlusion and restenosis after transluminal angioplasty. *N Engl J Med* 316: 701–706, 1987
3. Serruys PW, Kutryk MJB, Ong ATL: Coronary-artery stents. *N Engl J Med* 354: 483–495, 2006
4. Arjomand H, Turi Z, McCormick D: Percutaneous coronary intervention: Historical perspectives, current status, and future direction. *Am Heart J* 146: 787–796, 2003
5. Gruentzig AR, Senning A, Siegenthaler WE: Non-operative dilatation of coronary artery stenoses. Percutaneous transluminal coronary angioplasty. *N Engl J Med* 301: 61–68, 1979
6. Rasmussen RL, Feldman D, Beathard G, Rubin JE: Indications for stent placement in a dialysis access. *Semin Dial* 21: 83–84, 2008
7. Asif A, Leon C, Merrill D, Ellis R, Bhimani B, Pennell P: Optimal timing for secondary arteriovenous fistula creation: Devastating effects of delaying conversion. *Semin Dial* 19: 425–428, 2006
8. U.S. Renal Data System, USRDS 2006 Annual Data Report: Atlas of Chronic Kidney Disease and End-Stage Renal Disease in the United States, National Institutes of Health, National Institute of Diabetes and Digestive and Kidney Diseases, Bethesda MD, 2007
9. Zollikofer CL, Largiader I, Bruhlman W: Endovascular stenting of veins and grafts: Preliminary clinical experience. *Radiology* 167: 707–712, 1988
10. Antonucci F, Salomonowitz E, Stuckmann G, Stiefel M, Zollikofer CL: Placement of venous stents: Clinical experience with a self-expanding prosthesis. *Radiology* 183: 493–498, 1992
11. Quinn SF, Schuman ES, Demlow TA: Percutaneous transluminal angioplasty versus endovascular stent placement in the treatment of venous stenoses in patients undergoing hemodialysis: Intermediate results. *J Vasc Interv Radiol* 6: 851–855, 1995
12. Beathard GA: Gianturco self-expanding stent in the treatment of stenosis in dialysis access grafts. *Kidney Int* 43: 872–877, 1993
13. Hoffer EK, Sultan S, Herskowitz MM: Prospective randomized trial of a metallic intravascular stent in hemodialysis graft maintenance. *J Vasc Interv Radiol* 8: 965–973, 1997
14. Zaleski GX, Funaki B, Rosenblum J: Metallic stents deployed in synthetic arteriovenous hemodialysis grafts. *AJR* 176: 1515–1519, 2001
15. Oderich GS, Treiman GS, Schneider P, Bhirangi K: Stent placement for treatment of central and peripheral venous obstruction: A long-term multi-institutional experience. *J Vasc Surg* 32: 760–769, 2000
16. Hatzimpaloglou A, Velissaris I, Gourasas I, Grekas D, Kiskinis D, Kaitzis D, Louridas G: Stenting of central venous stenoses and occlusions to maintain hemodialysis vascular access. *J Vasc Access* 3: 10–13, 2002
17. Quinn SF, Kim J, Sheley RC: Transluminally placed endovascular grafts for venous lesions in patients on hemodialysis. *Cardiovascular and Interventional Radiology* 26: 4365–4369, 2003
18. Aytakin C, Boyvat F, Yağmurdur MC, Moray G, Haberal M: Endovascular stent placement in the treatment of upper extremity central venous obstruction in hemodialysis patients. *Eur J Radiol* 49: 81–85, 2004
19. Pan HB, Liang HL, Lin YH, Chung HM, Wu TH, Chen CY, Fang HC, Chen CK, Lai PH, Yang CF: Metallic stent placement for treating peripheral outflow lesions in native arteriovenous fistula hemodialysis patients after insufficient balloon dilatation. *AJR* 184: 403–409, 2005
20. Sreenarasimhaiah VP, Margassery SK, Martin KJ, Bander SJ: Salvage of thrombosed dialysis access grafts with venous anastomosis stents. *Kidney Int* 67: 678–684, 2005
21. Liang HL, Pan HB, Lin YH, Chen CY, Chung HM, Wu TH, Chou KJ, Lai PH, Yang CF: Metallic stent placement in hemodialysis graft patients after insufficient balloon dilatation. *Korean J Radiol* 7: 118–124, 2006
22. Naoum JJ, Irwin C, Hunter GC: The use of covered nitinol stents to salvage dialysis grafts after multiple failures. *Vasc Endovascular Surg* 40: 275–279, 2006
23. Lombardi JV, Dougherty MJ, Veitia N, Somal J, Calligaro KD: A comparison of patch angioplasty and stenting for

- axillary venous stenoses of thrombosed hemodialysis grafts. *Vasc Endovascular Surg* 36: 223–229, 2002
24. Vogel PM, Parise C: SMART stent for salvage of hemodialysis access grafts. *J Vasc Interv Radiol* 15: 1051–1060, 2004
 25. Vogel PM, Parise C: Comparison of SMART stent placement for arteriovenous graft salvage versus successful graft PTA. *J Vasc Interv* 16: 1619–1626, 2005
 26. Kolakowski S, Jr., Dougherty MJ, Calligaro KD: Salvaging prosthetic dialysis fistulas with stents: Forearm versus upper arm grafts. *J Vasc Surg* 38: 719–723, 2003
 27. Vesely T, Pilgram T, Amin MZ: Use of stents and stent grafts to salvage angioplasty failures in patients with hemodialysis. *Grafts Seminars in Dialysis* 21:100–104, 2008
 28. Chan MR, Bedi S, Sanchez RJ, Young HN, Becker YT, Kellerman PS, Yevzlin AS: Stent placement versus angioplasty improves patency of arteriovenous grafts and blood flow of arteriovenous fistulae. *Clin J Am Soc Nephrol* 3: 699–705, 2008
 29. Maya ID, Allon M: Outcomes of thrombosed arteriovenous grafts: Comparison of stents vs angioplasty. *Kidney Int* 69: 934–937, 2006
 30. Aruny JE: Quality improvement guidelines for percutaneous management of the thrombosed or dysfunctional dialysis access. *JVIR Volume* 14: S247–S253, 2003
 31. Vorwerk D, Guenther RW, Mann H: Venous stenosis and occlusion in hemodialysis shunts: Followup results of stent placement in 65 patients. *Radiology* 195: 140–146, 1995
 32. Beathard GA: Percutaneous transvenous angioplasty in the treatment of vascular access stenosis. *Kidney Int* Dec; 42: 1390–1397, 1992
 33. Gray RJ, Horton KM, Dolmatch BL: Use of Wallstents for hemodialysis access-related venous stenoses and occlusions untreatable with balloon angioplasty. *Radiology* 195: 479–484, 1995
 34. Haage P, Vorwerk D, Piroth W, Schuermann K, Guenther RW: Treatment of hemodialysis-related central venous stenosis or occlusion: Results of primary Wallstent placement and follow-up in 50 patients. *Radiology* 212: 175–180, 1999
 35. Sprouse LR 2nd, Lesar CJ, Meier GH 3rd, Parent FN, Demasi RJ, Gayle RG, Marcinyzck MJ, Glickman MH, Shah RM, McEnroe CS, Fogle MA, Stokes GK, Colonna JO: Percutaneous treatment of symptomatic central venous stenosis. *J Vasc Surg* 39: 578–582, 2004
 36. Maya ID, Saddekni S, Allon M: Treatment of refractory central vein stenosis in hemodialysis patients with stents. *Semin Dial* 20:78–82, 2007
 37. Levit RD, Cohen RM, Kwak A, Shlansky-Goldberg RD, Clark TW, Patel AA, Stavropoulos SW, Mondschein JL, Solomon JA, Tuite CM, Trerotola SO: Asymptomatic central venous stenosis in hemodialysis patients. *Radiology* 238: 1051–1056, 2006
 38. Rajan DK, Chennepragada SM, Lok CE, Beecroft JR, Tan KT, Hayeems E, Kachura JR, Sniderman KW, Simons ME: Patency of endovascular treatment for central venous stenosis: Is there a difference between dialysis fistulas and grafts? *J Vasc Interv Radiol* 18: 353–359, 2007
 39. Bakken AM, Protack CD, Saad WE, Lee DE, Waldman DL, Davies MG: Long-term outcomes of primary angioplasty and primary stenting of central venous stenosis in hemodialysis patients. *J Vasc Surg* 45: 776–783, 2007
 40. Chen CY, Liang HL, Pan HB, Chung HM, Chen WL, Fang HC, Lo A, Chen CK, Lai PH, Yang CF: Metallic stenting for treatment of central venous obstruction in hemodialysis patients. *J Chin Med Assoc* 66: 166–172, 2003
 41. Masková J, Komárková J, Kivánek J, Danes J, Slavíková M: Endovascular treatment of central vein stenoses and/or occlusions in hemodialysis patients. *Cardiovasc Intervent Radiol* 26: 27–30, 2003
 42. Smayra T, Otal P, Chabbert V, Chemla P, Romero M, Joffre F, Rousseau H: Long-term results of endovascular stent placement in the superior caval venous system. *Cardiovasc Intervent Radiol* 24: 388–394, 2001
 43. Lumsden AB, MacDonald MJ, Isiklar H, Martin LG, Kikeri D, Harker LA, Allen RC: Central venous stenosis in the hemodialysis patient: Incidence and efficacy of endovascular treatment. *Cardiovasc Surg* 5: 504–509, 1997
 44. Vesely TM, Hovsepian DM, Pilgram TK, Coyne DW, Shenoy S: Upper extremity central venous obstruction in hemodialysis patients: Treatment with Wallstents. *Radiology* 204: 343–348, 1997
 45. Mickley V, Görich J, Rilinger N, Storck M, Abendroth D: Stenting of central venous stenoses in hemodialysis patients: Long-term results. *Kidney Int* 51: 277–280, 1997
 46. Davidson CJ, Newman GE, Sheikh KH: Mechanism of angioplasty in hemodialysis fistula stenosis evaluated by intravascular ultrasound. *Kidney Int* 40: 91–95, 1991
 47. Dotter CT: Transluminally placed coilspring endarterial tube grafts: Long-term patency in canine popliteal artery. *Invest Radiol* 4: 327–332, 1969
 48. Maass D, Kropf L, Egloff L, Demierre D, Turma M, Senning A: Transluminal implantation of intravascular “double helix” spiral prostheses: Technical and biological considerations. *ESAO Proc* 9: 252–256, 1982
 49. Maass D, Demierre D, Deaton D, Largiad6r F, Senning A: Transluminal implantation of self-adjusting expandable prostheses: Principles, techniques, and results. *Prog Artif Org*: 979–987, 1983
 50. Maass D, Zollikofer CHL, Largiader F, Senning A: Radiological follow-up of transluminally inserted vascular endoprotheses: An experimental study using expanding spirals. *Radiology* 152: 659–663, 1984
 51. Zollikofer CL, Antonucci F, Stuckmann G, Mattias P, Salomonowitz EK: Historical overview on the development and characteristics of stents and future outlooks. *Cardiovasc Intervent Radiol* 15: 272–278, 1992
 52. Beathard GA. Central vein stenosis associated with dialysis access. Uptodate: http://www.utdol.com/online/content/topic.do?topicKey=dialysis/32202&selectedTitle=9~150&source=search_result. Accessed online 7–14-08
 53. Cragg A, Lurid G, Rysavy J, Castaneda F, Castaneda-Zuniga WR, Amplatz K: Non-surgical placement of arterial endoprotheses: A new technique using nitinol wire. *Radiology* 147: 261–263, 1983
 54. Clark TWJ: Nitinol stents in hemodialysis access. *J Vasc Interv Radiol* 15: 1037–1040, 2004
 55. Rotmans JI, Pattynama PM, Verhagen HJ: Sirolimus-eluting stents to abolish intimal hyperplasia and improve flow in porcine arteriovenous grafts: A 4-week follow-up study. *Circulation* 111: 1537, 2005
 56. Dyet JF, Watts WG, Ettles DF, Nicholson AA: Mechanical properties of metallic stents: How do these properties influence the choice of stent for specific lesions? *Cardiovasc Intervent Radiol* 23: 47–54, 2000
 57. Shabalovskaya SA: On the nature of the biocompatibility

- and on medical applications of NiTi shape memory and superelastic alloys. *Biomed Mater Eng* 6: 267–289, 1996
58. Duda SH, Wiskirchen J, Tepe G: Physical properties of endovascular stents: An experimental comparison. *J Vasc Interv Radiol* 11: 645–654, 2000
 59. Rhodes ES, Silas AM: Dialysis needle puncture of Wall-grafts placed in polytetrafluoroethylene hemodialysis grafts. *JVIR* 16: 1129–1134, 2005
 60. Rabindranauth P, Shindelman L: Transluminal stent-graft repair for pseudoaneurysm of PTFE hemodialysis grafts. *J Endovasc* 5: 138–141, 1998
 61. Hausegger KA, Tiessenhausen K, Klimpfinger M, Raith J, Hauser H, Tauss J: Aneurysms of hemodialysis access grafts: Treatment with covered stents: A report of three cases. *Cardiovasc Intervent Radiol* 21: 334–337, 1998
 62. Najibi S, Bush RL, Terramani TT, Chaikof EL, Gunnoud AB, Lumsden AB, Weiss VJ: Covered stent exclusion of dialysis access pseudoaneurysms. *J Surg Res* 106: 15–19, 2002
 63. Vesely TM: Use of stent grafts to repair hemodialysis graft-related pseudoaneurysms *J Vasc Interv Radiol* 16:1301–1307, 2005
 64. Vesely TM: Role of stents and stent grafts in management of hemodialysis access complications. *J Vasc Surg* 20: 3175–3183, 2007
 65. Gadalean F: Covered stent outcomes for arteriovenous hemodialysis access salvage. *J Am Soc Nephrol* 19: 899A, 2008
 66. Oderich GS, Panneton JM, Hofer J, Bower TC, Cherry KJ, Sullivan T, Noel AA, Kalra M, Gloviczki P: Iatrogenic operative injuries of abdominal and pelvic veins: A potentially lethal complication. *J Vasc Surg* 39: 931–936, 2004
 67. Asensio JA, Chahwan S, Hanpeter D, Demetriades D, Forno W, Gambaro E, Murray J, Velmahos G, Marengo J, Shoemaker WC, Berne TV: Operative management and outcome of 302 abdominal vascular injuries. *Am J Surg* 180: 528–533, 2000
 68. Funaki B, Szymiski GX, Leef JA, Rosenblum JD, Burke R, Hackworth CA: Wallstent deployment to salvage dialysis graft thrombolysis complicated by venous rupture: Early and intermediate results. *AJR* 169: 1435–1437, 1997
 69. Raynaud AC, Angel CY, Sapoval MR, Beyssen B, Pagny JY, Auguste MJ: Treatment of hemodialysis access rupture during PTA with Wallstent implantation. *Vasc Interv Radiol* 9: 437–442, 1998
 70. Azizzadeh A, Pham MT, Estrera AL, Coogan SM, Safi HJ: Endovascular repair of an iatrogenic superior vena caval injury: A case report. *J Vasc Surg* 46: 569–571, 2007
 71. Verstandig AG, Allan BI, Sasson T, Haviv YS, Rubinger D: Shortening and migration of Wallstents after stenting of central venous stenoses in hemodialysis patients. *Cardiovasc Intervent Radiol* 26: 58–64, 2003
 72. Gray RJ, Dolmatch BL, Horton KM, Romolo JL, Zarate AR: Migration of Palmaz stents following deployment for venous stenoses related to hemodialysis access. *J Vasc Interv Radiol* 5: 117–1120, 1994
 73. Tsuji T, Iijima R, Nakajima R, Yoshitama T, Hara H, Hara H, Tsunoda T, Nakamura M, Wada M, Yamamoto M, Shiba M: Stent fracture in the left brachiocephalic vein. *Cardiovasc Revasc MedPar* 8: 103–106, 2007
 74. Brewster UC, Mojibian HR, Aruny JE, Perazella MA: Access stenosis and stent fracture. *Am J Kidney Dis* 47; A45, e35–e36, 2006
 75. Maleux G, Rousseau H, Otal P, Joffre F: Collapsed Palmaz stent after deployment for hemodialysis access-related venous stenosis. *J Vasc Interv Radiol* 9: 169–171, 1998
 76. Thibodeaux LC, James KV, Lohr JM, Welling RE, Roberts WH: Infection of endovascular stents in a swine model. *Am J Surg* 172: 151–154, 1996
 77. Bruneau L, Gaboury L: Infection with fatal outcome after endovascular metallic stent placement. *Radiology* 192: 363–365, 1994
 78. Naddour F, Yount RD, Quintal RE: Successful conservative treatment of an infected central venous stent. *Catheterization and Cardiovascular Interventions* 51: 196–198, 2000
 79. Guest SS, Kirsch CM, Baxter R, Sorooshian M, Young J: Infection of a subclavian venous stent in a hemodialysis patient. *Am J Kidney Dis* 26: 377–380, 1995
 80. National Kidney Foundation. K/DOQI clinical practice guidelines in vascular access: 2006 update. *Am J Kidney Dis* 48;S1: S176–S306, 2006
 81. Beasley C, Rowland J, Spergel L: Fistula first: An update for renal providers. *Nephrol News Issues* 18: 88–90, 2004
 82. Beathard GA: Interventionalist's role in identifying candidates for secondary fistulas. *Semin Dial* 17: 233–236, 2004
 83. Asif A, Unger SW, Briones P, Merrill D, Cherla G, Lenz O, Roth D, Pennell P: Creation of secondary arteriovenous fistulas: Maximizing fistulas in prevalent hemodialysis patients. *Semin Dial* 18: 420–424, 2005