

# Nephrogenic Systemic Fibrosis: A Mysterious Disease in Patients with Renal Failure—Role of Gadolinium-Based Contrast Media in Causation and the Beneficial Effect of Intravenous Sodium Thiosulfate

Preethi Yerram, Georges Saab, Poorna R. Karuparthi, Melvin R. Hayden, and Ramesh Khanna

*Department of Internal Medicine, School of Medicine, University of Missouri–Columbia, Columbia, Missouri*

Nephrogenic fibrosing dermopathy/nephrogenic systemic fibrosis (NSF) is an emerging scleromyxedema-like cutaneous disorder of unknown cause that is seen in patients with renal failure, and the number of reported cases has grown significantly since its first recognition. Recent case reports associated the use of gadolinium ( $Gd^{3+}$ )-based contrast agents with the development of NSF. Herein is reported an additional patient who had NSF and had multiple previous exposures to  $Gd^{3+}$ -based magnetic resonance imaging studies and had marked improvement in pain and skin changes after a trial of intravenous sodium thiosulfate. Discussed are the possible association of  $Gd^{3+}$ -based contrast media with the development of NSF and potential for the use of sodium thiosulfate in the treatment of NSF.

*Clin J Am Soc Nephrol* 2: 258–263, 2007. doi: 10.2215/CJN.03250906

**N**ephrogenic fibrosing dermopathy (NFD) is an emerging scleromyxedema-like disease that is seen in patients with renal failure (1). This condition is characterized by thickening, induration, and hardening of the skin and requires skin biopsy for confirmation. Furthermore, this condition extends beyond the dermis, involving multiple organs and tissues, prompting it to be renamed nephrogenic systemic fibrosis (NSF) (2,3). The exact cause/trigger and treatment for this condition are still obscure. Recently, an association with exposure to gadodiamide (gadolinium [ $Gd^{3+}$ ]-diethylenetriaminepentaacetic acid) and the development of NSF has been described (4,5) and has prompted the US Food and Drug Administration (FDA) to issue a public health advisory regarding the use of  $Gd^{3+}$ -containing magnetic resonance imaging (MRI) contrast agents in patients with advanced renal failure (6). Recent findings of  $Gd^{3+}$  in the skin of patients with NSF has further supported this association (7,8). Here, we report an additional patient who has NSF that had previous multiple exposures to gadodiamide and had rapid improvement of this condition with the use of intravenous sodium thiosulfate (STS), an agent that has recently gained favor in the treatment of calciphylaxis.

## Materials and Methods

### Patient

A 26-yr-old white woman who had end-stage renal disease (secondary to Henoch-Schönlein purpura) and was on hemo-

dialysis (Table 1) presented with a history of severe pain (sharp, aching, throbbing) in her lower extremities for approximately 1 year with tightness, itching, joint stiffness, skin discoloration, and tenderness that began in January to February 2004. On examination, the patient was found to have yellowish scleral plaques bilaterally and lower extremities with hairless, shiny skin with bluish-brown discoloration and woody induration (Figure 1). Clubbing in both lower and upper extremities and sclerodactyly of the upper extremities (Figure 2) were also noted. These findings were reported to be insidious in onset by the patient.

During the course of the next several months, further diagnostic work-up was done (Tables 1 and 2). The patient was treated with large dosages of narcotics and gabapentin with minimal improvement of pain.

The patient was noted to have diffuse large arterial calcification on x-rays, and in view of this and the unresolved pain, a trial of intravenous STS was started (12.5 g three times a week at the end of hemodialysis) in May 2006. The patient tolerated the treatment well, with significant improvement in skin discoloration, pain, and joint stiffness within one month. The improvement in pain was remarkable to the extent that the patient's narcotic analgesic requirements became minimal and the skin discoloration was notably better. A skin biopsy was later obtained in July 2006, which confirmed the diagnosis of NSF (Figure 3). No histologic evidence of calciphylaxis was noted on the biopsy.

The patient's STS therapy was subsequently stopped in late August 2006 in view of her prolonged and complicated hospitalization for septic shock secondary to hemodialysis catheter-related infection. STS therapy has been reinstated now, and a repeat biopsy is being considered.

Received September 27, 2006. Accepted January 3, 2007.

Published online ahead of print. Publication date available at [www.cjasn.org](http://www.cjasn.org).

**Address correspondence to:** Dr. Preethi Yerram, Department of Internal Medicine, MA406, School of Medicine, University of Missouri–Columbia, Columbia, MO 65212. Phone: 573-234-4137; Fax: 573-884-4820; E-mail: [yerramp@health.missouri.edu](mailto:yerramp@health.missouri.edu)

Table 1. Medical history, medications, and pertinent laboratory tests<sup>a</sup>

Laboratory Tests	History	Medications (1/06)
Lupus anticoagulant, negative	Henoch-Schönlein purpura leading to ESRD	Aspirin 81 mg/d
Protein c and s, normal	Failed cadaveric renal transplant	Colace 100 mg orally twice a day
Anticardiolipin Ab (IgG and IgM), negative	Secondary hyperparathyroidism and renal osteodystrophy with numerous related fractures	Nephrocaps 1 tab daily
Anti-ENA Ab, negative	Extensive posterior cervical spinal fusion involving T8 to L4, with prosthesis	Cinacalcet 60 mg/d orally
Anti-SM Ab, negative	Heparin antibodies	Flexeril 10 mg orally twice a day
Anti-PM-1 Ab, negative	Peritoneal dialysis initially for 4.5 yr	Ranitidine 150 mg orally twice a day
Anti-SSA/RO Ab, Anti-SSB/La Ab, negative	Hemodialysis (since 1994)	Gabapentin 100 mg orally every 8 h
Anti-SCL 70 Ab, negative	Multiple procedures for hemodialysis access placement since 1994 (thrombectomy in December 2003, approximately 1 mo before development of symptoms)	Benadryl 25 mg orally every night as needed
Anti-Ds DNA Ab, negative	Occlusion of vascular access multiple times	Renagel 4 caps three times a day with meals
ESR (6/03), 33 mm/h	Subclavian deep vein thrombosis	Plavix 75 mg/d
ESR (6/04) 10 mm/h		Ativan in the evening as needed
CRP (6/03), 1.7 mg/dl (0 to 0.9)		Zoloft 25 mg orally every night
Iron (2/03), 42 μg/dl (37 to 170)		Fentanyl patch 75 mg every 3 d
TIBC (2/03), 149 μg/dl (250 to 450)		MSIR 30 mg orally every 4 h as needed for pain
Ferritin (2/03), 891 ng/ml (12 to 114)		Epogen 300 to 600 U/kg per wk
Vitamin B <sub>12</sub> (2/03), 757 pg/ml		Venofer 100 mg/wk intravenously
Intact PTH (7/06), 258 pg/ml (10 to 69)		No history of use of angiotensin-converting enzyme inhibitors

<sup>a</sup>Ab, antibody; CRP, C-reactive protein; DS, double-stranded; ENA, extractable nuclear antigen; ESR, erythrocyte sedimentation rate; PTH, parathyroid hormone; SM, Smith; TIBC, total iron-binding capacity.

Retrospective review of the patient's medical record revealed exposure to multiple Gd<sup>3+</sup>-based MRI and an MR venogram in 2003, which could be temporally related to the development of skin changes (Table 3). The patient was also noted to have multiple vascular access surgeries. In relation to the development of her symptoms, the patient had an arteriovenous graft placed in the right groin in March 2003, for which she underwent thrombectomy in December 2003 (approximately 1 mo before her symptoms developed). Subsequently, this access failed and the patient had several tunneled and nontunneled dialysis catheters placed at multiple sites, all after her symptoms developed. Her current hemodialysis access is a tunneled femoral catheter. Hemodialysis was complicated by chronic hypotension; therefore, antihypertensive agents, including angiotensin-converting enzyme inhibitors, were not administered.

## Discussion

### Role of Gadodiamide in the Development of NSF

Gadodiamide (Omniscan; Amersham Health, Amersham, UK) is a nonradioactive contrast agent that is approved by the FDA for use in MRI. Since its introduction, gadodiamide has become accepted as a safe alternative to iodine-based contrast agents in patients with impaired kidney function (9,10) and is usually well tolerated except for a few minor adverse effects.

However, recent case reports have suggested an association between the use of gadodiamide and the development of NSF in patients with impaired kidney function. In a recent case series by Marckmann *et al.* (5), the delay from exposure to first sign of the disease was 2 to 75 days.

The normal elimination half-life of gadodiamide in healthy individuals is approximately 1.5 h and can be prolonged up to 10 to 60 h in patients with ESRD, especially when dialysis is delayed. The clearance of gadodiamide with peritoneal dialysis (69% after 22 days of continuous dialysis) is prolonged compared with its clearance in a single session of hemodialysis (65%) (11).

The stability of Gd<sup>3+</sup> depends on its being bound to a ligand (*e.g.*, diethylenetriaminepentaacetic acid). The adverse effect profile of gadodiamide is likely due to the *in vivo* dissociation of Gd-ligand complex into Gd<sup>3+</sup> ion and ligand (12). This process is accelerated in patients with renal failure because of a combination of metabolic acidosis and inadequate clearance of the Gd-ligand complex. Endogenous metals such as Zn<sup>2+</sup>, Cu<sup>2+</sup>, Ca<sup>2+</sup>, and Fe<sup>3+</sup> also destabilize the complex by transmetalation (a process of displacing Gd<sup>3+</sup> from its ligand by competitive binding), leading to its dissociation (12). Grobner (4), in a recent case report, suggested that acidosis might be an essential co-factor in the pathogenesis of NSF, but this was not the case

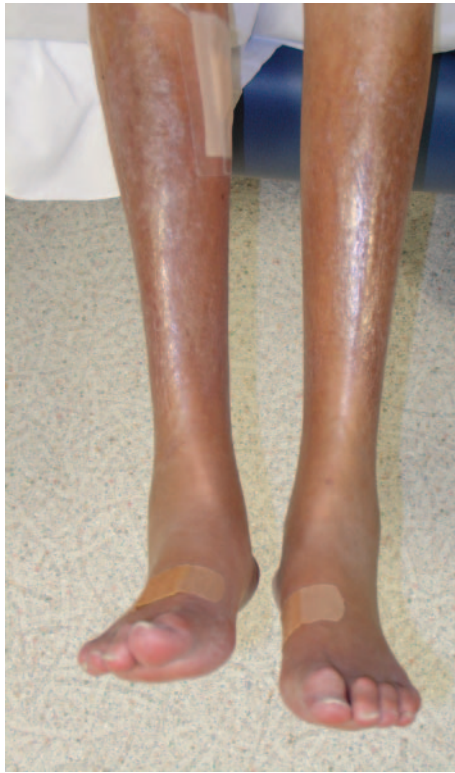

Figure 1. Shiny, discolored, woody skin (on inspection and palpation) seen in the patient with nephrogenic systemic fibrosis (NSF). This picture was taken approximately 1 to 1.5 mo after the initiation of sodium thiosulfate (STS) therapy.

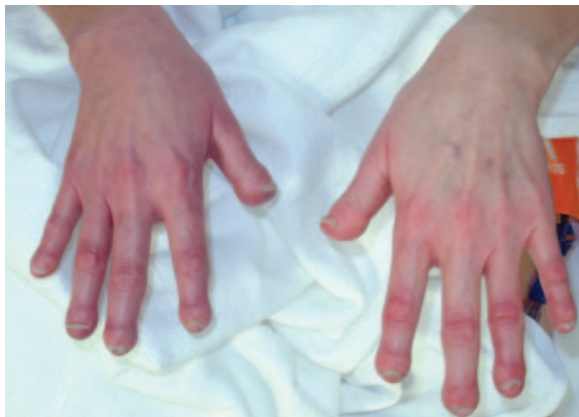

Figure 2. Sclerodactyly and severe clubbing seen in the patient with NSF.

in the study by Marckmann *et al.* (5), as well as with our patient (Table 2).

The dissociated  $Gd^{3+}$  ion has poor solubility and could form *in vivo* precipitates of salts by chelating with anions such as phosphate (which is elevated in patients with renal failure), carbonate, and hydroxyl, with eventual deposition in various tissues, such as liver, bone, skin, muscle, and the interstitium (12). Two different sequences of pathophysiologic events, as a reaction to noxious agents (*e.g.*, tissue deposits of Gd), have

Table 2. Pertinent laboratory findings at the time of MRI exams<sup>a</sup>

Date of MRI	Bicarbonate Level (mEq/L)	Phosphorus Level (g/dl)	Calcium Level (mg/dl)
01/30/03	29	5.2	9.6
06/07/03	27	7.6	10.2
07/15/03	32	6.4	9.9
08/01/03	29	Not done	9.8
11/24/03	27	Not done	9.9

<sup>a</sup>From January to February 2004, the average bicarbonate level was 26, and the average phosphorus level was 9. MRI, magnetic resonance imaging.

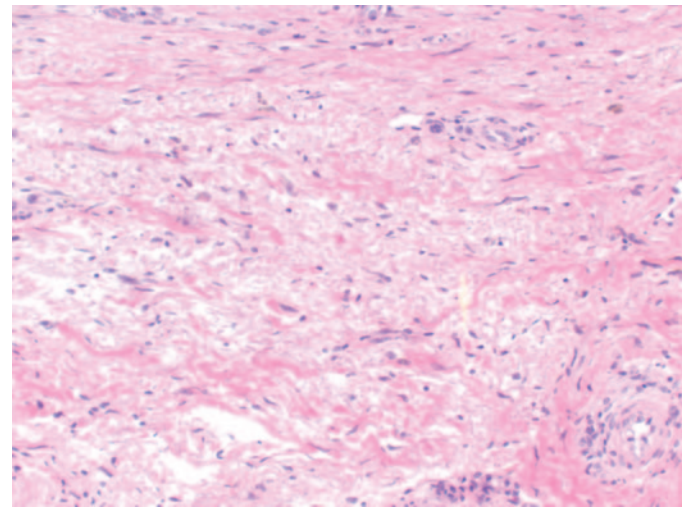


Figure 3. Thickened dermis with haphazardly arranged collagen bundles, increased dermal mucin, and scattered pigmented macrophages seen in a skin biopsy specimen in NSF. Biopsy was done approximately 1 to 1.5 mo after the initiation of STS therapy, with improvement in pain and skin changes.

been proposed in the development of NSF; the first hypothesis suggests possible infiltration of the affected tissues by  $CD68^{+}/XIIIa^{+}$  dendritic cells as a host response to noxious substances. These activated dendritic cells produce  $TGF-\beta$ , which not only initiates fibrosis but also enhances dendritic cell function, thereby initiating a vicious cycle of events that cause excess accumulation of dendritic cells in the affected tissues and extensive tissue fibrosis (13). A second hypothesis suggests the possibility that bone marrow–derived  $CD45RO^{+}/CD34^{+}/collagen\ I^{+}$  circulatory fibrocyte is released as a response to noxious stimuli in patients with NSF, resulting in fibrosis (14).

Recent case reports suggested development of NSF after administration of gadodiamide for MR angiography (which involves administration of gadodiamide at a dosage three times higher than the dosage approved by FDA for MRI in healthy patients), but our patient became symptomatic after repeated  $Gd^{3+}$ -based MRI exposures. This leads us to hypothesize a dosage-dependent effect of the association of gadodiamide with the development of NSF (G.S., personal observation).

Table 3. Timeline of MRI exams and onset of skin changes<sup>a</sup>

1/30/03	6/7/06	7/15/03	8/1/03	11/24/03	January to February 2004
→ MR venogram (to check patency of HD catheter)	→ MRI of lower extremities (R/O fracture)	→ MRI of pelvis/hips (R/O AVN of hips)	→ MRI pelvis/hips (R/O fracture)	→ MRI pelvis/hips (R/O fracture)	→ Skin/joint changes

<sup>a</sup>AVN, avascular necrosis; HD, hemodialysis; R/O, rule out.

Additional factors that have been postulated to contribute to the pathogenesis of NSF include large boluses of intravenous iron and recombinant epoetin (8,15). In addition to Gd<sup>3+</sup>, iron and other metal deposits have been described in skin specimens from patients with NSF. It is possible that the interactions between iron molecules and the ligand agent might contribute to the development of NSF. Our patient was receiving both epoetin (100 to 200 U/kg with each dialysis) and intravenous iron (100 mg/wk) in the months before and after the development of her symptoms.

Swaminathan *et al.* (15) found a higher median weekly epoetin dosage among case patients than control subjects (427 versus 198 U/kg). Of note, case patients had a higher serum ferritin and lower serum albumin (which was the case with our patient [Table 1]) than control subjects, suggesting chronic inflammation and decreased epoetin responsiveness. Although it is conceivable that the epoetin itself could be contributing to the development of NSF, another hypothesis is that patients with chronic inflammation have significantly greater endothelial dysfunction, leading to the extravascular accumulation of gadodiamide and leading to NSF. Alternatively, chronic inflammation may result in an accelerated fibrotic response. Here, higher dosages of epoetin may simply be a manifestation of resistance to epoetin secondary to the inflammation.

*Possible Mechanism of Action of STS in NSF*

STS (Na<sub>2</sub>S<sub>2</sub>O<sub>3</sub>) is a white crystalline substance that has reducing/antioxidant and chelating properties with multiple uses, including photography, treatment of cyanide poisoning,

prevention of carboplatin-related (16) and cisplatin-related (17) toxicity, and most recently in the treatment of calciphylaxis (18,19). We propose yet another potential use of STS in the treatment of the debilitating disease NSF.

STS has FDA-labeled indications for the treatment of acne, Tinea versicolor, and cyanide poisoning, but other uses are off-label. Available evidence from human studies suggests that it is a safe drug with minimal adverse effects at the dosages currently used. The most common adverse effects are nausea and vomiting (usually during the infusion). Usual dosages are 12.5 to 25 g with every dialysis.

It is important to realize that both calciphylaxis and NFD can be present in the same patients, as described in a study by Edsall *et al.* (20). Association between metastatic calcification and NSF has also been described in many studies (3,21–23). TGF-β/Smad signaling cascades have been proposed as common factors in the pathogenesis of both of these conditions (*i.e.*, fibrosis in NSF and calcification in calciphylaxis/metastatic calcification [20]). Therefore, it is possible that there is a similar mechanism of action of STS in both NFD and calciphylaxis, but further studies are needed to establish this relationship.

The beneficial effect of STS in our patient was rather dramatic with marked improvement in pain and skin changes after the first few treatments. We hypothesized that the beneficial effects of STS could be due to its chelating and antioxidant properties (Table 4).

It is possible that STS may chelate Gd<sup>3+</sup>, like other cations, and enhance its solubility and stability in serum, thereby facil-

Table 4. Reactions showing the chelating and antioxidant properties of STS<sup>a</sup>

Equation 1: Reaction showing the chelating property of STS						
2Gd <sup>3+</sup>	+	3(S <sub>2</sub> O <sub>3</sub> ) <sup>2-</sup>	→	Gd <sub>2</sub> (S <sub>2</sub> O <sub>3</sub> ) <sub>3</sub>		
Gadolinium cation	+	Thiosulfate anion	→	Gadolinium thiosulfate		
Equation 2: Reaction showing the antioxidant property of STS						
1GSSG	+	2Na <sub>2</sub> S <sub>2</sub> O <sub>3</sub>	(5H <sub>2</sub> O <sub>2</sub> ) (O <sub>2</sub> <sup>-</sup> ) superoxide	4NaHSO <sub>4</sub>	+	2GSH + 2H <sub>2</sub> O
Oxidized glutathione	+	STS	→	sodium bisulfate	+	glutathione
			→	glutathione oxireductase		

<sup>a</sup>STS, sodium thiosulfate.

itating its excretion during dialysis. If the  $Gd^{3+}$  precipitates in the tissue are the trigger for the fibrosis in NSF, then its removal may have helped ameliorate our patient's condition. The diffuse arterial calcification that was noted in our patient and the effect of STS in chelating cations including both  $Gd^{3+}$  and calcium could also explain the improvement in skin changes. However, the effects of STS occurred rapidly in our patient, a benefit that cannot be attributed solely to its chelating action.

$Gd^{3+}$  has been shown to accumulate in sites adjacent to recent endothelial trauma or inflammation, eventually leading to the worsening of endothelial dysfunction in patients who have chronic kidney disease or are on dialysis (which was the case with our patient) (24). STS could restore this endothelial dysfunction by its antioxidant properties (ability to donate electrons to pair unpaired free radicals), which has a positive effect on endothelial nitric oxide (eNO) synthase uncoupling and in the production of eNO (19). eNO has several positive effects in the maintenance of a healthy, normally functioning endothelium, including scavenging of reactive oxygen species, anti-inflammatory effect, fibrinolysis, and vasodilation. It is also likely that STS has the same beneficial effect in the neuronal vascular bed—the vasa nervorum and the endoneurium of the peripheral neuronal unit (25)—which may explain the rapid improvement of pain. The chelation of calcium/ $Gd^{3+}$  may also contribute to its beneficial effect; however, this is most likely a long-term effect.

## Conclusion

The cause and pathophysiology of NSF are still obscure, but multiple associations, including but not limited to recent vascular surgeries, high-dosage iron, and epoetin therapy, have been described in the literature. Some of these associations have been noted in our patient along with the temporal relation of multiple  $Gd^{3+}$ -based MRI exposures to the development of NSF. Recent literature suggests an association between gadodiamide exposure and the development of NSF, but the direct cause–effect relationship has not been proved conclusively. We also hypothesize a dosage-dependent association with exposure to gadodiamide in the development of NSF in functionally anephric patients. The beneficial effect of STS that was observed in our patient is also very encouraging and suggests a potential for its use in the treatment of this debilitating condition, for which an effective treatment modality has not been found yet.

## Acknowledgments

This work, in part, has been submitted in abstract form for the Annual Dialysis Conference, in Denver, Colorado; February 18 to 20, 2007.

## Disclosures

None.

## References

1. Cowper SE, Robin HS, Steinberg SM, Su LD, Gupta S, LeBoit PE: Scleromyxoedema-like cutaneous diseases in renal-dialysis patients. *Lancet* 356: 1000–1001, 2000
2. Mendoza F, Artlett C, Sandorfi N, Latinis K, Piera-Velazquez S, Jimenez S: Description of 12 cases of nephrogenic fibrosing dermopathy and review of the literature. *Semin Arthritis Rheum* 35: 238–249, 2006
3. Ting WW, Stone MS, Madison KC, Kurtz K: Nephrogenic fibrosing dermopathy with systemic involvement. *Arch Dermatol* 139: 903–906, 2003
4. Grobner T: Gadolinium: A specific trigger for the development of nephrogenic fibrosing dermopathy and nephrogenic systemic fibrosis. *Nephrol Dial Transplant* 21: 1104–1108, 2006
5. Marckmann P, Skov L, Rossen K, Dupont A, Damholt MB, Heaf JG, Thomsen HS: Nephrogenic systemic fibrosis: Suspected causative role of gadodiamide used for contrast-enhanced magnetic resonance imaging *J Am Soc Nephrol* 17: 2359–2362, 2006
6. FDA: *Public Health Advisory: Gadolinium-Containing Contrast Agents for Magnetic Resonance Imaging (MRI)—Omniscan, OptiMARK, Magnevist, ProHance, and MultiHance*, Washington, DC, FDA, 2006
7. Boyd A, Zic J, Abraham J: Gadolinium deposition in nephrogenic fibrosing dermopathy. *J Am Acad Dermatol* 56: 27–30, 2007
8. High W, Ayers R, Chandler J, Zito G, Cowper S: Gadolinium is detectable within the tissue of patients with nephrogenic systemic fibrosis. *J Am Acad Dermatol* 56: 21–26, 2007
9. Runge VM: Safety of approved MR contrast media for intravenous injection. *J Magn Reson Imaging* 12: 205–213, 2000
10. Townsend RR, Cohen DL, Katholi R, Swan SK, Davies BE, Benseal K, Lambrecht L, Parker J: Safety of intravenous gadolinium (Gd-BOPTA) infusion in patients with renal insufficiency. *Am J Kidney Dis* 36: 1207–1212, 2000
11. Joffe P, Thomsen HS, Meusel M: Pharmacokinetics of gadodiamide injection in patients with severe renal insufficiency and patients undergoing hemodialysis or continuous ambulatory peritoneal dialysis. *Acad Radiol* 5: 491–502, 1998
12. Mann JS: Stability of gadolinium complexes in vitro and in vivo. *J Comput Assist Tomogr* 17[Suppl 1]: S19–S23, 1993
13. Jimenez SA, Artlett CM, Sandorfi N, Derk C, Latinis K, Sawaya H, Haddad R, Shanahan JC: Dialysis-associated systemic fibrosis (nephrogenic fibrosing dermopathy): Study of inflammatory cells and transforming growth factor beta1 expression in affected skin. *Arthritis Rheum* 50: 2660–2666, 2004
14. Ortonne N, Lipsker D, Chantrel F, Boehm N, Grosshans E, Cribier B: Presence of CD45RO+ CD34+ cells with collagen synthesis activity in nephrogenic fibrosing dermopathy: A new pathogenic hypothesis. *Br J Dermatol* 150: 1050–1052, 2004
15. Swaminathan S, Ahmed I, McCarthy J, Albright R, Pittelkow M, Caplice N, Griffin MD, Leung N: Nephrogenic fibrosing dermopathy and high-dose erythropoietin therapy. *Ann Intern Med* 145: 234–235, 2006
16. Neuwelt EA, Brummett RE, Doolittle ND, Muldoon LL, Kroll RA, Pagel MA, Dojan R, Church V, Remsen LG, Bubalo JS: First evidence of otoprotection against carboplatin-induced hearing loss with a two-compartment system in patients with central nervous system malignancy using sodium thiosulfate. *J Pharmacol Exp Ther* 286: 77–84, 1998

17. Viallet NR, Blakley BW, Begleiter A, Leith MK: Effect of sodium thiosulphate and cis-diamminedichloroplatinum on FADU tumour cells in nude mice. *J Otolaryngol* 34: 371–373, 2005
18. Brucculeri M, Cheigh J, Bauer G, Serur D: Long-term intravenous sodium thiosulfate in the treatment of a patient with calciphylaxis. *Semin Dial* 18: 431–434, 2005
19. Hayden MR, Tyagi SC, Kolb L, Sowers JR, Khanna R: Vascular ossification-calcification in metabolic syndrome, type 2 diabetes mellitus, chronic kidney disease, and calciphylaxis-calcific uremic arteriopathy: The emerging role of sodium thiosulfate. *Cardiovasc Diabetol* 4: 4, 2005
20. Edsall LC, English JC 3rd, Patterson JW: Calciphylaxis and metastatic calcification associated with nephrogenic fibrosing dermopathy. *J Cutan Pathol* 31: 247–253, 2004
21. Cowper SE, Su LD, Bhawan J, Robin HS, Leboit PE: Nephrogenic fibrosing dermopathy. *Am J Dermatopathol* 23: 383, 2001
22. Streams BN, Liu V, Liegeois N, Moschella SM: Clinical and pathologic features of nephrogenic fibrosing dermopathy: A report of two cases. *J Am Acad Dermatol* 48: 42–47, 2003
23. Swartz RD, Crofford LJ, Phan SH, Ike RW, Su LD: Nephrogenic fibrosing dermopathy: A novel cutaneous fibrosing disorder in patients with renal failure. *Am J Med* 114: 563–572, 2003
24. Cowper SE: Nephrogenic fibrosing dermopathy: The first 6 years. *Curr Opin Rheumatol* 15: 785, 2003
25. Hayden M, Tyagi S: Neural redox stress and remodeling in metabolic syndrome, type 2 diabetes mellitus, and diabetic neuropathy. *Med Sci Monit* 10: RA291–RA307, 2004

See the related editorial, “Nephrogenic Systemic Fibrosis, Kidney Disease, and Gadolinium: Is There a Link?” on pages 200–202.