

# Acute Kidney Injury and CKD Associated with Hematopoietic Stem Cell Transplantation

Amanda DeMauro Renaghan,<sup>1</sup> Edgar A. Jaimes,<sup>2</sup> Jolanta Malyszko,<sup>3</sup> Mark A. Perazella,<sup>4,5</sup> Ben Sprangers,<sup>6,7</sup> and Mitchell Howard Rosner<sup>1</sup>

## Abstract

**Hematopoietic stem cell transplantation is a life-saving therapy for many patients with cancer, as well as patients with some nonmalignant hematologic disorders, such as aplastic anemia, sickle cell disease, and certain congenital immune deficiencies. Kidney injury directly associated with stem cell transplantation includes a wide range of structural and functional abnormalities, which may be vascular (hypertension, thrombotic microangiopathy), glomerular (albuminuria, nephrotic glomerulopathies), and/or tubulointerstitial. AKI occurs commonly after stem cell transplant, affecting 10%–73% of patients. The cause is often multifactorial and can include sepsis, nephrotoxic medications, marrow infusion syndrome, hepatic sinusoidal obstruction syndrome, thrombotic microangiopathy, infections, and graft versus host disease. The risk of post-transplant kidney injury varies depending on patient characteristics, type of transplant (allogeneic versus autologous), and choice of chemotherapeutic conditioning regimen (myeloablative versus nonmyeloablative). Importantly, AKI is associated with substantial morbidity, including the need for KRT in approximately 5% of patients and the development of CKD in up to 60% of transplant recipients. AKI has been associated universally with higher all-cause and nonrelapse mortality regardless of transplant type, and studies have consistently shown extremely high (>80%) mortality rates in those patients requiring acute dialysis. Accordingly, prevention, early recognition, and prompt treatment of kidney injury are essential to improving kidney and patient outcomes after hematopoietic stem cell transplantation, and for realizing the full potential of this therapy.**

CJASN 15: 289–297, 2020. doi: <https://doi.org/10.2215/CJN.08580719>

## Introduction

Hematopoietic stem cell transplantation is a life-saving therapy (1). Along with other transplant-related organ toxicities, both acute and CKD occur commonly after stem cell transplant, leading to substantial morbidity and mortality (2). Kidney injury directly associated with transplantation includes a wide range of abnormalities, which may be vascular (hypertension, thrombotic microangiopathy [TMA]), glomerular (albuminuria, glomerulopathies), and/or tubulointerstitial. The causes of transplant-associated kidney injury are multifactorial; contributing factors include chemotherapeutic conditioning regimen, radiation, sepsis, nephrotoxins, marrow infusion syndrome, hepatic sinusoidal obstruction syndrome, TMA, infections, and graft versus host disease (GVHD) (2–4). Frequency, timing, and risk factors for kidney injury vary by patient characteristics and the type of transplant performed.

## Types of Hematopoietic Stem Cell Transplantation

Hematopoietic stem cell transplantation involves upfront chemotherapy with or without radiotherapy, followed by bone marrow rescue by engraftment of stem or progenitor cells, which are harvested from bone marrow, peripheral blood, or umbilical cord blood (Table 1) (2,5). Stem or progenitor cells may come from the affected patient (autologous) or from a sibling or unrelated donor (allogeneic). In both

myeloablative allogeneic and autologous transplantation, high-dose chemotherapy and radiation are given to eradicate the bone marrow and underlying cancer. Those patients not eligible for aggressive myeloablative therapy because of age or comorbidities may still be candidates for nonmyeloablative (“miniallo”) transplants, which utilize lower-intensity (less toxic) conditioning regimens. The goals of nonmyeloablative regimens are not to eradicate the bone marrow or malignant cells, but to provide sufficient immunosuppression to permit the engraftment of transplanted stem cells, which then target tumor cells (“graft versus tumor” effect) (1,2,5). Importantly, both myeloablative allogeneic and nonmyeloablative allogeneic transplantation require the use of post-transplant immunosuppression, often with a calcineurin inhibitor, for prevention of GVHD. Autologous transplantation does not require GVHD prophylaxis.

## Epidemiology of AKI Incidence and Outcomes

AKI is a common complication after stem cell transplantation, with varied incidences depending on the definition of AKI, chemotherapeutic conditioning regimen (myeloablative versus nonmyeloablative), and type of transplant (allogeneic versus autologous) (6). In general, myeloablative regimens

<sup>1</sup>Division of Nephrology, University of Virginia Health System, Charlottesville, Virginia; <sup>2</sup>Department of Medicine, Renal Service, Memorial Sloan Kettering Cancer Center, New York, New York;

<sup>3</sup>Department of Nephrology, Dialysis and Internal Medicine, Warsaw Medical University, Warsaw, Poland; <sup>4</sup>Section of Nephrology, Yale University School of Medicine, New Haven, Connecticut;

<sup>5</sup>Veterans Affairs Medical Center, West Haven, Connecticut; <sup>6</sup>Department of Microbiology and Immunology, Laboratory of Molecular Immunology, Rega Institute, KU Leuven, Belgium; and

<sup>7</sup>Division of Nephrology, University Hospitals Leuven, Leuven, Belgium

## Correspondence:

Dr. Amanda DeMauro Renaghan, Division of Nephrology, Box 800133, University of Virginia Health System, Charlottesville, VA 22908. Email: [ajd9y@virginia.edu](mailto:ajd9y@virginia.edu)

**Table 1. Types of hematopoietic stem cell transplant**

<p><b>Source of stem or progenitor cells</b>          Bone marrow          Peripheral blood          Umbilical cord blood</p> <p><b>Type of donor</b>          Autologous (patient)          Allogeneic (relative [usually a nonidentical sibling] or unrelated donor; requires prophylaxis against GVHD, often in the form of a CNI)          Syngeneic (identical twin)</p> <p><b>Type of conditioning regimen</b>          Myeloablative (most toxic; aims to eradicate the bone marrow and underlying cancer)          Nonmyeloablative (least toxic; aims to provide sufficient immunosuppression to permit engraftment of transplanted cells, which target tumor cells [graft versus tumor effect])          Reduced-intensity conditioning (intermediate intensity)</p>
<p>GVHD, graft versus host disease; CNI, denotes calcineurin inhibitor.</p>

are associated with greater nephrotoxicity than nonmyeloablative regimens, and risk of AKI is higher with allogeneic compared with autologous transplantation (2).

In a landmark study analyzing 272 patients after myeloablative transplant (89% allogeneic, 11% autologous), 53% of patients developed AKI (defined as a doubling of serum creatinine); approximately half of these patients required dialysis (7). Subsequent studies published by Parikh *et al.* (8,9) similarly demonstrated very high rates of AKI after myeloablative allogeneic transplantation. Importantly, myeloablative allogeneic therapy was associated with a greater incidence of severe kidney failure (73% versus 47%) and a four-fold greater need for dialysis (12% versus 3%) compared with patients in the nonmyeloablative group. Incidence of AKI in the myeloablative group was 4.8-fold higher after controlling for baseline characteristics including age and comorbidities (9). These differences have been attributed to the greater toxic exposures associated with myeloablative conditioning. Autologous transplantation has the lowest incidence of AKI (approximately 20%); this has been ascribed to the absence of GVHD, lack of calcineurin inhibitor exposure, and more rapid engraftment (fewer cytopenias leading to less sepsis and nephrotoxic antibiotic exposure) (2,10,11). Recent data suggest that the incidence of AKI after stem cell transplantation is decreasing, potentially owing to the use of lower-dose myeloablative regimens and lower risks of sinusoidal obstruction syndrome, Gram-negative bacteremia, and severe GVHD, along with decreased exposure to amphotericin B (12,13). As with AKI incidence, the risk of requiring KRT after transplantation varies widely, with published rates ranging from 0% (autologous) to 33% (myeloablative allogeneic) (14,15). Overall, approximately 5% of patients develop AKI requiring hemodialysis (15,16).

AKI has been associated with higher all-cause and nonrelapse mortality, and AKI occurring before engraftment is associated with an inferior prognosis (15,17). Mortality is higher with worsening degrees of kidney

failure regardless of transplant type, and studies have consistently shown extremely high (>80%) mortality rates in those patients requiring acute dialysis (7,8,12,18–20).

### Risk Factors

AKI generally occurs in the first month after myeloablative transplantation (21,22). During this early post-transplant period, patients are more susceptible to AKI because of the toxicities associated with the intense conditioning regimens used, including sepsis, hepatic sinusoidal obstruction syndrome, and medication-induced kidney injury (6). It has been suggested that the engraftment syndrome, which occurs within the first 30 days post-transplant and is characterized by fever, erythematous skin rash, and noncardiogenic pulmonary edema, is also linked to AKI (23). This syndrome is more common after autologous transplant, but can also occur after myeloablative and nonmyeloablative allogeneic transplant (23,24).

Reported risk factors for development of AKI after nonmyeloablative allogeneic transplantation include diabetes mellitus, receiving more than three previous courses of chemotherapy, and use of methotrexate for GVHD prophylaxis (21). GVHD itself is also a risk factor for AKI, but only after day 100, and cyclosporine levels have not been shown to be clearly predictive for development of AKI (21). However, the use of cyclosporine in patients with diabetes is strongly linked to a higher risk for AKI, especially during the first 100 days post-transplant (25).

### Pathophysiology of AKI

For a full overview of the pathophysiology of AKI, see Figure 1.

### Sepsis

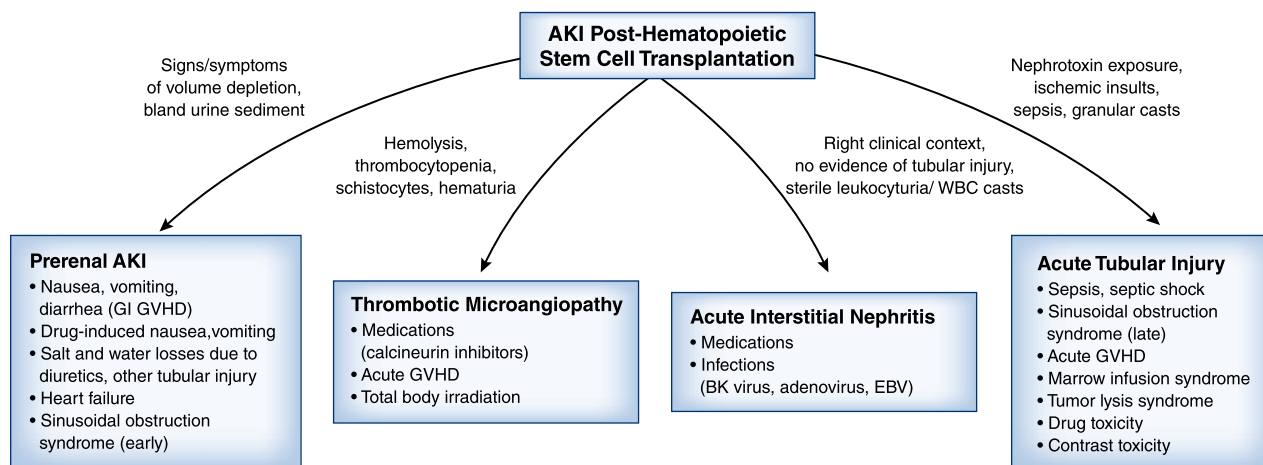
Immunocompromised recipients may develop infections that lead to sepsis complicated by AKI (10,26). Sepsis-induced AKI occurs from systemic vasodilatation with hypotension and kidney hypoperfusion, cytokine-related tubulointerstitial injury, and intrarenal endothelial dysfunction with capillary thrombosis (27,28). Nephrotoxic medications, such as aminoglycosides and vancomycin (often in combination with piperacillin-tazobactam), may contribute to sepsis-related AKI (26,27).

### Tumor Lysis Syndrome

Patients with hematologic malignancies, and rarely solid cancers, may develop tumor lysis syndrome complicated by AKI. However, this is a rare complication after stem cell transplantation as the cancer is often eliminated by the time of transplant. When it occurs, AKI results from cytokine-related kidney damage, crystalline-induced tubular injury (hyperuricemia/hyperphosphatemia), or crystal-independent uric acid-related nephrotoxicity (29–31).

### Nephrotoxic Medications

Several antimicrobial agents are well known causes of AKI; mechanisms include direct kidney injury and idiosyncratic allergic responses leading to acute interstitial nephritis.



**Figure 1.** | Etiologies of AKI after hematopoietic stem cell transplantation.

Aminoglycosides may cause AKI in at-risk patients. Underlying CKD, volume depletion, liver disease, exposure to other nephrotoxins, multiple versus single dosing aminoglycoside regimens, and prolonged exposure increase risk for AKI after stem cell transplantation (32). Classically, AKI develops after 7–10 days of drug exposure; however, tubular injury often occurs earlier. Tubulopathies such as proximal tubulopathy/Fanconi syndrome and Bartter-like syndrome may also develop (32).

Sulfonamides and ciprofloxacin may cause post-transplant AKI, especially in the setting of sepsis and volume depletion. Excessive drug dosing for underlying kidney function has been associated with crystalline-induced tubular injury. Acidic urine increases sulfonamide-induced crystal deposition within tubules, whereas alkaline urine increases ciprofloxacin-related crystal tubular deposition (32).

Acyclovir, used for the prevention and treatment of certain viral infections in patients receiving stem cell transplant, has been associated with crystalline-related tubular injury and obstruction. However, with adequate hydration, appropriate dosing for level of kidney function, and slow intravenous infusion, this is quite rare (33).

The antifungal agents amphotericin B deoxycholate and the newer lipid-based (liposomal) preparations may cause AKI in patients who have other risk factors for AKI. These drugs cause AKI *via* kidney vasoconstriction and direct tubular toxicity (disruption of cell membranes), although the lipid-based preparations are less nephrotoxic (34). Nephrotoxicity is dose-related.

Calcineurin inhibitors are used to prevent GVHD in allogeneic recipients and are associated with AKI (26,29). These drugs promote kidney arteriolar vasoconstriction through activation of the renin-angiotensin-aldosterone system and increase oxidative stress causing kidney endothelial damage, and are associated with TMA (35,36). Renin-angiotensin-aldosterone system inhibition may be useful for prevention of calcineurin inhibitor nephrotoxicity (37).

### Marrow Infusion Syndrome

The process of stem cell preservation, which includes exposure to various cryoprotectants such as DMSO, can cause red blood cell (RBC) lysis (38). Subsequent infusion

of lysed RBCs during transplantation may cause fever, vomiting, and BP fluctuations, along with hemoglobin pigment nephropathy within 24–48 hours of transplantation (marrow infusion syndrome). AKI results from kidney vasoconstriction, direct hemoglobin cytotoxicity, and intratubular hemoglobin cast formation (38).

### Hepatic Sinusoidal Obstruction Syndrome

Hepatic sinusoidal obstruction syndrome (formerly known as veno-occlusive disease) after stem cell transplantation is associated with AKI (38). It occurs within 30 days of transplant and is more common after allogeneic therapy (38). Published incidence from recent studies ranges from 2% (by updated European Society for Blood and Marrow Transplantation criteria) to 31% (39).

Sinusoidal obstruction occurs from damage to sinusoidal endothelial cells and hepatocytes, which results in fibrous narrowing of small hepatic venules/sinusoids. Cytokine release and glutathione depletion may also cause hepatocellular necrosis and fibrosis (40,41). Pretransplantation cytoreductive regimens (busulfan, cyclophosphamide, and/or total body irradiation) are presumed triggers (42). The novel antibody-drug conjugates gemtuzumab ozogamicin and inotuzumab, given before transplantation for the treatment of acute myelogenous leukemia and acute lymphoblastic leukemia, respectively, have been implicated in recent studies (39).

Sinusoidal obstruction syndrome appears to be a variant of hepatorenal syndrome and is characterized by jaundice, painful hepatomegaly, and fluid retention (40,42,43). Patients are often diuretic resistant and spontaneous recovery is rare, with mortality rates approaching 80%, especially when dialysis is needed (41).

### Acute TMA

Acute transplant-associated TMA is characterized pathologically by endothelial cell swelling, fibrin thrombi within capillary loops and arterioles, fragmented RBCs, and thickened glomerular and arteriolar vasculature (36). Subclinical kidney disease, AKI, or CKD may result (36).

It is unclear if TMA is a direct complication of transplantation or a manifestation of GVHD, infection, or drug toxicity (44–47). Conditioning regimens and other

exposures may promote kidney endothelial injury with subsequent TMA. Recent studies also support that transplantation may unmask undiagnosed alternative complement pathway mutations, resulting in atypical hemolytic uremic syndrome; mutations in complement factor H, complement factor I, complement factor B, MCP/CD46, and C3 comprise about 50% of known mutations and can be screened for (48). TMA may also be a consequence of GVHD (49,50). When associated with GVHD, patients tend to be steroid refractory/resistant and may have activation of the alternative complement pathway, and thus be amenable to therapy with complement blockade (51).

Two consensus guidelines describe clinical criteria for the diagnosis of transplant-associated TMA and include (1) schistocytes on peripheral smear and (2) elevated lactate dehydrogenase (52,53). The Blood and Marrow Transplant Clinical Trials Network guidelines also include AKI, unexplained central nervous system dysfunction, and negative Coombs test (52). Thrombocytopenia, anemia, and decreased haptoglobin are required in International Guidelines from the European Group for Blood and Marrow Transplantation (53). Unfortunately, these clinical criteria guidelines often do not correlate with histology (54).

#### Acute GN

Nephrotic syndrome after transplantation is a rare event (reported incidence of around 1%, with some evidence that this occurrence may be more common with nonmyeloablative therapy) (55–57). Typically, this syndrome develops more than 6 months after transplant and is thought to be related to tapering of immunosuppression and chronic GVHD, with dysregulation of both T and B cells and cytokines present as well as a high prevalence of autoantibodies to cellular and surface antigens (58). Most cases are identified by typical criteria of proteinuria, edema, and hypoalbuminemia. Kidney biopsies may be underperformed in this setting because of thrombocytopenia and coagulation abnormalities that increase the risks of biopsy. The most common pathologies encountered are membranous nephropathy and minimal change disease (59). In cases of transplant-associated membranous nephropathy, testing for anti-phospholipase A2 receptor antibodies is usually negative (60). Although the data are limited, most cases of nephrotic syndrome respond to increasing immunosuppression per standard guidelines used to treat these diseases (61).

#### Infections

BK virus and adenovirus infections develop in patients receiving hematopoietic stem cell transplant and may cause AKI. BK virus reactivation within the urogenital system can cause tubulointerstitial nephritis and hemorrhagic cystitis (62). Adenovirus infection may cause acute tubulointerstitial disease, but more commonly causes cystitis (63), especially in patients receiving allogeneic transplant who are heavily immunosuppressed and have severe GVHD (64).

#### Biomarkers for the Diagnosis of AKI

Several biomarkers have been widely investigated for early diagnosis of AKI, including neutrophil gelatinase-associated

lipocalin (NGAL), urine liver-type fatty acid-binding protein, and others. In the most recent prospective study of Benoit *et al.* (65) evaluating children undergoing allogeneic transplant, type and severity of AKI was assessed using weekly creatinine, serum cystatin C, and urine NGAL. These biomarkers were combined to define seven subtypes of AKI, depending upon the combination of positive biomarkers. Using this approach, 75% of patients were found to have AKI by at least one measure. Patients with all-biomarker-positive AKI were found to have the highest rates of morbidity and mortality. The authors concluded that use of all three biomarkers provides a more comprehensive profile of early AKI and identifies patients at highest risk of adverse outcomes, providing opportunities for early intervention (65). In a study by Deger *et al.* (66), serum cystatin C, but not urine NGAL, was a useful biomarker for early detection of AKI. By contrast, another study of allogeneic recipients showed significant relationship between urine NGAL and AKI (67). Shingai *et al.* (68) reported that higher baseline urine liver-type fatty acid-binding protein was linked with a high risk of AKI in patients receiving allogeneic transplant. There remains a knowledge gap and need for further research.

#### Prevention and Treatment of AKI

A brief overview of the prevention and treatment of AKI is shown in Table 2.

##### General Measures

Strict control of fluid balance is central to the prevention of post-transplant AKI, and therefore weight, BP, and urine output should be monitored regularly in all patients. Nephrotoxic medications and radiocontrast agents should be used cautiously (and ideally avoided).

Other recent developments that may lower risk of AKI include (1) using calcineurin-free regimens for prophylaxis of GVHD, as was shown in a study comparing post-transplant cyclophosphamide with calcineurin-based regimens that demonstrated better kidney function after 1 year in the group receiving cyclophosphamide; and (2) more personalized dosing regimens on the basis of knowledge of patient-specific factors such as drug levels and determining polymorphisms involved in drug metabolism (69,70). As an example, the rate of AKI after total body irradiation and cyclophosphamide conditioning was decreased by 38% when the second dose of cyclophosphamide was guided by measurement of the concentration of its metabolites in plasma after the first dose (70).

All patients with post-transplant AKI should be evaluated for occult infections, and a urinalysis and a kidney ultrasound should be performed. Nephrotoxic medications should be stopped (if possible), medication dosing should be adjusted according to changes in kidney function, and infections should be treated. Although rare, physicians should consider life-threatening complications such as TMA and hepatic sinusoidal obstruction syndrome. Although there are no established guidelines addressing the role of kidney biopsy after stem cell transplantation, we recommend consideration of biopsy in the following settings: (1) AKI of unclear cause, (2) failure of kidney function to recover as expected after

**Table 2. Prevention and management of hematopoietic stem cell transplant–associated AKI**

<p><b>Prevention and monitoring</b></p> <ul style="list-style-type: none"> <li>Optimization of fluid balance</li> <li>Careful use of nephrotoxic medication and contrast fluid</li> <li>Monitoring of kidney function</li> </ul> <p><b>Treatment: general measures</b></p> <ul style="list-style-type: none"> <li>Optimization of fluid balance</li> <li>Discontinuation of nephrotoxic medications</li> <li>Aggressive treatment of underlying infections</li> </ul> <p><b>Treatment: specific measures</b></p> <ul style="list-style-type: none"> <li>Marrow infusion syndrome: steroids</li> <li>Hepatic sinusoidal obstruction syndrome: albumin and terlipressin, defibrotide</li> <li>Thrombotic microangiopathy: treatment of hypertension, cessation of CNI, complement inhibition (?)</li> </ul>
CNI, calcineurin inhibitor.

initial modifications in therapy, and (3) presence of nephrotic-range proteinuria. As many post-transplant patients are coagulopathic and/or thrombocytopenic, biopsy should be performed with caution. KRT should be started in cases of refractory fluid overload or severe electrolyte disturbances; there is evidence suggesting that continuous convective techniques are preferable in this setting (71).

### Specific Treatments for Prevention and Treatment of AKI

**Marrow Infusion Syndrome.** Prevention of hemoglobin pigment nephropathy in marrow infusion syndrome includes urinary alkalinization and mannitol-induced diuresis to prevent heme-related nephrotoxicity (72,73).

Marrow infusion syndrome can be treated successfully with early steroid administration (23).

**Hepatic Sinusoidal Obstruction Syndrome.** Besides fluid/sodium restriction, administration of albumin together with terlipressin or early treatment with defibrotide, an antithrombotic and fibrinolytic agent, should be considered (74). Defibrotide prophylaxis (alone or in combination with ursodeoxycholic acid) has been reported to be beneficial in high-risk adult allogeneic transplant recipients, but should be evaluated in randomized trials (75,76).

**Acute TMA.** The most important intervention after diagnosis of TMA is withdrawal of calcineurin inhibitors (77). Plasma exchange has not been proven to be effective in randomized trials. Several other interventions, including rituximab, recombinant thrombomodulin, defibrotide, and pravastatin in combination with limaprost, have been reported to be beneficial, but their precise roles remain unclear at this time (78–81). The involvement of complement in the pathogenesis of transplant-associated TMA has led to the use of eculizumab with evidence of improved survival (82). Of note, the dose needed to achieve complement blockade is higher than in atypical hemolytic uremic syndrome (83). Other therapies that may show promise include the recombinant C5 inhibitor *Ornithodoros moubata* complement inhibitor (Coverdin) and OMS721, an mAb targeting MASP-2, the effector

enzyme of the lectin pathway of the complement system (84,85).

## CKD and Hematopoietic Stem Cell Transplantation

### Preexisting CKD

CKD is a common complication after stem cell transplantation associated with higher morbidity and mortality (2,86). On the other hand, presence of CKD is often used as an exclusion criterion when selecting patients to undergo transplant, especially when GVHD prophylaxis with a calcineurin inhibitor is contemplated.

Myelodysplastic syndrome, secondary acute myelogenous leukemia, and non-Hodgkin lymphoma are diseases of older patients with higher prevalence of CKD than in younger patients. Kidney function in these patients is frequently worsened by previous chemotherapy and exposure to nephrotoxic drugs. Nonmyeloablative conditioning regimens were developed as less toxic modalities of treatment for elderly patients and those with serious comorbidities, including CKD, who are not eligible for standard myeloablative therapy (87). De Souza *et al.* (88) reported that mild to moderate decrease in GFR was not associated with worse overall survival, nonrelapse mortality, or treatment-related mortality in 141 patients with high-risk myelodysplastic syndrome or acute myelogenous leukemia receiving reduced-intensity conditioning with fludarabine/melphalan. Kersting and Verdonck (89) showed that, in 13 patients with mildly reduced kidney function before nonmyeloablative allogeneic transplant, more than half of patients had improvement of kidney function after transplantation. It appears that the presence of CKD pretransplant should not be an exclusion criterion in settings where calcineurin inhibitor–free GVHD prophylaxis is available.

### CKD after Transplantation

**Epidemiology.** The incidence of kidney failure after hematopoietic stem cell transplantation has been reported to vary between 0% and 60% at  $\geq 6$  months (90–92). This wide variation is likely due, in part, to the use of different definitions of kidney dysfunction, duration of follow-up, and type of transplant (90–92). Importantly, stem cell transplant recipients develop ESKD at a rate far higher than seen in the general population, and the incidence of CKD after transplantation is anticipated to rise as the age of patients receiving stem cell transplant continues to increase (93).

Hingorani *et al.* (25) recently assessed a prospective cohort of 434 adults followed from the pretransplant period until a median of 5.3 years post-transplant. The largest decreases in eGFR were identified within the first year after transplantation, with eGFR decreasing from a median of 98 ml/min per 1.73 m<sup>2</sup> at baseline to 78 ml/min per 1.73 m<sup>2</sup> by 1 year. As eGFR declined from approximately 60 ml/min per 1.73 m<sup>2</sup>, the hazard of mortality progressively increased relative to a normal eGFR of 90 ml/min per 1.73 m<sup>2</sup> (1.15 versus eGFR 60 ml/min per 1.73 m<sup>2</sup> [95% confidence interval, 0.87 to 1.53], 1.68 versus eGFR 50 ml/min per 1.73 m<sup>2</sup> [95% confidence interval, 1.26 to 2.24], 2.67 versus eGFR 40 ml/min per 1.73 m<sup>2</sup> [95% confidence interval, 1.99 to 3.60]). Investigators noted that, although eGFR remained fairly stable after the initial decline, a decreased eGFR was significantly associated with higher risk of mortality (25).

Ando *et al.* (94) conducted a cross-sectional and retrospective study of 158 patients who survived  $\geq 3$  years after myeloablative transplantation. By National Kidney Foundation CKD staging, 27 patients (17%) developed CKD stage 3 or greater (stage 3, eight patients [5%]; stage 4, ten patients [6%]; stage 5, nine patients [6%]). Seven patients were started on hemodialysis or received a kidney transplant (94). Subsequently, Shimoi *et al.* retrospectively analyzed serum creatinine concentrations for 10 or more years in 77 patients who underwent myeloablative allogeneic transplantation. Cumulative incidence of CKD (defined as a persistent decrease in eGFR below 60 ml/min per 1.73 m<sup>2</sup>) increased over time, reaching 34% at 10 years (95).

**Risk Factors.** CKD is a long-term complication of stem cell transplantation associated with previous AKI, older age, lower pretreatment GFR, female sex, fludarabine conditioning, GVHD, calcineurin inhibitor exposure, TMA, glomerular diseases (membranous GN, minimal change disease, membranoproliferative GN, FSGS), and a variety of other factors (90–92,96). Radiation therapy has been implicated in post-transplant CKD, possibly by causing subacute or chronic TMA (radiation nephritis) (97–100). Hypertension has been recognized as a late complication of stem cell transplant, with incidence linked to the development of CKD (101). Albuminuria has been associated with progression of CKD and decreased post-transplant survival (102). Momoki *et al.* evaluated 251 patients without preexisting CKD for  $\geq 1$  year after allogeneic transplantation (median follow-up 4 years). Incident proteinuria  $\geq 1+$  on urine dipstick was found to be a significant risk for incident CKD as defined by a persistent eGFR  $< 60$  ml/min per 1.73 m<sup>2</sup> (hazard ratio, 4.39; 95% confidence interval, 2.44 to 7.73). The authors concluded that patients who manifest dipstick proteinuria are predisposed to nephropathy and strongly recommended routine monitoring by urine dipstick (103).

## Conclusions

Hematopoietic stem cell transplantation is a critical therapy for many patients with cancer. AKI occurs commonly after transplant and is associated with significant morbidity and decreased patient survival. Risk of CKD is also higher after hematopoietic stem cell transplantation. Research is ongoing to find reliable biomarkers for the early detection of subclinical kidney injury in the post-transplant setting. Prevention, early recognition, and prompt treatment of kidney injury are essential to improving kidney and patient outcomes.

## Disclosures

Dr. Jaimes is cofounder of and a stockholder in Goldilocks Therapeutics. Dr. Malyszko reports Advisory Board positions with Opterion and Vifor Pharma. Dr. Rosner reports receiving consulting fees from Baxter and Data Safety Monitoring Board positions with Reata and Retrophin. Dr. Rosner is also on the Editorial Board of *CJASN*. Dr. Perazella, Dr. Renaghan, and Dr. Sprangers have nothing to disclose.

## Funding

Dr. Jaimes is supported by National Institutes of Health grant P30CA008748.

## References

1. Copelan EA: Hematopoietic stem-cell transplantation. *N Engl J Med* 354: 1813–1826, 2006
2. Parikh CR, Coca SG: Acute renal failure in hematopoietic cell transplantation. *Kidney Int* 69: 430–435, 2006
3. Hingorani SR, Guthrie K, Batchelder A, Schoch G, Aboulhosn N, Manchion J, McDonald GB: Acute renal failure after myeloablative hematopoietic cell transplant: Incidence and risk factors. *Kidney Int* 67: 272–277, 2005
4. Rosner MH, Perazella MA: Acute kidney injury in patients with cancer. *N Engl J Med* 377: 500–501, 2017
5. Gyurkocza B, Sandmaier BM: Conditioning regimens for hematopoietic cell transplantation: One size does not fit all. *Blood* 124: 344–353, 2014
6. Hingorani S: Renal complications of hematopoietic-cell transplantation. *N Engl J Med* 374: 2256–2267, 2016
7. Zager RA, O'Quigley J, Zager BK, Alpers CE, Shulman HM, Gamelin LM, Stewart P, Thomas ED: Acute renal failure following bone marrow transplantation: A retrospective study of 272 patients. *Am J Kidney Dis* 13: 210–216, 1989
8. Parikh CR, McSweeney PA, Korular D, Ecder T, Merouani A, Taylor J, Slat-Vasquez V, Shpall EJ, Jones RB, Bearman SI, Schrier RW: Renal dysfunction in allogeneic hematopoietic cell transplantation. *Kidney Int* 62: 566–573, 2002
9. Parikh CR, Schrier RW, Storer B, Diaconescu R, Sorror ML, Maris MB, Maloney DG, McSweeney P, Storb R, Sandmaier BM: Comparison of ARF after myeloablative and nonmyeloablative hematopoietic cell transplantation. *Am J Kidney Dis* 45: 502–509, 2005
10. Merouani A, Shpall EJ, Jones RB, Archer PG, Schrier RW: Renal function in high dose chemotherapy and autologous hematopoietic cell support treatment for breast cancer. *Kidney Int* 50: 1026–1031, 1996
11. Fadia A, Casserly LF, Sanchowala V, Seldin DC, Wright DG, Skinner M, Dember LM: Incidence and outcome of acute renal failure complicating autologous stem cell transplantation for AL amyloidosis. *Kidney Int* 63: 1868–1873, 2003
12. Canet E, Lengline E, Zafrani L, Peraldi MN, Socié G, Azoulay E: Acute kidney injury in critically ill allo-HSCT recipients. *Bone Marrow Transplant* 49: 1121–1122, 2014
13. Gooley TA, Chien JW, Pergam SA, Hingorani S, Sorror ML, Boeckh M, Martin PJ, Sandmaier BM, Marr KA, Appelbaum FR, Storb R, McDonald GB: Reduced mortality after allogeneic hematopoietic-cell transplantation. *N Engl J Med* 363: 2091–2101, 2010
14. Lopes JA, Jorge S, Silva S, de Almeida E, Abreu F, Martins C, do Carmo JA, Lacerda JF, Prata MM: Acute renal failure following myeloablative autologous and allogeneic hematopoietic cell transplantation. *Bone Marrow Transplant* 38: 707, 2006
15. Ando M, Mori J, Ohashi K, Akiyama H, Morito T, Tsuchiya K, Nitta K, Sakamaki H: A comparative assessment of the RIFLE, AKIN and conventional criteria for acute kidney injury after hematopoietic SCT. *Bone Marrow Transplant* 45: 1427–1434, 2010
16. Parikh CR, Yarlagadda SG, Storer B, Sorror M, Storb R, Sandmaier B: Impact of acute kidney injury on long-term mortality after nonmyeloablative hematopoietic cell transplantation. *Biol Blood Marrow Transplant* 14: 309–315, 2008
17. Shingai N, Morito T, Najima Y, Kobayashi T, Doki N, Kakihana K, Ohashi K, Ando M: Early-onset acute kidney injury is a poor prognostic sign for allogeneic SCT recipients. *Bone Marrow Transplant* 50: 1557–1562, 2015
18. Parikh CR, McSweeney P, Schrier RW: Acute renal failure independently predicts mortality after myeloablative allogeneic hematopoietic cell transplant. *Kidney Int* 67: 1999–2005, 2005
19. Gruss E, Bernis C, Tomas JF, Garcia-Canton C, Figuera A, Motellón JL, Paraiso V, Traver JA, Fernandez-Rañada JM: Acute renal failure in patients following bone marrow transplantation: Prevalence, risk factors and outcome. *Am J Nephrol* 15: 473–479, 1995
20. Parikh CR, Sandmaier BM, Storb RF, Blume KG, Sahebi F, Maloney DG, Maris MB, Nieto Y, Edelstein CL, Schrier RW, McSweeney P: Acute renal failure after nonmyeloablative hematopoietic cell transplantation. *J Am Soc Nephrol* 15: 1868–1876, 2004

21. Liu H, Li YF, Liu BC, Ding JH, Chen BA, Xu WL, Qian J: A multicenter, retrospective study of acute kidney injury in adult patients with nonmyeloablative hematopoietic SCT. *Bone Marrow Transplant* 45: 153–158, 2010
22. Piñana JL, Valcárcel D, Martino R, Barba P, Moreno E, Sureda A, Vega M, Delgado J, Briones J, Brunet S, Sierra J: Study of kidney function impairment after reduced-intensity conditioning allogeneic hematopoietic stem cell transplantation. A single-center experience. *Biol Blood Marrow Transplant* 15: 21–29, 2009
23. Chang L, Frame D, Braun T, Gatza E, Hanauer DA, Zhao S, Magenau JM, Schultz K, Tokala H, Ferrara JL, Levine JE, Reddy P, Paczesny S, Choi SW: Engraftment syndrome after allogeneic hematopoietic cell transplantation predicts poor outcomes. *Biol Blood Marrow Transplant* 20: 1407–1417, 2014
24. Carreras E, Fernández-Avilés F, Silva L, Guerrero M, Fernández de Larrea C, Martínez C, Rosiñol L, Lozano M, Marín P, Rovira M: Engraftment syndrome after auto-SCT: Analysis of diagnostic criteria and risk factors in a large series from a single center. *Bone Marrow Transplant* 45: 1417–1422, 2010
25. Hingorani S, Pao E, Stevenson P, Schoch G, Laskin BL, Gooley T, McDonald GB: Changes in glomerular filtration rate and impact on long-term survival among adults after hematopoietic cell transplantation: A prospective cohort study. *Clin J Am Soc Nephrol* 13: 866–873, 2018
26. Caliskan Y, Besik SK, Sargin D, Ecdar T: Early renal injury after myeloablative allogeneic and autologous hematopoietic cell transplantation. *Bone Marrow Transplant* 38: 141–147, 2006
27. Kogon A, Hingorani S: Acute kidney injury in hematopoietic cell transplantation. *Semin Nephrol* 30: 615–626, 2010
28. Schrier RW, Wang W: Acute renal failure and sepsis. *N Engl J Med* 351: 159–169, 2004
29. Sawinski D: The kidney effects of hematopoietic stem cell transplantation. *Adv Chronic Kidney Dis* 21: 96–105, 2014
30. Mughal TI, Ejaz AA, Foringer JR, Coiffier B: An integrated clinical approach for the identification, prevention, and treatment of tumor lysis syndrome. *Cancer Treat Rev* 36: 164–176, 2010
31. Shimada M, Johnson RJ, May WS Jr, Lingegowda V, Sood P, Nakagawa T, Van QC, Dass B, Ejaz AA: A novel role for uric acid in acute kidney injury associated with tumour lysis syndrome. *Nephrol Dial Transplant* 24: 2960–2964, 2009
32. Perazella MA: Pharmacology behind common drug nephrotoxicities. *Clin J Am Soc Nephrol* 13: 1897–1908, 2018
33. Perazella MA: Crystal-induced acute renal failure. *Am J Med* 106: 459–465, 1999
34. Cagnoni PJ: Liposomal amphotericin B versus conventional amphotericin B in the empirical treatment of persistently febrile neutropenic patients. *J Antimicrob Chemother* 49[Suppl 1]: 81–86, 2002
35. Raeisi S, Ghorbanihaghjo A, Argani H, Dastmalchi S, Seifi M, Ghasemi B, Ghazizadeh T, Abbasi MM, Karimi P: Oxidative stress-induced renal telomere shortening as a mechanism of cyclosporine-induced nephrotoxicity. *J Biochem Mol Toxicol* 32: e22166, 2018
36. Wanchoo R, Bayer RL, Bassil C, Jhaveri KD: Emerging concepts in hematopoietic stem cell transplantation-associated renal thrombotic microangiopathy and prospects for new treatments. *Am J Kidney Dis* 72: 857–865, 2018
37. Prókai Á, Csohány R, Sziksz E, Pap D, Balicza-Himer L, Boros S, Magda B, Vannay Á, Kis-Petik K, Fekete A, Peti-Peterdi J, Szabó AJ: Calcineurin-inhibition results in upregulation of local renin and subsequent vascular endothelial growth factor production in renal collecting ducts. *Transplantation* 100: 325–333, 2016
38. Zager RA: Acute renal failure in the setting of bone marrow transplantation. *Kidney Int* 46: 1443–1458, 1994
39. Corbacioglu S, Jabbour EJ, Mohty M: Risk factors for development of and progression of hepatic veno-occlusive disease/sinusoidal obstruction syndrome. *Biol Blood Marrow Transplant* 25: 1271–1280, 2019
40. Bearman SI: The syndrome of hepatic veno-occlusive disease after marrow transplantation. *Blood* 85: 3005–3020, 1995
41. Coppel JA, Richardson PG, Soiffer R, Martin PL, Kernan NA, Chen A, Guinan E, Vogelsang G, Krishnan A, Giral S, Revta C, Carreau NA, Iacobelli M, Carreras E, Ruutu T, Barbui T, Antin JH, Niederwieser D: Hepatic veno-occlusive disease following stem cell transplantation: Incidence, clinical course, and outcome. *Biol Blood Marrow Transplant* 16: 157–168, 2010
42. McDonald GB, Hinds MS, Fisher LD, Schoch HG, Wolford JL, Banaji M, Hardin BJ, Shulman HM, Clift RA: Venocclusive disease of the liver and multiorgan failure after bone marrow transplantation: A cohort study of 355 patients. *Ann Intern Med* 118: 255–267, 1993
43. Jones RJ, Lee KS, Beschorner WE, Vogel VG, Grochow LB, Braine HG, Vogelsang GB, Sensenbrenner LL, Santos GW, Saral R: Venocclusive disease of the liver following bone marrow transplantation. *Transplantation* 44: 778–783, 1987
44. Changsirikulchai S, Myerson D, Guthrie KA, McDonald GB, Alpers CE, Hingorani SR: Renal thrombotic microangiopathy after hematopoietic cell transplant: Role of GVHD in pathogenesis. *Clin J Am Soc Nephrol* 4: 345–353, 2009
45. George JN: Hematopoietic stem cell transplantation-associated thrombotic microangiopathy: Defining a disorder. *Bone Marrow Transplant* 41: 917–918, 2008
46. Kojouri K, George JN: Thrombotic microangiopathy following allogeneic hematopoietic stem cell transplantation. *Curr Opin Oncol* 19: 148–154, 2007
47. Tichelli A, Passweg J, Wójcik D, Rovó A, Harousseau JL, Masszi T, Zander A, Békássy A, Crowley C, Arat M, Sica S, Lutz P, Socié G; EBMT Late Effects Working Party: Late cardiovascular events after allogeneic hematopoietic stem cell transplantation: A retrospective multicenter study of the Late Effects Working Party of the European group for blood and marrow transplantation. *Haematologica* 93: 1203–1210, 2008
48. Caprioli J, Noris M, Brioschi S, Pianetti G, Castelletti F, Bettinaglio P, Mele C, Bresin E, Cassis L, Gamba S, Porrati F, Bucchioni S, Monteferrante G, Fang CJ, Liszewski MK, Kavanagh D, Atkinson JP, Remuzzi G; International Registry of Recurrent and Familial HUS/TTP: Genetics of HUS: The impact of MCP, CFH, and IF mutations on clinical presentation, response to treatment, and outcome. *Blood* 108: 1267–1279, 2006
49. Kanamori H, Maruta A, Sasaki S, Yamazaki E, Ueda S, Katoh K, Tamura T, Otsuka-Aoba M, Taguchi J, Harano H, Ogawa K, Mohri H, Okubo T, Matsuzaki M, Watanabe S, Koharazawa H, Fujita H, Kodama F: Diagnostic value of hemostatic parameters in bone marrow transplant-associated thrombotic microangiopathy. *Bone Marrow Transplant* 21: 705–709, 1998
50. Matsuda Y, Hara J, Osugi Y, Tokimasa S, Fujisaki H, Takai K, Ohta H, Kawa-Ha K, Okada S: Serum levels of soluble adhesion molecules in stem cell transplantation-related complications. *Bone Marrow Transplant* 27: 977–982, 2001
51. Wall SA, Zhan Q, Ranganathan P, Elder P, William BM, Puto M, Roddy J, Klisovic RB, Blum W, Benson DM, Jaglowski S, Mims AS, Brammer JE, Efebera YA, Hofmeister CC, Andritsos L, Penza S, Walker AR, Devine SM, Cataland SR, Vasu S: Transplant associated thrombotic microangiopathy (TA-TMA) commonly occurs after steroid-refractory or dependent gastrointestinal (GI) graft versus host disease (GVHD) and contributes to post-transplant morbidity. *Blood* 130 (Suppl 1): 4483, 2017
52. Ho VT, Cutler C, Carter S, Martin P, Adams R, Horowitz M, Ferrara J, Soiffer R, Giral S: Blood and marrow transplant clinical trials network toxicity committee consensus summary: Thrombotic microangiopathy after hematopoietic stem cell transplantation. *Biol Blood Marrow Transplant* 11: 571–575, 2005
53. Ruutu T, Barosi G, Benjamin RJ, Clark RE, George JN, Gratwohl A, Holler E, Iacobelli M, Kentouche K, Lämmle B, Moake JL, Richardson P, Socié G, Zeigler Z, Niederwieser D, Barbui T; European Group for Blood and Marrow Transplantation; European LeukemiaNet: Diagnostic criteria for hematopoietic stem cell transplant-associated microangiopathy: Results of a consensus process by an International Working Group. *Haematologica* 92: 95–100, 2007
54. Cho BS, Yahng SA, Lee SE, Eom KS, Kim YJ, Kim HJ, Lee S, Min CK, Cho SG, Kim DW, Lee JW, Min WS, Park CW: Validation of recently proposed consensus criteria for thrombotic microangiopathy after allogeneic hematopoietic stem-cell transplantation. *Transplantation* 90: 918–926, 2010
55. Beyar Katz O, Kruzel Davila E, Zuckerman T, Fineman R, Haddad N, Okasha D, Henig I, Rowe JM, Ofra Y: Nephrotic syndrome after hematopoietic stem cell transplantation: A single center experience. *Minerva Med* 106: 355–357, 2015

56. Reddy P, Johnson K, Uberti JP, Reynolds C, Silver S, Ayash L, Braun TM, Ratanatharathorn V: Nephrotic syndrome associated with chronic graft-versus-host disease after allogeneic hematopoietic stem cell transplantation. *Bone Marrow Transplant* 38: 351–357, 2006
57. Srinivasan R, Balow JE, Sabnis S, Lundqvist A, Igarashi T, Takahashi Y, Austin H, Tisdale J, Barrett J, Geller N, Childs R: Nephrotic syndrome: An under-recognized immune-mediated complication of non-myeloablative allogeneic hematopoietic cell transplantation. *Br J Haematol* 131: 74–79, 2005
58. Brukamp K, Doyle AM, Bloom RD, Bunin N, Tomaszewski JE, Cizman B: Nephrotic syndrome after hematopoietic cell transplantation: Do glomerular lesions represent renal graft-versus-host disease? *Clin J Am Soc Nephrol* 1: 685–694, 2006
59. Beyar-Katz O, Davila EK, Zuckerman T, Fineman R, Haddad N, Okasha D, Henig I, Leiba R, Rowe JM, Ofran Y: Adult nephrotic syndrome after hematopoietic stem cell transplantation: Renal pathology is the best predictor of response to therapy. *Biol Blood Marrow Transplant* 22: 975–981, 2016
60. Huang X, Qin W, Zhang M, Zheng C, Zeng C, Liu Z: Detection of anti-PLA2R autoantibodies and IgG subclasses in post-allogeneic hematopoietic stem cell transplantation membranous nephropathy. *Am J Med Sci* 346: 32–37, 2013
61. Kemper MJ, Güngör T, Halter J, Schanz U, Neuhaus T: Favorable long-term outcome of nephrotic syndrome after allogeneic hematopoietic stem cell transplantation. *Clin Nephrol* 67: 5–11, 2007
62. Hirsch HH, Steiger J: Polyomavirus BK. *Lancet Infect Dis* 3: 611–623, 2003
63. Ito M, Hirabayashi N, Uno Y, Nakayama A, Asai J: Necrotizing tubulointerstitial nephritis associated with adenovirus infection. *Hum Pathol* 22: 1225–1231, 1991
64. Bil-Lula I, Ussowicz M, Rybka B, Wendycz-Domalewska D, Ryczan R, Gorczyńska E, Kalwak K, Woźniak M: Hematuria due to adenoviral infection in bone marrow transplant recipients. *Transplant Proc* 42: 3729–3734, 2010
65. Benoit SW, Dixon BP, Goldstein SL, Bennett MR, Lane A, Louder DT, Rotz SJ, Gloude NJ, Lake KE, Litts B, Davies SM: A novel strategy for identifying early acute kidney injury in pediatric hematopoietic stem cell transplantation. *Bone Marrow Transplant* 54: 1453–1461, 2019
66. Deger SM, Erten Y, Suyani E, Aki SZ, Ulusal Okyay G, Pasaoglu OT, Pasaoglu H, Arinsoy T, Turkoz Sucak G: Early diagnostic markers for detection of acute kidney injury in allogeneic hematopoietic stem cell transplant recipients. *Exp Clin Transplant* doi:10.6002/ect.2016.0161
67. Taghizadeh-Ghehi M, Sarayani A, Ashouri A, Ataei S, Moslehi A, Hadjibabaie M: Urine neutrophil gelatinase associated lipocalin as an early marker of acute kidney injury in hematopoietic stem cell transplantation patients. *Ren Fail* 37: 994–998, 2015
68. Shingai N, Morito T, Najima Y, Igarashi A, Kobayashi T, Doki N, Kakihana K, Ohashi K, Ando M: Urinary liver-type fatty acid-binding protein linked with increased risk of acute kidney injury after allogeneic stem cell transplantation. *Biol Blood Marrow Transplant* 20: 2010–2014, 2014
69. Jacoby E, Chen A, Loeb DM, Gamper CJ, Zambidis E, Llosa NJ, Huo J, Cooke KR, Jones R, Fuchs E, Luznik L, Symons HJ: Single-agent post-transplantation cyclophosphamide as graft-versus-host disease prophylaxis after human leukocyte antigen-matched related bone marrow transplantation for pediatric and young adult patients with hematologic malignancies. *Biol Blood Marrow Transplant* 22: 112–118, 2016
70. McCune JS, Batchelder A, Guthrie KA, Witherspoon R, Appelbaum FR, Phillips B, Vicini P, Salinger DH, McDonald GB: Personalized dosing of cyclophosphamide in the total body irradiation-cyclophosphamide conditioning regimen: A phase II trial in patients with hematologic malignancy. *Clin Pharmacol Ther* 85: 615–622, 2009
71. Flores FX, Brophy PD, Symons JM, Fortenberry JD, Chua AN, Alexander SR, Mahan JD, Bunchman TE, Blowey D, Somers MJ, Baum M, Hackbarth R, Chand D, McBryde K, Benfield M, Goldstein SL: Continuous renal replacement therapy (CRRT) after stem cell transplantation. A report from the prospective pediatric CRRT Registry Group. *Pediatr Nephrol* 23: 625–630, 2008
72. Zager RA: Studies of mechanisms and protective maneuvers in myoglobinuric acute renal injury. *Lab Invest* 60: 619–629, 1989
73. Zager RA, Foerder C, Bredl C: The influence of mannitol on myoglobinuric acute renal failure: Functional, biochemical, and morphological assessments. *J Am Soc Nephrol* 2: 848–855, 1991
74. Kernan NA, Grupp S, Smith AR, Arai S, Triplett B, Antin JH, Lehmann L, Shore T, Ho VT, Bunin N, Iacobelli M, Liang W, Hume R, Tappe W, Soiffer R, Richardson P: Final results from a defibrotide treatment-IND study for patients with hepatic veno-occlusive disease/sinusoidal obstruction syndrome. *Br J Haematol* 181: 816–827, 2018
75. Mohty M, Malard F, Abecassis M, Aerts E, Alaskar AS, Aljurf M, Arat M, Bader P, Baron F, Bazarbachi A, Blaise D, Ciceri F, Corbacioglu S, Dalle JH, Duarte RF, Fukuda T, Huynh A, Masszi T, Michallet M, Nagler A, NiChonghaile M, Pagliuca T, Peters C, Petersen FB, Richardson PG, Ruutu T, Savani BN, Wallhult E, Yakoub-Agha I, Carreras E: Sinusoidal obstruction syndrome/veno-occlusive disease: Current situation and perspectives—a position statement from the European Society for Blood and Marrow Transplantation (EBMT). *Bone Marrow Transplant* 50: 781–789, 2015
76. Picod A, Bonnin A, Battipaglia G, Giannotti F, Ruggeri A, Brissot E, Malard F, Médiavilla C, Belhocine R, Vekhoff A, Gueye MS, Lapusan S, Adaeva R, Isnard F, Legrand O, Baylatry MT, Joly AC, Labopin M, Duléry R, Mohty M: Defibrotide for sinusoidal obstruction syndrome/veno-occlusive disease prophylaxis in high-risk adult patients: A single-center experience study. *Biol Blood Marrow Transplant* 24: 1471–1475, 2018
77. Cutler C, Henry NL, Magee C, Li S, Kim HT, Alyea E, Ho V, Lee SJ, Soiffer R, Antin JH: Sirolimus and thrombotic microangiopathy after allogeneic hematopoietic stem cell transplantation. *Biol Blood Marrow Transplant* 11: 551–557, 2005
78. Au WY, Ma ES, Lee TL, Ha SY, Fung AT, Lie AK, Kwong YL: Successful treatment of thrombotic microangiopathy after hematopoietic stem cell transplantation with rituximab. *Br J Haematol* 137: 475–478, 2007
79. Fujiwara H, Maeda Y, Sando Y, Nakamura M, Tani K, Ishikawa T, Nishimori H, Matsuoka K, Fujii N, Kondo E, Tanimoto M: Treatment of thrombotic microangiopathy after hematopoietic stem cell transplantation with recombinant human soluble thrombomodulin. *Transfusion* 56: 886–892, 2016
80. Corti P, Uderzo C, Tagliabue A, Della Volpe A, Annaloro C, Tagliaferri E, Balduzzi A: Defibrotide as a promising treatment for thrombotic thrombocytopenic purpura in patients undergoing bone marrow transplantation. *Bone Marrow Transplant* 29: 542–543, 2002
81. Uesawa M, Muroi K, Ozawa K: Plasmapheresis-refractory transplantation-associated thrombotic microangiopathy successfully treated with pravastatin and limaprost alfadex. *Ther Apher Dial* 17: 462–463, 2013
82. Jodele S, Fukuda T, Vinks A, Mizuno K, Laskin BL, Goebel J, Dixon BP, Teusink A, Pluthero FG, Lu L, Licht C, Davies SM: Eculizumab therapy in children with severe hematopoietic stem cell transplantation-associated thrombotic microangiopathy. *Biol Blood Marrow Transplant* 20: 518–525, 2014
83. Jodele S, Fukuda T, Mizuno K, Vinks AA, Laskin BL, Goebel J, Dixon BP, Chima RS, Hirsch R, Teusink A, Lazear D, Lane A, Myers KC, Dandoy CE, Davies SM: Variable eculizumab clearance requires pharmacodynamic monitoring to optimize therapy for thrombotic microangiopathy after hematopoietic stem cell transplantation. *Biol Blood Marrow Transplant* 22: 307–315, 2016
84. Goodship THJ, Pinto F, Weston-Davies WH, Silva J, Nishimura JJ, Nunn MA, Mackie I, Machin SJ, Palm L, Pryce JW, Chiesa R, Amrolia P, Veys P: Use of the complement inhibitor C5aR1 inhibitor eculizumab to treat HSCT-associated TMA. *Blood Adv* 1: 1254–1258, 2017
85. Hematology Times Staff: Drug Receives Breakthrough Designation for HSCT-TMA, 2018. Available at: <https://www.mdedge.com/hematology-oncology/article/184982/transplantation/drug-receives-breakthrough-designation-hsct-tma>. Accessed September 15, 2019
86. Schrier RW, Parikh CR: Comparison of renal injury in myeloablative autologous, myeloablative allogeneic and non-myeloablative allogeneic hematopoietic cell transplantation. *Nephrol Dial Transplant* 20: 678–683, 2005



87. Slavin S, Nagler A, Naparstek E, Kapelushnik Y, Aker M, Cividalli G, Varadi G, Kirschbaum M, Ackerstein A, Samuel S, Amar A, Brautbar C, Ben-Tal O, Eldor A, Or R: Nonmyeloablative stem cell transplantation and cell therapy as an alternative to conventional bone marrow transplantation with lethal cytoreduction for the treatment of malignant and nonmalignant hematologic diseases. *Blood* 91: 756–763, 1998
88. de Souza JA, Saliba RM, Patah P, Rondon G, Ribeiro R, de Padua Silva L, Qazilbash MH, Hosing C, Popat U, Efebera Y, Champlin RE, de Lima M: Moderate renal function impairment does not affect outcomes of reduced-intensity conditioning with fludarabine and melphalan for allogeneic hematopoietic stem cell transplantation. *Biol Blood Marrow Transplant* 15: 1094–1099, 2009
89. Kersting S, Verdonck LF: Successful outcome after non-myeloablative allogeneic hematopoietic stem cell transplantation in patients with renal dysfunction. *Biol Blood Marrow Transplant* 14: 1312–1316, 2008
90. Hingorani S: Chronic kidney disease in long-term survivors of hematopoietic cell transplantation: Epidemiology, pathogenesis, and treatment. *J Am Soc Nephrol* 17: 1995–2005, 2006
91. Kal HB, van Kempen-Harteveld ML: Renal dysfunction after total body irradiation: Dose-effect relationship. *Int J Radiat Oncol Biol Phys* 65: 1228–1232, 2006
92. Ellis MJ, Parikh CR, Inrig JK, Kanbay M, Patel UD: Chronic kidney disease after hematopoietic cell transplantation: A systematic review. *Am J Transplant* 8: 2378–2390, 2008
93. Cohen EP, Drobyski WR, Moulder JE: Significant increase in end-stage renal disease after hematopoietic stem cell transplantation. *Bone Marrow Transplant* 39: 571–572, 2007
94. Ando M, Ohashi K, Akiyama H, Sakamaki H, Morito T, Tsuchiya K, Nitta K: Chronic kidney disease in long-term survivors of myeloablative allogeneic haematopoietic cell transplantation: Prevalence and risk factors. *Nephrol Dial Transplant* 25: 278–282, 2010
95. Shimoi T, Ando M, Munakata W, Kobayashi T, Kakihana K, Ohashi K, Akiyama H, Sakamaki H: The significant impact of acute kidney injury on CKD in patients who survived over 10 years after myeloablative allogeneic SCT. *Bone Marrow Transplant* 48: 80–84, 2013
96. Singh N, McNeely J, Parikh S, Bhinder A, Rovin BH, Shidham G: Kidney complications of hematopoietic stem cell transplantation. *Am J Kidney Dis* 61: 809–821, 2013
97. Lawton CA, Cohen EP, Barber-Derus SW, Murray KJ, Ash RC, Casper JT, Moulder JE: Late renal dysfunction in adult survivors of bone marrow transplantation. *Cancer* 67: 2795–2800, 1991
98. Leblond V, Sutton L, Jacquaud C, Item C, Sadoun R, Jaudon MC, Raymond F, Jacobs C, Deray G: Evaluation of renal function in 60 long-term survivors of bone marrow transplantation. *J Am Soc Nephrol* 6: 1661–1665, 1995
99. Borg M, Hughes T, Horvath N, Rice M, Thomas AC: Renal toxicity after total body irradiation. *Int J Radiat Oncol Biol Phys* 54: 1165–1173, 2002
100. Humphreys BD, Soiffer RJ, Magee CC: Renal failure associated with cancer and its treatment: An update. *J Am Soc Nephrol* 16: 151–161, 2005
101. Cohen EP, Lawton CA, Moulder JE: Bone marrow transplant nephropathy: Radiation nephritis revisited. *Nephron* 70: 217–222, 1995
102. Hingorani SR, Seidel K, Lindner A, Aneja T, Schoch G, McDonald G: Albuminuria in hematopoietic cell transplantation patients: Prevalence, clinical associations, and impact on survival. *Biol Blood Marrow Transplant* 14: 1365–1372, 2008
103. Momoki K, Yamaguchi T, Ohashi K, Ando M, Nitta K: Emergence of dipstick proteinuria predicts overt nephropathy in patients following stem cell transplantation. *Nephron* 135: 31–38, 2017

Published online ahead of print. Publication date available at [www.cjasn.org](http://www.cjasn.org).