

## Drug-Induced Acute Interstitial Nephritis

Dennis G. Moledina\* and Mark A. Perazella\*\*

*Clin J Am Soc Nephrol* 12: 2046–2049, 2017. doi: <https://doi.org/10.2215/CJN.07630717>

Drug-induced acute interstitial nephritis (DI-AIN) is a common cause of AKI, affecting about 20% of patients with unexplained AKI, and leads to CKD and ESRD (1). Although any drug can potentially cause DI-AIN, antibiotics, non-steroidal anti-inflammatory drugs, and proton pump inhibitors, are the most frequent offenders (1). Diagnosis of DI-AIN is obvious when the classic triad of rash, fever, and eosinophilia occur within a few days of the initiation of a culprit drug. However, these findings occur in <10% of patients, and the onset of DI-AIN may be delayed by weeks or months after drug initiation (2). Moreover, only half of all patients with biopsy-proven DI-AIN present with AKI, whereas the rest have a slow, progressive loss of kidney function not meeting the AKI criteria (3). Urinary abnormalities such as eosinophiluria, pyuria, and white blood cell (WBC) casts, considered typical of DI-AIN, are also unreliable (2). Diagnosis of DI-AIN relies on maintaining a high index of suspicion in those at risk for this disease and obtaining a kidney biopsy to establish the diagnosis.

As challenging as diagnosing DI-AIN is for clinicians, formulating an evidence-based treatment plan is equally difficult. Given the underlying immune mechanism of DI-AIN, corticosteroid administration has been considered the treatment of choice along with early withdrawal of the culprit drug. However, there is no randomized controlled trial of corticosteroids in DI-AIN. The literature is fraught with case reports, case series, and retrospective studies examining corticosteroid therapy for this inflammatory kidney lesion (4–8). Review of this literature reveals that there is no definitive answer for DI-AIN treatment except that early drug withdrawal is imperative. We present two patients to illustrate the frustrating nature of this issue and offer DI-AIN treatment recommendations on the basis of current literature.

### Patient 1

A 25-year-old woman with acute pyelonephritis from *Escherichia coli* was treated with oral double-strength trimethoprim/sulfamethoxazole. On day 11 of 14 of antibiotic treatment, the patient developed a maculopapular rash, low-grade fever, and eosinophilia. Serum creatinine (SCr) was 1.9 mg/dl (baseline SCr 0.7 mg/dl). Urine sediment microscopy revealed 1–3 WBC casts per low power field (LPF). Acute

interstitial nephritis (AIN) due to sulfamethoxazole was presumed and the drug was discontinued. Treatment was completed with 3 days of daily levofloxacin. Over the next week, her symptoms resolved, and SCr returned to baseline.

### Patient 2

A 69-year-old man with coronary artery disease, atrial fibrillation, and hypertension was admitted to the intensive care unit for pneumonia complicated by hypotension. After clinical improvement with ceftriaxone and azithromycin therapy, he was transferred to a medical floor. On day nine, the nephrology service was consulted to evaluate his SCr rise from 1.2 to 2.1 mg/dl. Urine sediment microscopy demonstrated 5–10 isomorphic red blood cells per high power field (HPF), 10–15 WBCs per HPF, 3–5 renal tubular epithelial cells per HPF, and 1–3 granular casts per LPF. Acute tubular injury, acute infectious GN, and DI-AIN were considered in the differential diagnosis of AKI. Antibiotics were discontinued for clinical suspicion of DI-AIN. However, because the SCr continued to rise to 5.7 mg/dl on day 13, kidney biopsy was performed. Light microscopy revealed diffuse AIN, acute tubular injury, and 30% interstitial fibrosis. Ceftriaxone was the most likely culprit. After consultation with infectious diseases specialists, therapy with intravenous methylprednisolone 500 mg daily for 3 days was initiated, followed by oral prednisone, 60 mg daily for 4 weeks with subsequent taper. Two weeks after starting therapy, a gradual decrease in SCr was observed. At 6-month follow-up, the patient's SCr was 1.9 mg/dl.

### Discussion

These patients illustrate two important features of DI-AIN: (1) the varied clinical presentation, and (2) the divergent response to culprit drug discontinuation alone. The first patient developed classic “allergic DI-AIN” with systemic and kidney manifestations, whereas the second patient had only kidney manifestations that did not allow DI-AIN to be easily differentiated from other causes of AKI. Furthermore, the first patient had resolution of DI-AIN solely with drug discontinuation, whereas the second patient had worsening AKI, presumably from ongoing tubulointerstitial inflammation and injury despite drug discontinuation.

\*Section of Nephrology, Yale University School of Medicine, New Haven, Connecticut; and †Department of Medicine, Veterans Administration Medical Center, West Haven, Connecticut

**Correspondence:** Dr. Mark A. Perazella, Section of Nephrology, Yale University School of Medicine, BB 114, 330 Cedar Street, New Haven, CT 06520-8029. Email: [mark.perazella@yale.edu](mailto:mark.perazella@yale.edu)

In response to worsening AKI, corticosteroid therapy was initiated and kidney function eventually improved (albeit incompletely) over the next several weeks.

An obvious first step in the treatment of DI-AIN is early identification and discontinuation of the culprit drug, which should not be delayed while a kidney biopsy is being contemplated. Longer duration of exposure to the culprit drug is associated with worse chance of recovery of kidney function (6). After this, the therapeutic approach becomes less clear and somewhat controversial. As noted for the above patients, there are a number of unanswered questions regarding the management of DI-AIN, including the role of a kidney biopsy to establish the diagnosis and the utility of corticosteroids in its treatment. In this article, we provide answers to these questions on the basis of our interpretation of the literature and clinical experience.

### Are Corticosteroids Effective for Treatment of DI-AIN?

Evidence for the effectiveness of corticosteroids is derived from retrospective studies, which have several limitations. Firstly, the decision to use the drugs in these studies was made by treating physicians with intimate knowledge of each patient. Only those patients expected to benefit from corticosteroid therapy are given these agents. Because those with higher degrees of fibrosis are less likely to recover their kidney function completely, these patients are often not exposed to corticosteroid therapy. On the other hand, those with mild DI-AIN, expected to recover solely with drug discontinuation, are not administered corticosteroids. Secondly, many centers in the United States, including our own, administer corticosteroids to nearly all eligible patients with DI-AIN as a standard of care, which makes it harder to compare the effectiveness of corticosteroids in DI-AIN from retrospective analysis. For example, in the study by Muriithi *et al.* (6), 87% of patients with DI-AIN were treated with corticosteroids. As a result, retrospective evaluation of the effect of corticosteroid use on long-term kidney function outside of a randomized setting is highly confounded.

Within these limitations, several retrospective studies attempted to examine the effectiveness of corticosteroids in patients with DI-AIN (Table 1). Valluri *et al.* found no improvement in kidney function in those treated with corticosteroids as compared with those who were managed conservatively; however, the corticosteroid treated group had significantly worse kidney function at the time of biopsy (8). Similar findings were observed by Clarkson *et al.* (4) where corticosteroids were initiated much later after diagnosis. However, these observations were contradicted by other studies where kidney function and histologic findings at biopsy were comparable between corticosteroid-treated and conservatively managed patients, and corticosteroid therapy was rapidly initiated after diagnosis. For example, in a study of 158 patients, corticosteroid-treated patients with DI-AIN had better kidney function at 2 years as compared with those who did not receive these drugs (9). Similar outcomes were observed in studies by Raza *et al.* (7) and González *et al.* (5). Thus, the weight of available evidence appears to support a potential benefit of corticosteroid administration on

**Table 1. Studies examining corticosteroid therapy in acute interstitial nephritis**

Author, Yr (ref)	Sample size		Peak SCr, mg/dl		Final SCr, mg/dl		Follow-Up, Mo	Comment
	Steroid	No Steroid	Steroid	No Steroid	Steroid	No Steroid		
Clarkson <i>et al.</i> 2004 (4)	26	16	7.9	6.1	1.6	1.6	12	Patients received steroids late after diagnosis (median delay >3 wk). Steroid-treated patients with complete recovery had shorter delay to steroids (13 d) as compared with those without complete recovery (34 d). Improved GFR with steroid versus control ( $P<0.05$ ). No difference in kidney outcomes on the basis of steroid timing.
González <i>et al.</i> 2008 (5)	52	9	5.9	4.9	2.1	3.7	19	
Raza <i>et al.</i> 2012 (7)	37	12	6.5	5.2	2.8	3.4	19	Steroid-treated patients had superior kidney outcomes with early versus late steroid therapy.
Muriithi <i>et al.</i> 2014 (6)	83	12	3.0	4.5	1.4	1.5	6	
Valluri <i>et al.</i> 2015 (8)	73	51	4.03	3.16	NR	NR	12	Worse kidney function in steroid-treated versus control at biopsy (SCr 4.2 versus 3.3 mg/dl). Steroid-treated patients had complete recovery (48%) versus control group (41%); final SCr not different at 1 yr.
Predecki <i>et al.</i> 2016 (9)	158	29	20.5 ml/min (eGFR)	25 ml/min (eGFR)	43 ml/min (eGFR)	24 ml/min (eGFR)	24	

SCr, serum creatinine concentration; NR, not reported.

recovery of kidney function and possible prevention of long-term dialysis. The same approach applies to drug-induced granulomatous AIN once an infectious cause has been excluded.

### Is a Kidney Biopsy Required to Document DI-AIN before Corticosteroid Therapy?

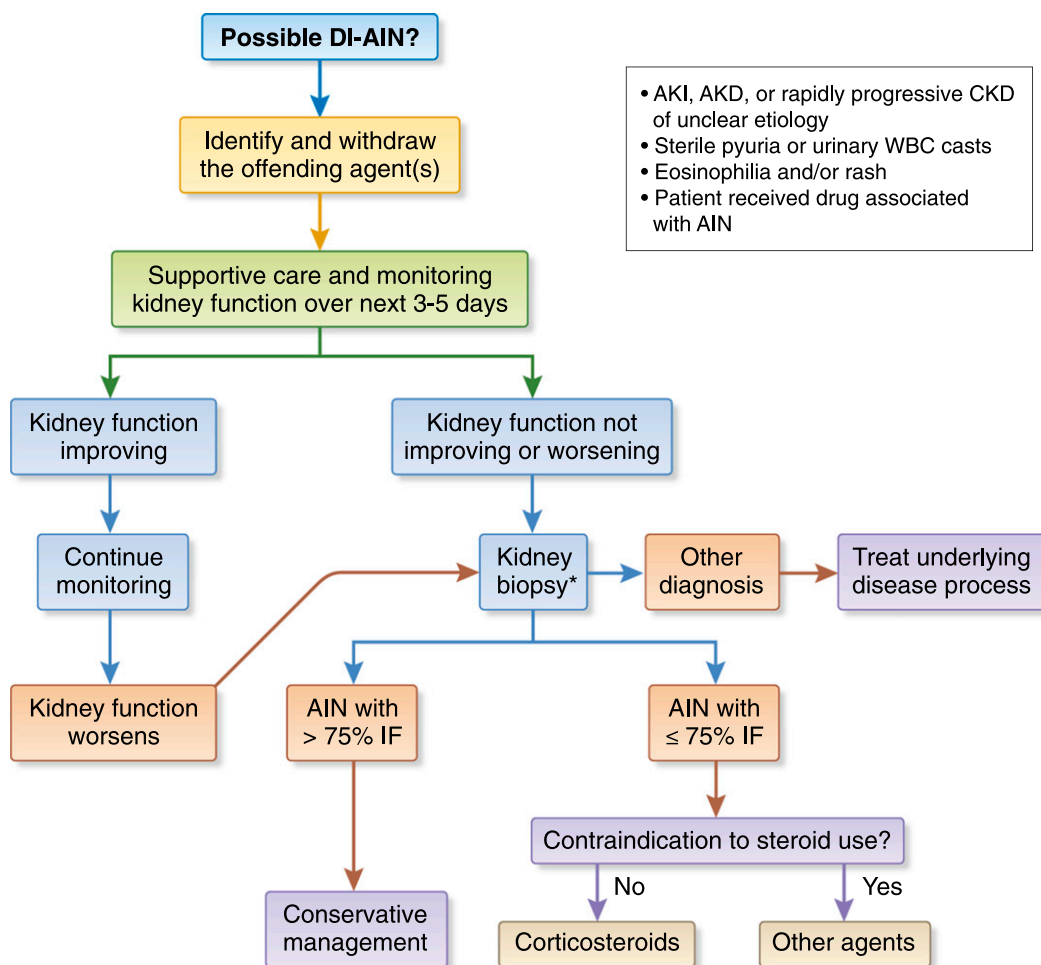
Clinical diagnosis of DI-AIN is challenging without a kidney biopsy. In fact, one study found that only a quarter of PPI-mediated DI-AIN cases were suspected before biopsy (10). Thus, it is desirable to document the presence of DI-AIN with a biopsy before exposing patients to corticosteroids, which carry risks even with short-term use (11). Moreover, a kidney biopsy also provides prognostic information such as the degree of interstitial fibrosis, tubular atrophy, and glomerular sclerosis, which can guide treatment decisions. For example, it would be reasonable to avoid corticosteroid therapy in patients with >75% interstitial fibrosis/tubular atrophy and significant glomerulosclerosis. As we will discuss below, early initiation of corticosteroids is

associated with better long-term kidney function. Thus, a biopsy should be performed as soon as possible in those suspected to have DI-AIN, or those with unexplained AKI to establish (or rule out) DI-AIN diagnosis.

In patients where a biopsy cannot be performed and DI-AIN is the top diagnosis, a trial of empirical corticosteroid therapy may be considered on a patient-by-patient basis. Unfortunately, there is currently no noninvasive test that reliably diagnoses DI-AIN.

### Who Should Get Steroids and How Do We Identify This Group?

Identifying patients with DI-AIN who should be given a trial of steroids requires balancing potential benefit of kidney function recovery with the harms of high-dose corticosteroids. The harms of short-term corticosteroid use include poor glycemic control in diabetic individuals, and increased infection risk (11). Muriithi *et al.* (6) found that increased amounts of interstitial fibrosis/tubular atrophy



**Figure 1.** | Algorithm for management of drug-induced acute interstitial nephritis. \*In patients where kidney biopsy cannot be performed, the decision to start a trial of empirical steroids can be considered on a patient-by-patient basis. An ultrasound showing small kidneys usually indicates advanced fibrosis and unlikely benefit from corticosteroid use. Unfortunately, there are currently no tests that can be recommended to replace biopsy to establish DI-AIN diagnosis. AIN, acute interstitial nephritis; AKD, acute kidney disease; AKI, acute kidney injury; DI-AIN, drug-induced acute interstitial nephritis; IF, interstitial fibrosis; WBC, white blood cell.

and smaller kidneys on ultrasound correlated with poor response to steroids. Thus, corticosteroids should be avoided in those with advanced fibrosis, particularly in patients with diabetes with labile blood glucose control. In patients with active infection, discussing corticosteroid therapy with an infectious disease consultant is an important step before initiating treatment.

### What Is the Optimal Timing of Steroid Therapy in Patients?

Studies suggest that early corticosteroid initiation is associated with better outcomes. For example, two studies reported lower rates of kidney function recovery in those with longer time from onset of DI-AIN to starting steroids (5,6). Thus, if corticosteroid therapy is considered, it should be initiated early after the diagnosis is established, preferably in 1–2 weeks.

### What Regimen and for What Duration Should Corticosteroids Be Administered for DI-AIN?

DI-AIN studies have used either 250–500 mg intravenous methylprednisolone followed by 1 mg/kg per day of oral prednisone (5) or 1 mg/kg per day of oral prednisone without intravenous therapy (10). Regardless of the initiation dose, 1 mg/kg per day of prednisone should be continued for approximately 1–1.5 months because most patients recover their kidney function within this time frame (5). A trial of corticosteroids should not be extended beyond 1.5 months in those who fail to show any improvement in kidney function. In patients with improving kidney function who develop adverse effects from corticosteroid therapy, a small case series supports switching to mycophenolate mofetil as a potentially useful alternate therapy (12). Figure 1 outlines our approach to the treatment of patients diagnosed with DI-AIN.

### Disclosures

None.

### References

1. Perazella MA, Markowitz GS: Drug-induced acute interstitial nephritis. *Nat Rev Nephrol* 6: 461–470, 2010
2. Perazella MA: Clinical approach to diagnosing acute and chronic tubulointerstitial disease. *Adv Chronic Kidney Dis* 24: 57–63, 2017
3. Chu R, Li C, Wang S, Zou W, Liu G, Yang L: Assessment of KDIGO definitions in patients with histopathologic evidence of acute renal disease. *Clin J Am Soc Nephrol* 9: 1175–1182, 2014
4. Clarkson MR, Giblin L, O'Connell FP, O'Kelly P, Walshe JJ, Conlon P, O'Meara Y, Dormon A, Campbell E, Donohoe J: Acute interstitial nephritis: Clinical features and response to corticosteroid therapy. *Nephrol Dial Transplant* 19: 2778–2783, 2004
5. González E, Gutiérrez E, Galeano C, Chevia C, de Sequera P, Bernis C, Parra EG, Delgado R, Sanz M, Ortiz M, Goicoechea M, Quereda C, Olea T, Bouarich H, Hernández Y, Segovia B, Praga M; Grupo Madrileño De Nefritis Intersticiales: Early steroid treatment improves the recovery of renal function in patients with drug-induced acute interstitial nephritis. *Kidney Int* 73: 940–946, 2008
6. Muriithi AK, Leung N, Valeri AM, Cornell LD, Sethi S, Fidler ME, Nasr SH: Biopsy-proven acute interstitial nephritis, 1993–2011: A case series. *Am J Kidney Dis* 64: 558–566, 2014
7. Raza MN, Hadid M, Keen CE, Bingham C, Salmon AH: Acute tubulointerstitial nephritis, treatment with steroid and impact on renal outcomes. *Nephrology (Carlton)* 17: 748–753, 2012
8. Valluri A, Hetherington L, Mcquarrie E, Fleming S, Kipgen D, Geddes CC, Mackinnon B, Bell S: Acute tubulointerstitial nephritis in Scotland. *QJM* 108: 527–532, 2015
9. Prendecki M, Tanna A, Salama AD, Tam FW, Cairns T, Taube D, Cook HT, Ashby D, Duncan ND, Pusey CD: Long-term outcome in biopsy-proven acute interstitial nephritis treated with steroids. *Clin Kidney J* 10: 233–239, 2017
10. Muriithi AK, Leung N, Valeri AM, Cornell LD, Sethi S, Fidler ME, Nasr SH: Clinical characteristics, causes and outcomes of acute interstitial nephritis in the elderly. *Kidney Int* 87: 458–464, 2015
11. Waljee AK, Rogers MA, Lin P, Singal AG, Stein JD, Marks RM, Ayanian JZ, Nallamothu BK: Short term use of oral corticosteroids and related harms among adults in the United States: Population based cohort study. *BMJ* 357: j1415, 2017
12. Preddie DC, Markowitz GS, Radhakrishnan J, Nickolas TL, D'Agati VD, Schwimmer JA, Gardenswartz M, Rosen R, Appel GB: Mycophenolate mofetil for the treatment of interstitial nephritis. *Clin J Am Soc Nephrol* 1: 718–722, 2006

Published online ahead of print. Publication date available at [www.cjasn.org](http://www.cjasn.org).