

Sodium Thiosulfate Treatment for Calcific Uremic Arteriopathy in Children and Young Adults

Carlos E. Araya, Robert S. Fennell, Richard E. Neiberger, and Vikas R. Dharnidharka

Division of Pediatric Nephrology, Department of Pediatrics, University of Florida College of Medicine, Gainesville, Florida

In adult patients with ESRD, calcific uremic arteriopathy (CUA) is an uncommon but life-threatening complication. No effective therapy exists, although anecdotal case reports highlight the use of sodium thiosulfate (STS), a calcium-chelating agent with antioxidant properties. CUA is rare in children, and STS use has not been reported. The objective of this study was to determine the influence of STS treatment on three patients with CUA in a pediatric chronic dialysis unit. The patients were between 12 and 21 yr of age; two were male; and primary diagnoses were obstructive uropathy, renal dysplasia, and calcineurin nephrotoxicity. Time from ESRD to CUA diagnosis was 1, 9, and 20 yr. Diagnosis was made by tissue biopsy and three-phase bone scan. Pain was the presenting symptom. Initial treatment included discontinuation of calcitriol and use of non-calcium-based phosphate binders and low-calcium dialysate concentration. STS dosage was 25 g/1.73 m² per dose intravenously after each hemodialysis session. For optimization of removal of calcium deposits, patient three received a combination of STS and continuous venovenous hemofiltration for the first 10 d. All patients demonstrated rapid pain relief. Within weeks, skin induration and joint mobility of the extremities improved. Radiographic evidence of reduction in the calcium deposits occurred within 3 mo of initiation of STS. The only complication was prolonged QT interval in one patient as a result of hypocalcemia, who was resolved by use of a higher dialysate calcium concentration. STS seems well tolerated in children and young adults with CUA and has mild adverse effects. For determination of its efficacy, optimum dosage, duration of therapy, and dialysis modality, controlled trials are needed.

Clin J Am Soc Nephrol 1: 1161–1166, 2006. doi: 10.2215/CJN.01520506

Once considered rare, calcific uremic arteriopathy (CUA) has been reported to occur in as high as 4% of dialysis populations (1). This often life-threatening condition, also known as calciphylaxis, represents a small-vessel vasculopathy that is characterized by intimal proliferation, endovascular fibrosis, and medial wall calcification, which result in ischemia and necrosis most commonly of the skin and subcutaneous tissues. The cause of CUA is not understood, which makes treatment not only difficult but also empirical. Risk factors, including disorders of calcium-phosphate homeostasis and treatment with parathyroidectomy and non-calcium-based phosphate binders and use of low-calcium dialysate, have been the focus of study in patients with ESRD. However, the overall benefit of these strategies in most patients still is low, and the mortality from CUA remains elevated (1).

Intravenous sodium thiosulfate (STS) has been used successfully in three individual case reports in the treatment of hemodialysis and peritoneal dialysis patients with severe CUA (Table 1) (2–4). STS is an antioxidant agent and a chelator of cations (e.g., calcium) and initially was used as an antidote for

cyanide and cisplatin toxicity. The antioxidant properties may help restore endothelial cell dysfunction and promote vasodilation. Furthermore, the enhanced aqueous solubility of calcium thiosulfate allows for successful mobilization and clearance of the vascular and soft tissue calcium deposits (5). In children, the incidence of CUA is not known, and there are very few reported cases (6). We report our experience in the use of STS to treat CUA in three patients with ESRD in our chronic pediatric hemodialysis unit. To our knowledge, there are no published case series on the treatment of CUA with STS or any reports involving pediatric or young adult patients.

Materials and Methods

CUA was diagnosed histologically in one of the patients and confirmed radiologically with nuclear medicine bone scan examination in all three patients. STS 25% solution (American Reagent Laboratories, Shirley, NY) was administered at a dosage of 25 g/1.73 m² per dose over 60 min after each hemodialysis session three times per week. Hemodialysis was performed using a high-flux polysulfone hemodialyzer (Fresenius, Lexington, MA). One of the patients received initial therapy with STS and continuous venovenous hemofiltration (CVVH) using a Diapact device (B. Braun, Bethlehem, PA) for 10 d followed by daily hemodialysis for 15 d.

Patient 1

A 21-yr-old white man developed ESRD at the age of 5 mo as a result of bilateral multicystic dysplastic kidney disease. He had received one living-related and two deceased-donor kidney transplants at 27 mo, 7 yr, and 8 yr of age, respectively. The initial transplant failed after 5 yr

Received May 5, 2006. Accepted June 28, 2006.

Published online ahead of print. Publication date available at www.cjasn.org.

Address correspondence to: Dr. Vikas R. Dharnidharka, Division of Pediatric Nephrology, University of Florida Health Science Center, 1600 SW Archer Road, PO Box 100296, Gainesville, FL 32610-0296. Phone 352-392-4434; Fax: 352-392-7107; E-mail: vikasmd@peds.ufl.edu

Table 1. Review of reports describing the use of STS for the treatment of CUA^a

Authors	Age (yr)	Presenting Symptoms	Renal Replacement Modality	Treatment	Results
Cicone <i>et al.</i> (2)	69	Painful indurated subcutaneous plaques in lower extremities	Peritoneal dialysis	Discontinuation of calcitriol, use of NCPB, oral corticosteroids, STS	Pain relief, less induration
Guerra <i>et al.</i> (3)	46	Tender, nodular, and necrotic lower extremity lesions	CVVH followed by hemodialysis	Use of NCPB, STS	Pain relief, resolution of skin ulcers
Bruculeri <i>et al.</i> (4)	48	Tender subcutaneous nodules and skin ulcers in abdomen, breasts, hips, thighs	Hemodialysis	Discontinuation of calcitriol, increased dialysis frequency, use of NCPB, parathyroidectomy, STS	Regression of skin lesions with wound healing
Araya <i>et al.</i> (this study)	21	Painful indurated subcutaneous plaques in all extremities, lower extremity ulcers	Hemodialysis	Discontinuation of calcitriol, oral corticosteroids, use of NCPB, STS	Pain relief, improvement in skin induration
	12	Bilateral calf and thigh tender induration	Hemodialysis	Discontinuation of calcitriol, use of NCPB, STS	Pain relief, functional improvement with less induration, pain relief
	21	Upper and lower extremity induration with severe contractures of the hands, violaceous lower extremity lesions	CVVH followed by hemodialysis	Discontinuation of calcitriol, use of NCPB, STS	Improvement in skin changes

^aCUA, calcific uremic arteriolopathy; CVVH, continuous venovenous hemofiltration; NCPB, non-calcium-based phosphate binder; STS, sodium thiosulfate.

to chronic allograft nephropathy, the second after 8 d as a result of severe accelerated acute rejection, and the third after 5 d from vascular thrombosis. Initially, the patient received continuous cyclic peritoneal dialysis, but because of recurrent episodes of peritonitis, he was transitioned to hemodialysis. Thrombosis of his arteriovenous fistula prompted a hematologic evaluation for hypercoagulability. A moderately elevated homocysteine level, a low protein C level, and a homozygous defect of methylene tetrahydrofolate reductase were identified, and he was maintained on long-term anticoagulation with warfarin. Because of severe hyperparathyroidism that was refractory to medical therapy, he required parathyroidectomy. Severe hyperphosphatemia was treated with phosphorous diet restriction as well as increasing dosages of the calcium-based binder. However, the calcium-phosphate product reached a level as high as 110 mg²/dl² and was persistently above 55 mg²/dl². After 11 yr on hemodialysis, he began to experience pain and tenderness in both lower extremities, primarily below the knees. The skin of both calves became indurated and hyperpigmented. An area of erythema was noted anteriorly on both legs. No ulcerations were present initially. A skin biopsy revealed increased collagen deposition and thickened subcutaneous fibrous septa with little cellular proliferation most consistent with nephrogenic fibrosing dermopathy. Treatment with daily oral prednisone was ineffective, and the symptoms worsened. During the next few months, he developed an ulcerative lesion on the left lower extremity, and the induration began involving his thighs, forearms, and hands. A radiograph of the forearms demonstrated amorphous calcification in the superficial antecubital regions and linear calcifications affecting the distal left arm, consistent with vessel calcifications. The three-phase bone scan revealed soft tissue accumulation in both lower extremities and forearms, as well as intense uptake in the myocardium, lungs, stomach, and para-articular surfaces, consistent with CUA (Figure 1). Treatment included

intravenous STS, change to a non-calcium-based phosphate binder, and use of low-calcium dialysate. A total of 35 STS treatments were administered. The pain significantly improved, and he required low dosages of conventional analgesics. The ulcerative lesion healed within weeks and no new lesions have developed since the STS treatments were discontinued. A repeat three-phase bone scan 3 mo after diagnosis revealed less intense but still considerable calcifications (Figure 1). However, the restriction of movement had not changed significantly.

Patient 2

A 12-yr-old white boy received a diagnosis *in utero* of posterior urethral valves. A few months after birth, he progressed to ESRD and was initiated on continuous cycling peritoneal dialysis. A deceased-donor kidney transplantation was performed at the age of 3 yr, and his posttransplantation course was complicated by left femoral vein thrombosis, which was treated with warfarin anticoagulation for several years. He also developed Epstein-Barr virus-mediated posttransplantation lymphoproliferative disorder, which responded well to chemotherapy. As a result of chronic allograft nephropathy, hemodialysis was restarted 9 yr later. At this time, he had developed secondary hyperparathyroidism with an intact parathyroid hormone (PTH) level that rose from 129 to 974 pg/ml. By changing to non-calcium-based phosphorus binder and adding an oral calcimimetic agent, the PTH level decreased to 326 pg/ml. He also developed antibody deficiency that required subcutaneous Ig replacement therapy. After 3 mo on hemodialysis, he began to experience bilateral foot pain that failed to respond to oral analgesics. One month later, indurated cutaneous plaques were noted on both legs, and they progressed to involve most of the left calf and thigh, giving it a woody feel. The area was tender and slightly hyperpigmented, and the patient had significant pain on ambulation

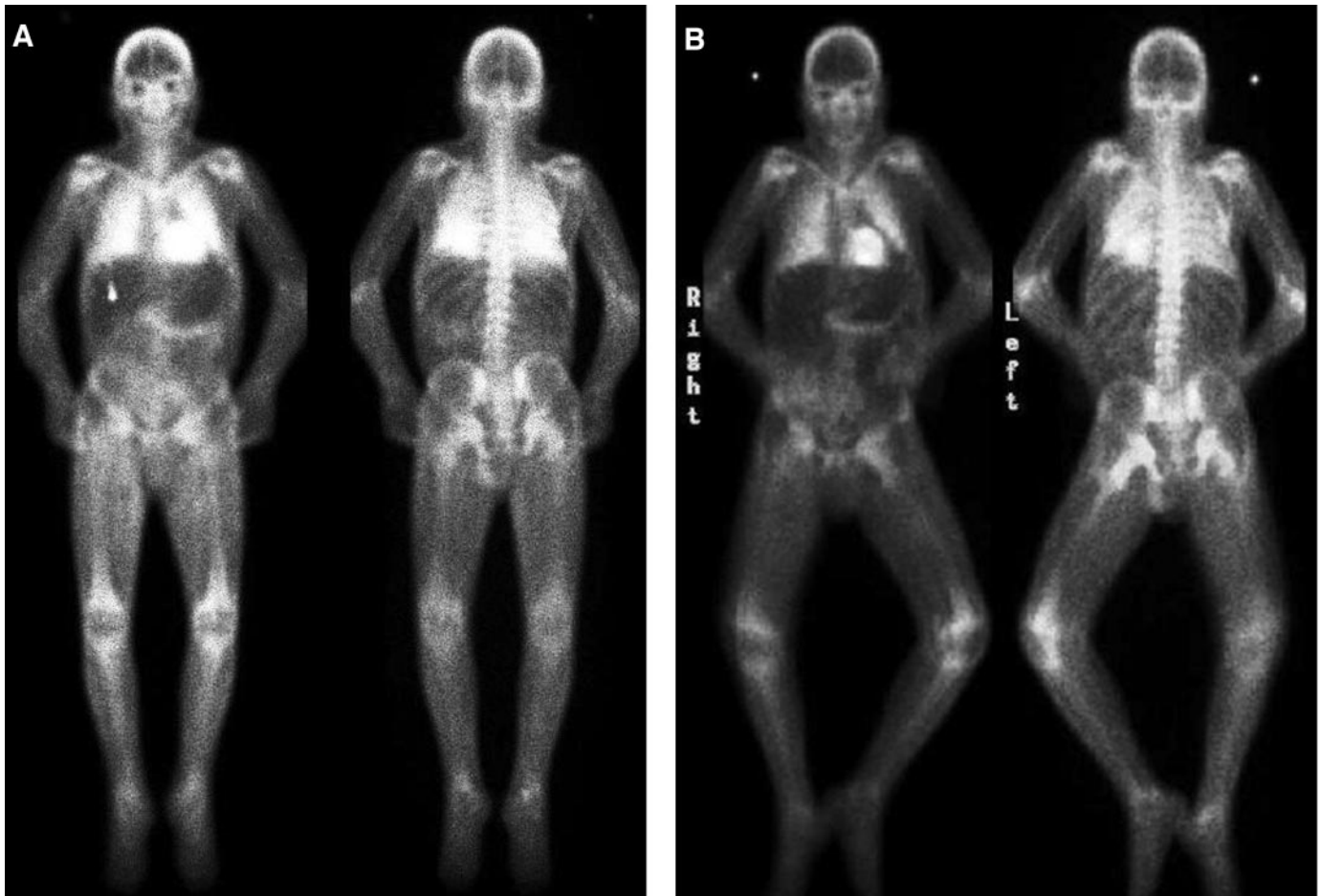


Figure 1. (A) Initial three-phase bone scan demonstrating soft tissue accumulation in thighs, distal femur, proximal tibia, and forearms. There is intense uptake in the myocardium and early accumulation in the lungs. (B) Three months later, the calcium deposition in the thighs and forearms is less significant. However, there still is calcification in the heart, lungs, and para-articular surfaces.

that limited his daily activities. Biopsy of the left calf and thigh revealed fat necrosis, septal fibroplasia, and focal interstitial as well as arterial wall calcification favoring the diagnosis of CUA. The three-phase bone scan demonstrated increased uptake along the soft tissue and skin surface of both legs but worse on the left (Figure 2). Intravenous STS was initiated as well as use of low-calcium dialysate concentration of 1.5 mEq/L. His ionized calcium decreased to 0.88 mmol/L, and he developed prolonged QT syndrome, which resolved after correction of the hypocalcemia. Clinically, the patient reported less pain on ambulation and no need for analgesics, and repeat bone scans 6 and 9 mo later documented an improvement, with the latter showing only subtle changes of CUA on both calves (Figure 2). The indurated plaques decreased in size and intensity, although they did not disappear. The STS treatments were discontinued once he was able to ambulate free of pain. He received a total of 92 treatments.

Patient 3

A 21-yr-old white woman with cystic fibrosis had a bilateral lung transplant at the age of 18 yr. She had multiple medical problems, including insulin-dependent diabetes, hypertension, osteoporosis, and recurrent lung infections. Primarily as a result of calcineurin nephrotoxicity, she developed chronic renal failure and required chronic hemodialysis at the age of 20 yr. She developed a superior vena cava

thrombosis secondary to placement of a central venous catheter, which required anticoagulation initially with heparin and later warfarin. Construction of an arteriovenous fistula proved difficult, and the patient was noted to have very poor wound healing. Further evaluation for a hypercoagulable condition did not yield any abnormalities. She received hemodialysis at an outside institution but had multiple hospitalizations at our center as a result of the development of bronchiolitis obliterans syndrome. She was malnourished and had hypoalbuminemia. Her degree of secondary hyperparathyroidism was mild with a highest intact PTH of 220 pg/ml. The calcium-phosphate product mostly was below $55 \text{ mg}^2/\text{dl}^2$, and she required calcium carbonate only intermittently. The patient began experiencing pain in the hands, back, hips, and legs. During one of the hospitalizations, she was noted to have hard, tender subcutaneous plaques on the lower extremities and skin induration with contractures of the hands. The pain was constant and required increasing dosages of analgesics and eventually opiates intravenously. The skin was not erythematous, but some of the lesions developed a violaceous color during the subsequent weeks; however, no ulcers were noted. A biopsy was not done because of the history of poor wound healing. The three-phase bone scan revealed active CUA in both lower extremities and forearms. There also were changes of metastatic calcification in the lungs, myocardium, and kidneys. Because the symptoms were so intense and the skin lesions were progressing, we

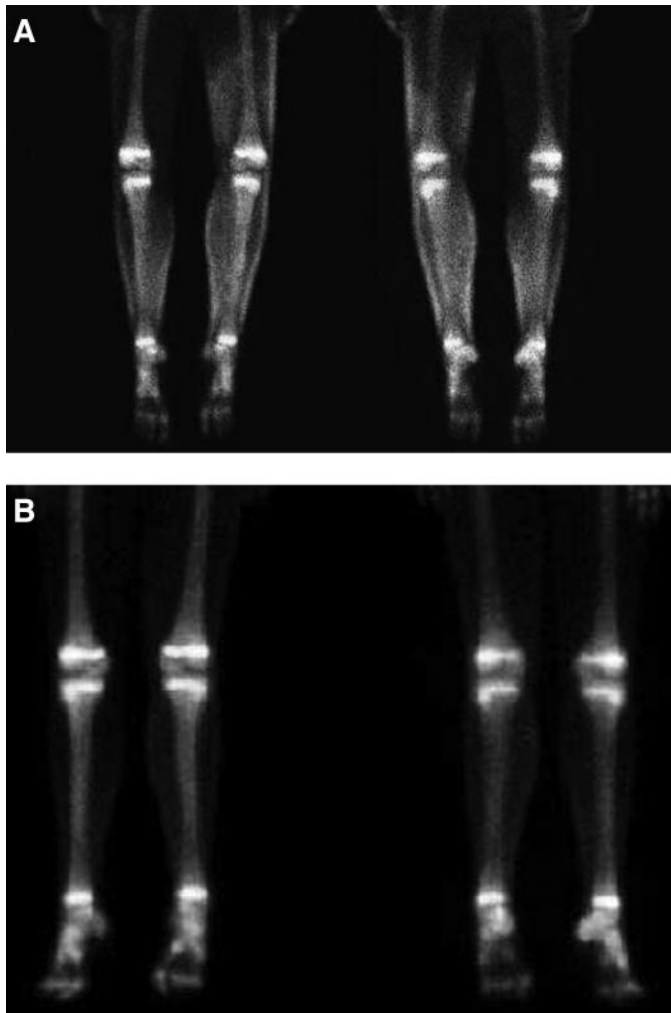


Figure 2. (A) There is abnormal soft tissue activity in the skin surface of both lower legs, consistent with calcific uremic arteriopathy. The changes are worse on the left as it extends from midhigh. (B) Nine months later, there is very slight subcutaneous uptake diffusely in the right calf only.

initiated therapy with CVVH and STS intravenously every other day for a total of 10 d followed by daily hemodialysis for 15 d. The pain dramatically improved within 24 h, and we were able to titrate and eventually discontinue the intravenous opiates. We then resumed hemodialysis three times a week followed by a total of 40 STS infusions. The skin was softer and less tender, and no ulcers developed. The joint mobility of the hands slowly improved but continued to remain restricted. Three months later, a repeat bone scan demonstrated less intense uptake of the radiotracer in the subcutaneous tissues without changes in the lungs, myocardium, and kidneys.

Discussion

The name *calciophylaxis* first was used to describe the possible mechanisms involved in organ and soft tissue calcification. In rodents, sensitization with different forms of vitamin D, PTH, and high-calcium and -phosphorous diet followed by a challenge with other factors (including iron, steroids, egg albumin, and trauma) resulted first in inflammation and, later, calcification (7). This concept then was contemplated to occur in pa-

tients who were on dialysis and developed extraskeletal calcifications and panniculitis, described a few years later (8,9). Although this process is not IgE mediated, the name *calciophylaxis* is used commonly even though other, more appropriate terms, including CUA or obliterative calcific vasculopathy, have been proposed. We have preferred to use the term CUA throughout this article.

Histologically, the most characteristic lesion is intimal proliferation and endovascular calcification with fibrosis, primarily involving the small arterioles and venules (10). Although arteriole medial wall calcification is common, it may not be as prominent in some cases. This process leads to the formation of painful subcutaneous nodules and dense plaques with an erythematous or violaceous color that may progress to necrotizing, nonhealing ulcers. The ulcerative lesions become infected, causing septicemia and death. In patients with renal disease, the lesions can be proximal (involving abdomen, thighs, and buttocks) or distal (primarily involving the calves), with the latter having a better prognosis (11). To avoid the introduction of nonhealing wounds, not all cases of *calciophylaxis* undergo biopsy. Also, a single biopsy may be negative or unequivocal in the presence of CUA (1). A bone scan is a noninvasive way to diagnose and monitor the progression of CUA and in some reports has been found to have very high sensitivity (1). Other investigators believe that CUA is diagnosed best by histopathology (12). In patient 1, the initial skin biopsy findings were consistent with nephrogenic fibrosing dermopathy (NFD), another rare condition that has been reported in one other patient to coexist with CUA (13). NFD and CUA thus may represent different parts of the same disease spectrum. Before the diagnosis of CUA, our group published the skin findings in this patient as a case of NFD in pediatrics (14). STS therapy was not administered in this patient until the diagnosis of CUA was established.

Because the mineral that is deposited in these lesions is composed of calcium phosphate (15), attention has been given to disturbances of calcium and phosphorus in the development of CUA. A review of case-control series in adult patients demonstrated that hyperphosphatemia but not hypercalcemia or hyperparathyroidism was a risk factor in the development of CUA (16). Two of our patients had significant elevations in the calcium-phosphate product primarily as a result of high phosphorus levels, whereas patient 3 had primarily low phosphorus levels. However, other risk factors, including female gender, white race, hypoalbuminemia, and warfarin use, were present in this patient as well. A recent hypothesis suggested that in these patients, vascular smooth muscle cells transform into osteoblast-like cells, which lay down a bone matrix of type I collagen and noncollagenous proteins. This framework acts as a nidus for mineralization, which results in calcification of the vessel and subsequent ischemia (16). Although the exact role of calcium in the pathogenesis of CUA is not clear, therapies for CUA have included parathyroidectomy, use of non-calcium-containing phosphate binders, avoidance of administration of vitamin D analogs, and use of low-calcium dialysate for patients who are on intermittent hemodialysis.

The beneficial effects of STS are thought to be due in part to

the enhanced solubility of calcium deposits in aqueous solution. Initial experiments by Yatzidis (17) demonstrated that calcium thiosulfate is 250, 1000, 3600, and 100,000 times more soluble in aqueous solution than calcium sulfate, citrate, phosphate, and oxalate, respectively. Hence, the administration of STS in CUA could facilitate the mobilization of calcium from the affected vessels. STS has a small molecular weight of 248 ($\text{Na}_2\text{S}_2\text{O}_3$) and in patients with normal renal function has a serum half-life of 15 min. Animal data, using normal and anuric mongrel dogs, demonstrated that STS distributes rapidly throughout the extracellular space (18). During renal failure, its volume of distribution doubled and the metabolic clearance rate decreased drastically. In the normal animals, STS had a half-life of 46.8 min and >98% was cleared renally. However, in the anuric dogs the half-life was 239 min and STS elimination was primarily through the biliary system. In six healthy humans, the average volume of distribution of STS was found to be 12.2 L (167 ml/kg), whereas in edematous individuals, it was 18.2 L (240 ml/kg) (19). Bruccleri *et al.* (4) measured serum STS concentrations in a patient with ESRD 15 min after infusion, before hemodialysis (52 h after administration) and after a 4-h hemodialysis session. The recorded STS levels were 110, 1.2, and 0 $\mu\text{g}/\text{ml}$, respectively, with a calculated half-life of 478 min. The investigators concluded that STS probably was eliminated *via* biliary secretion. Consequently, we found it reasonable that all of our patients receive the STS infusion after hemodialysis, 3 times per week. Pharmacokinetic data on STS during other forms of renal replacement therapy, including peritoneal dialysis, are lacking.

The successful use of this relatively nontoxic substance has been reported as adjuvant treatment of several conditions involving disorders of calcium homeostasis. Yatzidis (17) described its benefits by decreasing the rate of new stone development in 34 patients with recurrent calcium urolithiasis. Prompted by these excellent results, intravenous STS was administered after hemodialysis to three patients with ESRD and tumoral calcinosis for a period of 6 to 12 mo. Two of the patients had regression of the calcified mass as well as improved motility of the affected joints (20). STS was given for a period of 9 yr to a patient with nephrocalcinosis as a result of renal tubular acidosis type 1 (21). There was no further deterioration of his condition, and the discontinuation of the medication was accompanied by recurrence of renal colic. Cicone *et al.* (2) were the first to report the benefits of STS in one peritoneal dialysis patient with CUA. They noted significant pain relief as well as reduction in the size and the induration of the subcutaneous plaques after a total of 8 mo of treatment. In two patients with severe ulcerative lesions, the use of STS was associated with reduction in pain, reduced inflammation, and improved healing (3,4). One of the patients received concomitant therapy with CVVH in an attempt to maintain a constant state of mild hypocalcemia and optimize removal (3). The only noted adverse effects during the treatment period in two of the patients were mild nausea and vomiting and metabolic acidosis.

Because of the rapid progression of symptoms, we opted to use CVVH and STS in one of our patients. The other two

patients received STS after each hemodialysis session. In our experience as well as that of others, the most dramatic change was that of pain relief. This relief was noted in all patients within the first days after initiation of treatment. The mechanism for pain relief has been hypothesized to be due to the antioxidant properties of STS, which by restoring endothelial function can enhance endothelial nitric oxide production, promoting vasodilation and reducing pain (5). In our patients, the subcutaneous plaques, although still present, were reduced in size and became softer and less tender within weeks. Radiologic evidence of decreased calcification also was noted. However, only one of the patients had significant functional improvement in the mobility of the affected areas.

Conclusion

STS has not been proved by itself to resolve CUA, and in our experience, we cannot establish the relative contribution and the importance of each of the interventions (use of low-calcium dialysate, non-calcium-containing phosphate binders, and STS). However, in our patients, we believe that the rapid improvement in symptoms was due to the administration of intravenous STS. Still, CUA continues to be a devastating condition, particularly in dialysis patients, and the optimum treatment remains unclear. Although further studies are needed to determine its kinetics, optimum dosage, and duration of treatment, intravenous STS seems beneficial, has mild adverse effects, and is well tolerated in children and young adults with CUA.

Acknowledgments

This work was presented at the 26th Annual Dialysis Conference; February 26 to 28, 2006; San Francisco, CA.

References

1. Fine A, Zacharias J: Calciphylaxis is usually non-ulcerating: Risk factors, outcome and therapy. *Kidney Int* 61: 2210–2217, 2002
2. Cicone JS, Petronis JB, Embert CD, Spector DA: Successful treatment of calciphylaxis with intravenous sodium thiosulfate. *Am J Kidney Dis* 43: 1104–1108, 2004
3. Guerra G, Shah RC, Ross EA: Rapid resolution of calciphylaxis with intravenous sodium thiosulfate and continuous venovenous haemofiltration using low calcium replacement fluid: Case report. *Nephrol Dial Transplant* 20: 1260–1262, 2005
4. Bruccleri M, Cheigh J, Bauer G, Serur D: Long-term intravenous sodium thiosulfate in the treatment of a patient with calciphylaxis. *Semin Dial* 18: 431–434, 2005
5. Hayden MR, Tyagi SC, Kolb L, Sowers JR, Khanna R: Vascular ossification-calcification in metabolic syndrome, type 2 diabetes mellitus, chronic kidney disease, and calciphylaxis-calcific uremic arteriopathy: The emerging role of sodium thiosulfate. *Cardiovasc Diabetol* 4: 4, 2005
6. Imam AA, Mattoo TK, Kapur G, Bloom DA, Valentini RP: Calciphylaxis in pediatric end-stage renal disease. *Pediatr Nephrol* 20: 1776–1780, 2005
7. Selye H, Gabbiani G, Strebel R: *Sensitization to Calciphylaxis*

- by *Endogenous Parathyroid Hormone*, Chicago, University of Chicago Press, 1962, pp 554–558
8. Anderson DC, Stewart WK, Piercy DM: Calcifying panniculitis with fat and skin necrosis in a case of uraemia with autonomous hyperparathyroidism. *Lancet* 2: 323–325, 1968
 9. Parfitt AM: Soft-tissue calcification in uremia. *Arch Intern Med* 124: 544–556, 1969
 10. Essary LR, Wick MR: Cutaneous calciphylaxis. An under-recognized clinicopathologic entity. *Am J Clin Pathol* 113: 280–287, 2000
 11. Hafner J, Keusch G, Wahl C, Sauter B, Hurlimann A, von Weizsacker F, Krayenbuhl M, Biedermann K, Brunner U, Helfenstein U: Uremic small-artery disease with medial calcification and intimal hyperplasia (so-called calciphylaxis): A complication of chronic renal failure and benefit from parathyroidectomy. *J Am Acad Dermatol* 33: 954–962, 1995
 12. Goldsmith DJ: Calcifying panniculitis or 'simple' inflammation? Biopsy is better than a bone scan. *Nephrol Dial Transplant* 12: 2463–2464, 1997
 13. Edsall LC, English JC 3rd, Teague MW, Patterson JW: Calciphylaxis and metastatic calcification associated with nephrogenic fibrosing dermopathy. *J Cutan Pathol* 31: 247–253, 2004
 14. Jain SM, Wesson S, Hassanein A, Canova E, Hoy M, Fennell RS, Dharnidharka VR: Nephrogenic fibrosing dermopathy in pediatric patients. *Pediatr Nephrol* 19: 467–470, 2004
 15. Coates T, Kirkland GS, Dymock RB, Murphy BF, Brealey JK, Mathew TH, Disney AP: Cutaneous necrosis from calcific uremic arteriolopathy. *Am J Kidney Dis* 32: 384–391, 1998
 16. Moe SM, Chen NX: Calciphylaxis and vascular calcification: A continuum of extra-skeletal osteogenesis. *Pediatr Nephrol* 18: 969–975, 2003
 17. Yatzidis H: Successful sodium thiosulphate treatment for recurrent calcium urolithiasis. *Clin Nephrol* 23: 63–67, 1985
 18. Braverman B, Ivankovich AD, Shah G: Thiosulfate pharmacokinetics in normal and anuric dogs. *Proc Soc Exp Biol Med* 170: 273–280, 1982
 19. Cardozo RH, Edelman IS: The volume of distribution of sodium thiosulfate as a measure of the extracellular fluid space. *J Clin Invest* 31: 280–290, 1952
 20. Kyriakopoulos G, Kontogianni K: Sodium thiosulfate treatment of tumoral calcinosis in patients with end-stage renal disease. *Ren Fail* 12: 213–219, 1990
 21. Agroyannis BJ, Koutsikos DK, Tzanatos HA, Konstadinidou IK: Sodium thiosulphate in the treatment of renal tubular acidosis I with nephrocalcinosis. *Scand J Urol Nephrol* 28: 107–108, 1994