

Mycophenolate Mofetil for the Treatment of Interstitial Nephritis

Dean C. Preddie,* Glen S. Markowitz,[†] Jai Radhakrishnan,* Thomas L. Nickolas,* Vivette D. D'Agati,[†] Joshua A. Schwimmer,*[‡] Mark Gardenswartz,[‡] Raquel Rosen,[§] and Gerald B. Appel*

*Department of Medicine/Division of Nephrology and [†]Department of Pathology, Columbia University College of Physicians & Surgeons, and [‡]Department of Medicine/Division of Nephrology, Lenox Hill Hospital, New York, and [§]Department of Medicine/Division of Nephrology, Mary Imogene Bassett Hospital, Cooperstown, New York

Acute interstitial nephritis (AIN) is a clinicopathologic entity that is characterized by acute renal failure and renal biopsy findings of interstitial inflammation and tubulitis. There are multiple causes of AIN, the majority of which appear to respond to immunosuppressive therapy. Corticosteroids are the mainstay of treatment for AIN, but many patients are refractory to or intolerant of treatment or are unable to discontinue therapy without clinical relapse. Herein are reported eight cases of steroid-resistant, biopsy-proven AIN that were treated successfully with mycophenolate mofetil (MMF) at one institution. Patients had a mean decline in serum creatinine from 2.3 to 1.6 mg/dl over a mean of 24.3 mo of treatment. Six of the eight patients had a decline in serum creatinine of at least 0.3 mg/dl, and the remaining two patients had stable renal function during the treatment period. At most recent follow-up, five of the eight patients successfully have discontinued treatment with MMF for a mean of 6.4 mo. MMF was well tolerated by all patients. It is concluded that MMF is a useful therapeutic option for steroid-resistant AIN and may be considered as potential first-line therapy in select populations.

Clin J Am Soc Nephrol 1: 718–722, 2006. doi: 10.2215/CJN.01711105

Acute interstitial nephritis (AIN) is a clinicopathologic entity with a typical clinical presentation of acute renal failure (ARF), sterile leukocyturia, and low-grade proteinuria (1–4). Pathologically, AIN is characterized by acute interstitial inflammation that extends across tubular basement membranes to produce tubulitis and resultant tubular degenerative changes (1–3). The interstitial infiltrate typically is composed of a predominance of lymphocytes with variable numbers of eosinophils, neutrophils, plasma cells, and histiocytes. The finding of abundant interstitial eosinophils favors the diagnosis of allergic/drug-induced interstitial nephritis (2,3).

Multiple unrelated conditions may be associated with AIN. The most common cause is allergic/drug-induced disease. Patients with allergic interstitial nephritis often demonstrate one or more of a triad of clinical symptoms that include fever, eosinophilia, and an allergic rash (1,4). Although the finding of prominent interstitial eosinophils favors allergic AIN, it often is difficult to determine the offending agent. AIN also is associated with autoimmune/collagen vascular diseases, including systemic lupus erythematosus (“lupus interstitial nephritis”), mixed connective tissue disease (MCTD), and Sjögren syn-

drome. AIN may represent renal involvement by sarcoidosis, which typically is accompanied by granulomatous inflammation. AIN also may result from bacterial or viral infection of the renal parenchyma, and it is the pattern of renal involvement in the entity of tubulointerstitial nephritis with uveitis. In many cases of AIN, the cause cannot be determined (1–4).

Optimal therapy for AIN is determined by the presumed cause. Drug-induced AIN is treated by discontinuation of potential offending agents, although corticosteroids commonly are used for resistant cases (1,4). Corticosteroids are the mainstay of treatment for AIN that is associated with systemic lupus erythematosus, MCTD, Sjögren syndrome, sarcoidosis, and tubulointerstitial nephritis with uveitis and frequently are used in cases of AIN of unknown cause (1–4). There is no consensus on the appropriate therapy for patients who are intolerant of corticosteroids or who relapse frequently upon dose reduction or discontinuation. Use of other immunosuppressives, such as cyclophosphamide, is mentioned only rarely in the literature (5).

Mycophenolate mofetil (MMF) is a widely used immunosuppressive agent in solid-organ transplantation and has been shown to reduce the risk for acute rejection in renal allograft recipients (6,7). The immunosuppressive and immunomodulatory properties of MMF likely result from inhibition of the rate-limiting enzyme in the *de novo* pathway of purine synthesis. MMF reduces lymphocyte proliferation, downregulates the expression of cell surface adhesion molecules, and decreases antibody production (8). MMF has been used successfully to treat a variety of glomerular diseases (9). In controlled trials of lupus nephritis, MMF has proved to be equivalent or superior

Received November 11, 2005. Accepted March 12, 2006.

Published online ahead of print. Publication date available at www.cjasn.org.

Address correspondence to: Dr. Dean C. Preddie, Department of Medicine/Division of Nephrology, Columbia University College of Physicians & Surgeons, 622 West 168th Street, PH4-124, New York, NY 10032. Phone: 212-305-3273; Fax: 212-305-6692; E-mail: dcp2014@columbia.edu

to standard therapy with cyclophosphamide and is associated with lower toxicity (10–14).

There is little available experience with MMF in the treatment of AIN. A single abstract describes the successful use of MMF in a single patient with AIN (15). We report the clinical history, pathologic findings, and outcomes in a cohort of eight steroid-resistant or steroid-intolerant patients who had AIN and were treated with MMF.

Materials and Methods

We retrospectively reviewed the medical records and renal biopsy findings in all eight patients at Columbia University who had biopsy-proven AIN and were treated with MMF. All eight patients were treated with at least one course of corticosteroids before MMF, received steroids for at least 6 mo, and were unable to discontinue therapy without worsening of the serum creatinine. All renal biopsies were processed according to standard techniques. Tissue was available for immunofluorescence and electron microscopy in five and seven cases, respectively. This study was approved by the Institutional Review Board of Columbia University.

Results

The cohort of patients who had AIN that was treated with MMF consisted of five women and three men with a mean age of 60 yr (range 53 to 67; Table 1). Seven patients were white, and one was black. Five of the patients had a history of hypertension, but none had diabetes. All patients presented with renal insufficiency, as evidenced by a mean serum creatinine of 2.3 mg/dl (range 1.5 to 3.2 mg/dl) and a mean creatinine clearance by the Modification of Diet in Renal Disease formula of 37.2 ml/min (range 20.8 to 49.5 ml/min). A 24-h urine protein collection was available for seven patients, five of whom had a 24-h urine protein of <1 g/d. A maximum 24-h urine protein of 1.502 g was seen in patient 5. A single patient had mild hy-

poalbuminemia (albumin 3.1 g/dl in patient 8), and none had evidence of peripheral edema. To our knowledge, this cohort included all known patients who had AIN and were treated with MMF at our institution.

Before treatment with MMF, all patients had been treated with corticosteroids. All had experienced >6 mo of corticosteroid therapy with inability to discontinue without worsening of the serum creatinine. Most patients had tried several times to discontinue the corticosteroids. One patient developed diabetes during 6 mo of steroid therapy and subsequently was changed to MMF. Six of the eight patients were considered steroid dependent or intolerant. The remaining two patients had relapsed recently after discontinuation of steroids. After discontinuation of steroids, one of the two patients had a repeat renal biopsy that showed active interstitial nephritis. As a result, steroids were reinstated.

All patients underwent renal biopsy. Sampling for light microscopy included a mean of 12.1 and a median of seven glomeruli. In all cases, glomeruli exhibited no significant histopathologic abnormalities. All biopsies exhibited the hallmarks of AIN, including interstitial inflammation, tubulitis, and resultant tubular injury (Figure 1A). The interstitial inflammation and tubulitis were severe in all but one case (moderate intensity in patient 4). Prominent interstitial eosinophils, a marker of drug-induced AIN, were seen in two cases. Two additional patients had a predominantly granulomatous pattern of interstitial nephritis (Figure 1B). The majority of biopsies exhibited only mild vascular disease. Immunofluorescence and electron microscopy were performed on five and seven cases, respectively, and revealed no evidence of glomerular, tubular, or interstitial immune complex formation.

The likely cause of the AIN could be determined for some of the patients. Patients 1 and 5 had abundant interstitial eosino-

Table 1. Clinical findings and outcomes^a

	Patient							
	1	2	3	4	5	6	7	8
Age (y)	67	53	61	60	63	65	54	57
Race	white	white	white	white	white	white	white	black
Gender	male	female	female	male	female	male	female	female
Presentation	ARF	ARF	ARF	ARF	ARF	ARF	ARF	ARF
Hypertension	yes	no	no	yes	yes	yes	no	yes
Creatinine (mg/dl)	3.2	1.5	2.0	2.1	3.1	1.9	1.8	2.6
GFR by MDRD (32) (ml/min)	35.8	38.0	36.0	49.5	20.8	47.0	48.0	22.5
24-h urine protein (g)	0.200	0.500	0.225	U	1.502	0.076	0.388	1.071
Presumed cause of AIN	ciprofloxacin	unknown	MCTD	pANCA	drug-induced	unknown	unknown	sarcoidosis
Renal biopsy findings	AIN with eosinophils	AIN	AIN	GIN	AIN with eosinophils	AIN	AIN	GIN
Treatment								
steroid courses	2	2	1	1	1	1	1	1
max MMF daily dose (mg)	1500	1500	2000	1000	1500	2000	1500	2000
MMF duration (mo)	32	23	29	24	25	13	34	14
Follow-up								
duration, after MMF (mo)	8	8	5	0	3	8	0	0
creatinine (mg/dl)	1.7	0.8	1.7	2.0	1.1	2.0	1.5	2.1

^aAIN, acute interstitial nephritis; ARF, acute renal failure; GIN, granulomatous interstitial nephritis; MCTD, mixed connective tissue disease; MDRD, Modification of Diet in Renal Disease; MMF, mycophenolate mofetil; pANCA, perinuclear anti-neutrophil cytoplasmic antibody.

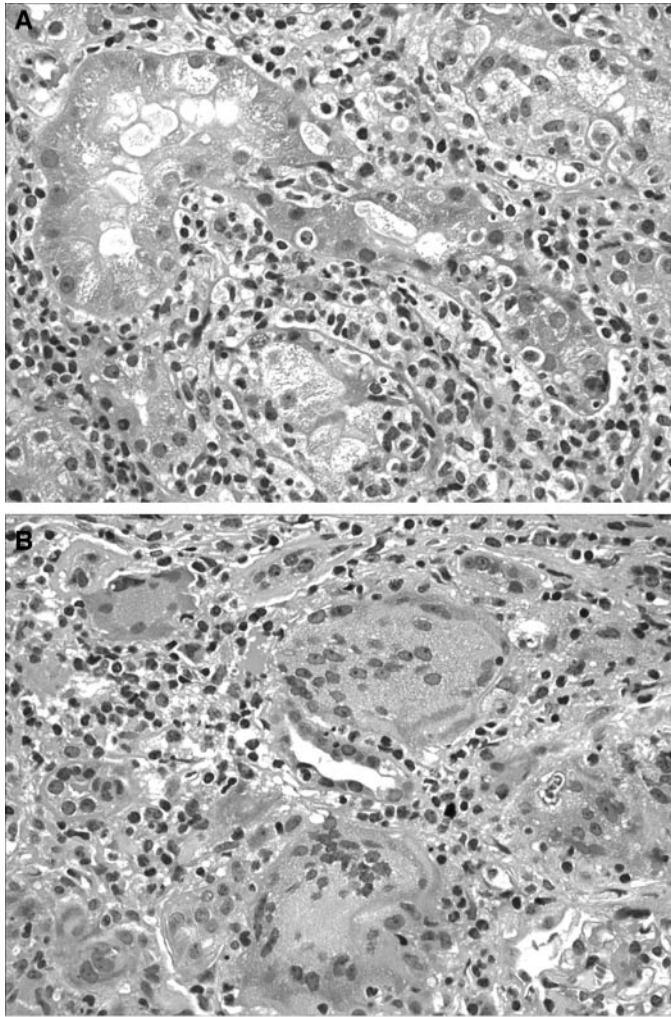


Figure 1. (A) An example of acute interstitial nephritis (from patient 5) with severe interstitial inflammation composed of lymphocytes, eosinophils, and monocytes. The interstitial inflammation extends across tubular basement membranes to produce severe tubulitis. (B) Granulomatous interstitial nephritis is characterized by interstitial inflammation composed of histiocytes and multinucleated giant cells (from patient 8). Four multinucleated giant cells are seen in this field. In the center, there is evidence of tubulitis. Magnification, $\times 400$ (hematoxylin and eosin).

phils, favoring allergic/drug-induced disease. This likely related to recent treatment with ciprofloxacin in patient 1. Patient 8 had granulomatous interstitial nephritis as a result of sarcoidosis. Patient 4 also had granulomatous interstitial nephritis, possibly related to perinuclear anti-neutrophil cytoplasmic antibody seropositivity. Patient 3 had MCTD. The cause of AIN in patients 2, 6, and 7 could not be determined from the clinical history or pathologic findings.

Patients initially were treated with MMF in doses that ranged from 500 to 1000 mg twice daily. Doses were titrated to 1000 mg orally twice daily as tolerated by monitoring leukocyte counts and gastrointestinal side effects. Changes in renal function were monitored by serial measurements of serum creatinine.

At the start of treatment with MMF, the mean serum creatinine was 2.3 mg/dl. Six of the 8 patients had improvement in renal function after treatment with MMF, as evidenced by a decline in serum creatinine of at least 0.3 mg/dl. In the remaining two patients, the serum creatinine essentially was unchanged (patients 4 and 6). The mean serum creatinine at the conclusion of the study was 1.6 mg/dl (Figure 2). At most recent follow-up (mean 28 mo; range 14 to 40 mo), three patients are still maintained on reduced doses of MMF (250 to 500 mg twice daily) and all have discontinued corticosteroids. Five patients have discontinued MMF and have been off of immunosuppressive therapy for a mean of 6.4 mo. Patient 1 discontinued MMF after 24 mo and has had a stable creatinine of 1.7 mg/dl in the subsequent 8 mo. Patient 3 initially experienced a relapse after discontinuation of MMF but was able to discontinue on a second attempt several months later without a rise in her nadir creatinine of 1.7 mg/dl. One patient sustained a myocardial infarct during therapy, had a prolonged hospital course, was taken off MMF, and ultimately died of cardiac disease. MMF was discontinued at the time of the myocardial infarct, and his course was believed to be unrelated to treatment with MMF. There were no major complications of MMF therapy.

Discussion

AIN is a common cause of ARF leading to renal biopsy. As many as 15% of patients who have ARF and undergo biopsy will have this lesion (16). Most cases of AIN have been attributed to medications, and the reaction has been attributed variously to cell-mediated immunity or hypersensitivity reactions (17). Even in patients who present with the classic features of allergic/drug-induced AIN, such as fever, rash, and eosinophilia associated with nonoliguric renal failure, it often is difficult to incriminate a single offending medication. Moreover, some medications, such as nonsteroidal anti-inflammatory drugs, may produce an atypical picture without classic hypersensitivity features (18,19). The usual therapy of discontinuing all potential offending medications often is successful in reversing the renal dysfunction. Rechallenge with a potential medication, which would document the offending agent, has been done only rarely and even then usually inadvertently.

Corticosteroids have been the common therapy for progressive and resistant drug-induced AIN (1–4). They also have been

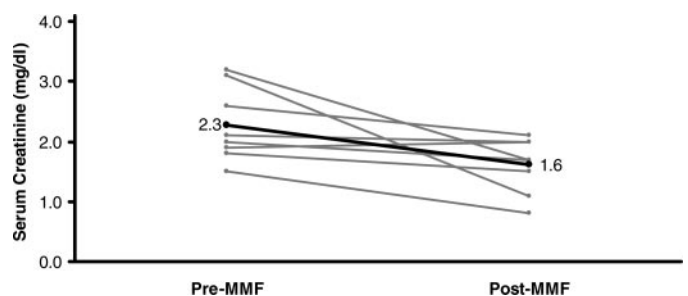


Figure 2. Changes in renal function after treatment with mycophenolate mofetil (MMF).

used successfully in interstitial nephritis that is associated with sarcoidosis, lupus, and Sjögren syndrome (20–22). Although there are no controlled, randomized trials, retrospective analyses suggest improvement in both renal function and histologic findings after treatment of AIN with corticosteroids (6). Selection bias actually might favor those who are untreated, because patients who have more progressive courses that do not respond to discontinuation of potential offending drugs would be most likely to receive treatment. Regardless, some patients are resistant to therapy, some respond but relapse with tapering the corticosteroid dosage, and others do not tolerate the treatment, especially if prolonged therapy is necessary (5).

Other therapies rarely have been attempted for these patients. Individual patients have been treated with other immunosuppressive agents (6). One case that was presented as an abstract revealed improvement with MMF (1). In the cohort described herein, all patients had received corticosteroids and had experienced relapses, intolerance, and resistance to therapy. MMF was used because of its known immunosuppressive effect and patient tolerance in other renal populations. In transplantation, MMF has been used successfully in several large trials that have documented both efficacy and a good safety profile (7,8). In systemic lupus, both induction and maintenance studies have shown benefit over potentially more toxic therapeutic options (13–15). MMF also has been used successfully in small uncontrolled trials in membranous nephropathy and focal segmental glomerulosclerosis (23–27). In IgA nephropathy, treatment trials have given mixed results, but the medication has been well tolerated (28–31). Given this background and the lack of other proven therapeutic options, we treated eight patients with MMF for interstitial nephritis. In each case, serum creatinine stabilized or improved on therapy. Five patients have been able to discontinue treatment with MMF successfully. The remaining three patients are maintained on MMF, unable to discontinue without relapse. This may mean that we are trading steroid dependence and adverse effects for MMF dependence and adverse effects. Further follow-up of such patients will clarify this issue.

It should be emphasized that MMF was not tried as initial therapy in any patient and was not compared with steroid therapy or placebo alone. In such a study, it might prove superior or inferior to corticosteroids. It is unlikely that such a study will be performed, because many patients with allergic/drug-induced AIN respond solely to discontinuation of the potential offending agents. When tolerated, corticosteroids are effective in many patients. As a result, the number of remaining patients is low enough that many centers will have to aggregate their cases if a randomized trial is to be performed. It should be noted that the mean serum creatinine of 2.3 mg/dl in our cohort is less than the mean peak serum creatinine in some previous studies on AIN (3). Nevertheless, for steroid-resistant or intolerant patients, MMF seems to be a useful therapeutic option. Moreover, in patients with obesity, diabetes, or other factors that make corticosteroids an unpalatable first therapeutic option, MMF may be considered as first-line therapy. At present, no serious adverse effects have been attributed to the MMF treatment in our patients, and remissions have been maintained

on tapering doses, which should lead to few adverse reactions. Further study is needed to define better the role of MMF in the treatment of AIN.

References

1. Appel GB: Interstitial nephritis. In: *ACP Medicine*, New York, Web MD Inc., pp 2027–2042
2. Rossert J: Drug-induced acute interstitial nephritis. *Kidney Int* 60: 804–817, 2001
3. Clarkson MR, Giblin L, O'Connell FP, O'Kelly P, Walshe JJ, Conlon P, O'Meara Y, Dormon A, Campbell E, Donohoe J: Acute interstitial nephritis: Clinical features and response to corticosteroid therapy. *Nephrol Dial Transplant* 19: 2778–2783, 2004
4. Baker RJ, Pusey CD: The changing profile of acute tubulointerstitial nephritis. *Nephrol Dial Transplant* 19: 11–16, 2004
5. Neilson EG: Pathogenesis and therapy of interstitial nephritis. *Kidney Int* 35: 1257–1270, 1989
6. The Tricontinental Mycophenolate Mofetil Renal Transplantation Study Group: A blinded, randomized clinical trial of mycophenolate mofetil for the prevention of acute rejection in cadaveric renal transplantation. *Transplantation* 61: 1029–1037, 1996
7. Halloran P, Mathew T, Tomlanovitch S, Groth C, Hooftman L, Barker C: Mycophenolate mofetil in renal allograft recipients: A pooled efficacy analysis of three randomized, double-blind, clinical studies in prevention of rejection. *Transplantation* 63: 39–47, 1997
8. Allison AC, Eugui EM: Mycophenolate mofetil and its mechanism of action. *Immunopharmacology* 47: 85–118, 2000
9. Appel GB, Radhakrishnan J, Ginzler EM: Use of mycophenolate mofetil in autoimmune and renal diseases. *Transplantation* 80[Suppl]: S265–S271, 2005
10. Contreras G, Pardo V, Leclercq B, Lenz O, Tozman E, O'Nan P, Roth D: Sequential therapies for proliferative lupus nephritis. *N Engl J Med* 350: 971–980, 2004
11. Chan TM, Tse KC, Tang CS, Mok MY, Li FK; Hong Kong Nephrology Study Group: Long-term study of mycophenolate mofetil as continuous induction and maintenance treatment for diffuse proliferative lupus nephritis. *J Am Soc Nephrol* 16: 1076–1084, 2005
12. Ginzler EM, Dooley MA, Aranow C, Kim MY, Buyon J, Merrill JT, Petri M, Gilkeson GS, Wallace DJ, Weisman NH, Appel GB: Mycophenolate mofetil or intravenous cyclophosphamide for lupus nephritis. *N Engl J Med* 353: 2219–2228, 2005
13. Dooley MA, Cosio FG, Nachman PH, Falkenhain ME, Hogan SL, Falk RJ, Hebert LA: Mycophenolate mofetil therapy in lupus nephritis: Clinical observations. *J Am Soc Nephrol* 10: 833–839, 1999
14. Karim MY, Alba P, Cuadrado MJ, Abbs IC, D'Cruz DP, Khamashta MA, Hughes GR: Mycophenolate mofetil for systemic lupus erythematosus refractory to other immunosuppressive agents. *Rheumatology (Oxford)* 41: 876–882, 2002
15. Mihindukulasuriya JC, Gara PJ, Markowitz GS: Idiopathic hypocomplementemic interstitial nephritis with extensive tubulointerstitial deposits: Reversal of subacute renal failure with mycophenolate mofetil and corticosteroids [Abstract]. *J Am Soc Nephrol* 14: 800A, 2003
16. Farrington K, Levison DA, Greenwood RN, Cattell WR,

- Baker LR: Renal biopsy in patients with unexplained renal impairment and normal kidney size. *Q J Med* 70: 221–233, 1989
17. Appel GB: Acute interstitial nephritis. In: *Immunologic Renal Disease*, edited by Neilsen E, Couser W, Philadelphia, Lippincott-Raven, 2001, pp 1269–1281
 18. Appel GB: COX-2 inhibitors and the kidney. *Clin Exp Rheumatol* 19[Suppl 25]: S37–S40, 2001
 19. Markowitz GS, Falkowitz DC, Isom R, Zaki M, Imaizumi S, Appel GB, D'Agati VD: Membranous glomerulopathy and acute interstitial nephritis following treatment with celecoxib. *Clin Nephrol* 59: 137–142, 2003
 20. Bossini N, Savoldi S, Franceschini F, Mombelloni S, Baronio M, Cavazzana I, Viola BF, Valzorio B, Mazzucchelli C, Cattaneo R, Scolari F, Maiorca R: Clinical and morphological features of kidney involvement in primary Sjogren's syndrome. *Nephrol Dial Transplant* 16: 2328–2336, 2001
 21. Park MH, D'Agati V, Appel GB, Pirani CL: Tubulointerstitial disease in lupus nephritis: Relationship to immune deposits, interstitial inflammation, glomerular changes, renal function and prognosis. *Nephron* 44: 309–319, 1986
 22. Brause M, Magnusson K, Degenhardt S, Helmchen U, Grabensee B: Renal involvement in sarcoidosis: A report of 6 cases. *Clin Nephrol* 57: 142–148, 2002
 23. Cattran DC, Wang MM, Appel G, Matalon A, Briggs W: Mycophenolate mofetil in the treatment of focal segmental glomerulosclerosis. *Clin Nephrol* 62: 405–411, 2004
 24. Briggs WA, Choi MJ, Scheel PJ Jr: Successful mycophenolate mofetil treatment of glomerular disease. *Am J Kidney Dis* 31: 213–217, 1998
 25. Miller G, Zimmerman R 3rd, Radhakrishnan J, Appel G: Use of mycophenolate mofetil in resistant membranous nephropathy. *Am J Kidney Dis* 36: 250–256, 2000
 26. Choi MJ, Eustace JA, Gimenez LF, Atta MG, Scheel PJ, Sothinathan R, Briggs WA: Mycophenolate mofetil treatment for primary glomerular diseases. *Kidney Int* 61: 1098–1114, 2002
 27. DuBuf-Verejken P, Wetzels J: Mycophenolate mofetil vs. cyclophosphamide in patients with idiopathic membranous nephropathy and renal insufficiency [Abstract]. *J Am Soc Nephrol* 15: 341A, 2004
 28. Chen X, Chen P, Cai G, Wu J, Cui Y, Zhang Y, Liu S, Tang L: A randomized control trial of mycophenolate mofetil treatment in severe IgA nephropathy [in Chinese]. *Zhonghua Yi Xue Za Zhi* 82: 796–801, 2002
 29. Tang S, Leung JCK, Tang AWC, Ho YW, Chan LYY, Chan TM, Lai KN; for the Hong Kong IgA Nephropathy Study Group: A prospective randomized case controlled trial on the efficacy of mycophenolate mofetil in IgA nephropathy patients with persistent proteinuria despite angiotensin blockade [Abstract]. *J Am Soc Nephrol* 14: 752A–753A, 2003
 30. Maes BD, Oyen R, Claes K, Evenepoel P, Kuypers D, Vanwallenghem J, Van Damme B, Vanrenterghen YF: Mycophenolate mofetil in IgA nephropathy: Results of a 3-year prospective placebo-controlled randomized study. *Kidney Int* 65: 1842–1849, 2004
 31. Frisch G, Lin J, Rosenstock J, Markowitz G, D'Agati V, Radhakrishnan J, Preddie D, Crew J, Valeri A, Appel G: Mycophenolate mofetil (MMF) vs. placebo in patients with moderately advanced IgA nephropathy: A double-blind randomized controlled trial. *Nephrol Dial Transplant* 21: 2139–2145, 2005
 32. Levey AS, Bosch JP, Lewis JB, Greene T, Rogers N, Roth D; for the Modification of Diet in Renal Disease Study Group: A more accurate method to estimate glomerular filtration rate from serum creatinine: A new prediction equation. *Ann Int Med* 130: 461–470, 1999

See related editorial, "Is Mycophenolate Mofetil a New Treatment Option in Acute Interstitial Nephritis," on pages 609–610.