

Chronic Nephropathies of Cocaine and Heroin Abuse: A Critical Review

Jared A. Jaffe and Paul L. Kimmel

Division of Renal Diseases and Hypertension, Department of Medicine, George Washington University Medical Center, Washington, DC

Renal disease in cocaine and heroin users is associated with the nephrotic syndrome, acute glomerulonephritis, amyloidosis, interstitial nephritis, and rhabdomyolysis. The pathophysiologic basis of cocaine-related renal injury involves renal hemodynamic changes, glomerular matrix synthesis and degradation, and oxidative stress and induction of renal atherogenesis. Heroin is the most commonly abused opiate in the United States. Previous studies identified a spectrum of renal diseases in heroin users. The predominant renal lesion in black heroin users is focal segmental glomerulosclerosis and in white heroin users is membranoproliferative glomerulonephritis. Although the prevalence of heroin use in the United States has increased, the incidence of "heroin nephropathy" has declined. Because reports of heroin nephropathy predated the surveillance of hepatitis C virus and HIV, the varied findings might be related to the spectrum of viral illnesses that are encountered in injection drug users. Socioeconomic conditions, cultural and behavioral practices, or differences in genetic susceptibilities may be more associated with the development of nephropathy in heroin users than the drug's pharmacologic properties. Administration of cocaine in animal models results in nonspecific glomerular, interstitial, and tubular cell lesions, but there is no animal model of heroin-associated renal disease. The heterogeneity of responses that are associated with heroin is not consistent with a single or simple notion of nephropathogenesis. There are no well-designed, prospective, epidemiologic studies to assess the incidence and the prevalence of renal disease in populations of opiate users and to establish the validity of a syndrome such as heroin nephropathy. It is concluded although there is a paucity of evidence to support a heroin-associated nephropathy, the evidence from *in vitro* cellular and animal studies to support the existence of cocaine-induced renal changes is more convincing.

Clin J Am Soc Nephrol 1: 655–667, 2006. doi: 10.2215/CJN.00300106

Substance abuse is common, involving lifetime exposure of 46% of the general population (1). Estimates for US lifetime and past-month prevalence of drug abuse among the general population aged 12 yr and older are 110 million and 19 million, respectively (2). The problem of drug abuse may be underestimated on questionnaires because of the sensitive nature of the illegal activity involved. Therefore, some respondents may be uncomfortable answering such questionnaires truthfully. Also, surveys do not account for institutionalized and homeless people, which include a significant high-risk population of substance abusers.

Substances with the potential to be abused include alcohol, opiates, sedatives and hypnotics, cocaine, cannabis, hallucinogens and psychedelic drugs, psychotropic, stimulant and anxiolytic medications, and analgesics and amphetamines (3), which may have direct or indirect effects on physiologic mechanisms that lead to organ system dysfunction and disease. A multitude of renal diseases are associated with drug abuse because of the many different substances used with widely

varying pharmacologic effects (3–10). Such drugs have been associated with several renal syndromes (3,4) by varied mechanisms. Causal associations between particular drugs and the development of a single renal disease, however, remain undetermined for the most part.

Renal disease in cocaine and heroin abusers has been associated with the nephrotic syndrome, acute glomerulonephritis, amyloidosis, interstitial nephritis, and rhabdomyolysis. We pose the question, "Do cocaine and heroin nephropathies exist as specific entities, and, if so, what is the evidence to support or deny these claims?" We provide a critical review of the history, epidemiology, and pathophysiologic evidence supporting a causal relationship between cocaine and heroin abuse and chronic kidney disease (CKD).

Cocaine

Historical Perspective

Cocaine has had a significant impact on many societies, cultures, and religions in the past 1200 yr. Shortly after its introduction to the United States in 1854, the nonmedicinal use of cocaine became predominant, eventually leading to abuse and dependence (11).

Cocaine (benzoyl methylecgonine) is extracted from the leaves of the South American plant *Erythroxylon coca* (12). It exists in two major forms: Cocaine hydrochloride and alkaloi-

Published online ahead of print. Publication date available at www.cjasn.org.

Address correspondence to: Dr. Paul L. Kimmel, Division of Renal Diseases and Hypertension, Department of Medicine, George Washington University Medical Center, 2150 Pennsylvania Avenue NW, Washington, DC 20037. Phone: 202-741-2283; Fax: 202-741-2285; E-mail: pkimmel@mfa.gwu.edu

dal freebase (crack) cocaine (Table 1) (12–15). Cocaine is well absorbed through mucous membranes, resulting in a slower onset of action, a later peak effect, and a longer duration of action when used orally or nasally compared with intravenous injection (12,16).

Epidemiology of Abuse

Today, cocaine abuse and dependence is epidemic in the United States (Table 2). A total of 34.3 million Americans (14.6% of surveyed population) have used cocaine at some time, and 2.1 million Americans (0.9% of the surveyed population) used cocaine the month before the survey (Table 2) (17). In New York City between 1990 and 1992, cocaine metabolites were found in the blood and urine in 26.7% of people who sustained fatal injuries (18). More than 30% of deaths after cocaine use were attributed to drug intoxication; 65% involved traumatic injuries (19). A total 143,000 emergency department visits mentioned cocaine in 1994, and nearly 199,000 in 2002 (20).

Pathophysiologic Basis for Renal Disease

Except for cocaine-induced rhabdomyolysis (21–39), the direct effects of cocaine on the kidney have received less attention. The pathophysiologic basis of cocaine-related renal injury is multifactorial and involves changes in renal hemodynamics, changes in glomerular matrix synthesis, degradation and oxidative stress, and induction of renal atherosclerosis (12,40).

Cocaine has potent vasoconstrictive effects on vascular smooth muscle; however, the cellular mechanisms of action have not been elucidated (12,41–43). Cocaine inhibits catecholamine reuptake at the presynaptic nerve terminal, blocks norepinephrine reuptake in sympathetically innervated tissues, and releases norepinephrine and epinephrine from the adrenal medulla (12,44,45), resulting in development of hypertension and tachycardia (12). Cocaine may affect directly smooth muscle vascular cell calcium influx (12,46,47).

Endothelins (ET) have been implicated in the vascular dysfunction that is induced by cocaine intoxication (12). There is a high density of ET-1 receptors in the vascular smooth muscle of all renal resistance vessels (48). Increased ET-1 production causes decreased renal blood flow and GFR (49). ET-1 is elevated in the plasma and urine of pregnant women with cocaine intoxication (12,50–52).

Involvement of the renin-angiotensin-aldosterone system (RAAS) has been suggested because cocaine-induced ET release is inhibited by captopril and lisinopril in cultured human and

bovine endothelial cells (50). Endothelial cells produce endogenous angiotensin-converting enzyme (ACE), suggesting that the effect of ACE inhibitors on BP and cardiovascular function may be due to local effects on endothelial cells (53). Captopril downregulates ET-1 release in cultured endothelial cells (54). Captopril in combination with diazepam increased survival time in rats that were exposed to lethal levels of cocaine (55). Ultimately, activation of the RAAS and angiotensin II by cocaine may lead to renal fibrosis from stimulation of TGF- β (12). The arterial pressor response involves the L-arginine–nitric oxide (NO) pathway (56). Rats that were pretreated with L-w-N-monomethylarginine, an NO synthase inhibitor, had an 80% reduction in pressor response to cocaine compared with controls (56). Collectively, the effects of cocaine on the kidney, through ET-1, the RAAS, and the L-arginine–NO pathway, result in vasoconstriction of the glomerular microcirculation.

Cocaine has been linked to accelerated atherosclerosis in both animal experiments and human studies and autopsy findings (57–70). Cocaine increases renal cellular oxidative stress and decreases intracellular glutathione in cocaine-exposed cultured renal epithelial cells (71). Cocaine increased thromboxane production and platelet aggregation in *in vitro* platelet cultures (72) and platelet activity, measured by platelet p-selectin expression, in human and canine models (73,74). Cocaine exposure increased collagen synthesis in rabbit aorta (61).

Severe renal arteriosclerosis was noted in a 41-yr-old black man who did not have other risk factors and abused cocaine for 10 yr (65). Renal biopsy demonstrated mildly increased mesangial matrix without deposits, normal basement membranes, and mild interstitial fibrosis. Interlobular and segmental arteries showed severe narrowing as a result of marked intimal fibrosis.

Cocaine has been associated with accelerated and malignant hypertension as well as implicated in hastening the progression of hypertensive nephrosclerosis to ESRD (75,76). Twelve black individuals who were identified as habitual cocaine users for up to 10 yr presented with severe hypertension, advanced renal insufficiency, non-nephrotic-range proteinuria, and decreased renal size. Information on serologic evaluation and confirmation of renal disease by renal biopsy was not given. Therefore, the presence of other nephropathies cannot be excluded (77–87).

Chronic administration of cocaine to rats results in nonspecific glomerular, interstitial, and tubular cell lesions (88). Co-

Table 1. Characteristics and properties of cocaine^a

	Cocaine Hydrochloride	Alkaloidal Cocaine
Solubility	Water soluble	Water insoluble
Physical form	Powder	Transparent crystals
Route of administration	Intravenous, nasal, and oral ingestion	Inhalation
Onset of action	1–5 min	Seconds
Peak effect	20 min	<1 min

^aData from Nzerue *et al.* (12), Hollister (13), Zafar *et al.* (14), and Kokko (12).

Table 2. Estimated lifetime and past-month prevalence and demographic characteristics of cocaine and heroin use among individuals 12 yr and older in the United States^a

	Cocaine (Excluding Crack)		Heroin	
	Lifetime	Past Month	Lifetime	Past Month
Total prevalence of population (%)	34,331 (14.6)	2116 (0.9)	3767 (1.6)	235 (0.1)
Demographic characteristics				
age (yr)				
12 to 17	668 (2.7)	149 (0.6)	99 (0.4)	0 (0.0)
18–25	4840 (15.6)	652 (2.1)	496 (1.6)	62 (0.2)
>26	28,841 (16.2)	1255 (0.7)	3111 (1.7)	179 (0.1)
gender				
male	20,676 (18.2)	1363 (1.2)	2726 (2.4)	114 (0.1)
female	13,613 (11.2)	729 (0.6)	1094 (0.9)	0 (0.0)
race				
white	26,297 (15.9)	1323 (0.8)	2646 (1.6)	165 (0.1)
black	3271 (12.2)	456 (1.7)	483 (1.8)	54 (0.2)
Native American or Alaskan	276 (18.9)	28 (1.9)	31 (2.1)	1 (0.1)
Native Hawaiian	99 (12.5)	5 (0.6)	5 (0.6)	0 (0.0)
Asian	408 (4.5)	181 (0.2)	9 (1.0)	0 (0.0)
Hispanic	3577 (12.3)	233 (0.8)	118 (1.3)	29 (0.1)

^aData from the Substance Abuse and Mental Health Data Archive (SAMHDA) (17). Prevalence values reported were rounded up to the nearest 1000 and divided by 1000 (*e.g.*, reported prevalence of 4840 is 4,840,000 people in the United States). Total prevalence (%) is based on a weighted population $n = 235,142,978$.

caine hydrochloride or saline was administered intraperitoneally to 28 experimental and 28 control rats for 90 d. No lesions were observed in controls, whereas a variety of lesions were found in cocaine-treated rats (Table 3). Chronic cocaine administration produced progressive changes in renal tubules and interstitium. Marked dilation of some tubules and necrosis of proximal and distal collecting tubular cells, with nuclear karyorrhexis, cytoplasmic eosinophilia, and vacuolization, were demonstrated.

Renal lesions seen in the rat model were dissimilar to those found in human autopsies (64). Histologic features of 40 kidney autopsy specimens in patients with cocaine-related deaths were compared with 40 accident victims. The ratio of the number of sclerotic glomeruli to the total number of glomeruli was 18-fold greater in cocaine users than in controls. Highly significant

differences also were found in the degree of periglomerular fibrosis, degree of interstitial cellular infiltrate, and hyperplastic arteriosclerosis in cocaine users compared with controls. Medial thickening, luminal narrowing, and vessel obstruction were absent in the control group. A total of 75% of cases were found to have advanced coronary atherosclerosis, more extensive than expected in normal populations >60 yr of age.

Currently, no epidemiologic data address cocaine-associated CKD in the United States. A case-control study was performed to examine recreational drug use as a risk factor for ESRD (89). Reported cocaine use was associated with a three-fold increased risk for developing ESRD. However, after adjustment for use of opiates, the relative risk for cocaine became insignificant. Differences in urban and rural communities and their unique set of cultural practices may modify the risk for developing CKD (90).

Table 3. Renal histologic findings of rats that were treated with intraperitoneal cocaine for 90 d^a

Day	Histology
15	Glomeruli with increased mesangial matrix and decreased epithelial cell number Some capillary loops were occluded by thrombi
30	Capillary walls were thinned, variably ruptured, or destroyed Adhesions to Bowman's capsule and thickening of the capsular basal membrane
60	Glomeruli showed moderate mesangial cell proliferation Diffuse thickening of the capillary basement membrane
90	Glomeruli were deformed and smaller Capillaries were adherent to Bowman's capsule

^aData from Barroso-Moguel *et al.* (88).

A prospective cohort of 647 patients who were followed during a 15-yr period were assessed to associate a history of illicit drug use with renal functional decline (91). There was a three-fold, significantly increased risk for mild functional decline associated with cocaine or crack use compared with nonusers. The study could not determine whether illicit drug use preceded the decline in renal function.

Cocaine use was reported in 28.5% of 193 dialysis patients (92). A history of cocaine use was associated with a diagnosis of hypertension-related ESRD in 89.1% of cocaine users *versus* 46.4% of nonusers. Cocaine users had significantly fewer years of hypertension than nonusers before developing ESRD (5.3 ± 5.4 *versus* 12.7 ± 9.8 yr; $P < 0.0005$). Illicit drug use, however, was not found to be a risk factor for severe hypertension in a black and Hispanic population (93). Despite the plausible putative effects of cocaine on the kidney and vasculature, medical noncompliance and socioeconomic factors may contribute to the increased risk for renal deterioration in hypertensive black individuals (94,95). Diagnoses of hypertension-related ESRD often are made on clinical grounds alone, so the validity of reported causes of ESRD may be uncertain without verification by renal biopsy (92). Nephrologists are more likely to make a clinical diagnosis of hypertensive nephrosclerosis as a cause of ESRD in black patients (96). Well-controlled, prospective, epidemiologic studies are needed to clarify the relationship between cocaine use and the development of CKD.

Rare associations of cocaine and renal disease have been described in case reports of renal infarction after nasal insufflation of cocaine (97), a case of anti-glomerular basement membrane antibody-mediated glomerulonephritis (98), and acute interstitial nephritis induced by crack cocaine (99). Besides these uncommon associations, the pathophysiologic mechanisms of cocaine-induced CKD largely remain unknown.

Heroin

Historical Perspective

Heroin is processed from morphine, a naturally occurring substance that is extracted from various poppy plant species. Heroin can be injected, inhaled, or smoked for its euphoric effects. The purity of heroin depends on whether the heroin is “cut” with other drugs or substances, known as adulterants. Common adulterants include sucrose, dextrose, mannitol, lactose, starches, powdered milk, quinine, caffeine, inositol, lidocaine, procaine, acetylprocaine, methapyrilene, and strychnine (100). The Drug Enforcement Administration analyzed 12,366 heroin/cocaine samples and found a frequency of adulterants exceeding 5% (101).

Epidemiology of Heroin Abuse and Kidney Disease

Heroin is the most commonly abused opiate in the United States (102), accounting for a lifetime prevalence of 1.6% among Americans 12 yr and older (17) (Table 2). From 1992 through 2002, the annual number of new heroin users ranged from 96,000 to 122,000 (103). During this period, approximately 75% of new users were 18 yr and older, and 63% were male (103). There is little difference in the proportion of heroin users among various racial or ethnic groups (17) (Table 2). Heroin

abuse has become a growing health-related problem in large metropolitan areas. In June 2003, 62 to 82% of all emergency admissions that were associated with illicit drug use (except alcohol) were related to the use of heroin in Baltimore, Boston, and Newark (104). Forty heroin- or morphine-related emergency encounters per 100,000 residents were projected in 2000 (105). In comparison, there were 70.7 cocaine-related and almost 40 marijuana-related emergency encounters per 100,000 residents (105). Total emergency encounters for heroin/morphine increased from 63,158 in 1994 to 94,804 in 2000 (105,106).

Historical Perspective of Renal Disease and Heroin Use

McGinn *et al.* (107) first described the presence of renal disease associated with the use of heroin in the 1970s. Three heroin addicts and one cocaine addict who were aged 17 to 22 yr and had nephrotic syndrome were described. Initially, all patients had renal biopsies without lesions on light microscopy. Three patients were followed for 3 mo and demonstrated stable or progressive proteinuria despite trials of prednisone, azathioprine, or both drugs in combination. A second biopsy in one patient revealed membranous glomerulonephritis.

Focal membranoproliferative glomerulonephritis with IgM and complement deposition was found in seven of eight heroin addicts with the nephrotic syndrome (108). Four men and two women, aged 23 to 40 yr, presented with a chief complaint of edema. Patients had azotemia, nephrotic-range proteinuria, and hematuria. Four patients had hypocomplementemia, and four had polyclonal gammopathy. Basement membrane thickening with electron-dense deposits as well as amorphous electron-opaque material in the subendothelial space were found. Amyloid fibrils were absent.

Focal and segmental glomerulosclerosis (FSGS) was a common glomerular lesion in heroin users who underwent biopsies in other case series (109–112). FSGS, with a paucity of focal proliferative changes, was found in 11 of 13 heroin users who underwent biopsies (109). All patients were black men, aged 19 to 34 yr, who admitted to injecting heroin for 1 to 18 yr before the onset of renal disease. Three patients had a recent history of icteric hepatitis, and three patients had elevated ASO titers. Immunofluorescence studies detected a consistent pattern of focal and segmental glomerular IgM and C3 deposits.

Contrary to finding FSGS in some renal biopsy series, other investigators noted a high prevalence of sclerosing glomerulonephritis (113,114). Twenty-three black men with a history of a few months to 15 yr of heroin use presented with hypertension and varying degrees of renal insufficiency, proteinuria, and urinary abnormalities. Varying degrees of glomerulosclerosis were present on light microscopy. Fine basement membrane linear deposition of IgG and focal granular IgM and C3 deposits were demonstrated in 16 of 21 biopsies performed. Global, segmental, or mesangial sclerosis; glomerular basement membrane thickening; and epithelial cell foot process dropout also were demonstrated. The authors compared renal biopsies that were performed in drug abusers and non-drug abusers with glomerulosclerosis and found no renal pathologic markers that differentiated the two groups.

Llach *et al.* (115) found no specific histologic or immunoflu-

orescent pattern in patients who had renal disease and used heroin. A spectrum of pathologic findings including FSGS, minimal-change disease, mesangial proliferation, membranoproliferative glomerulonephritis, dysproteinemias, and diabetic nephropathy was found by Grisham, Churg, and Porush in heroin users with renal disease (116). A case of granulomatous interstitial nephritis also was reported in a heroin user (117).

Focal and diffuse segmental and global glomerulosclerosis also was demonstrated in patients who used intravenous pentazocine or tripeleminamine. The investigators concluded that renal findings that were associated with heroin use were non-specific (118).

Renal biopsies in 19 white heroin users also demonstrated a spectrum of pathologic findings, including 13 patients with membranoproliferative glomerulonephritis (MPGN), two with chronic interstitial nephritis, two with acute proliferative glomerulonephritis, one with amyloidosis, and one with granulomatous glomerulonephritis and interstitial nephritis (119). All patients had serologic evidence of hepatitis C virus (HCV) infection, one had hepatitis B surface antigenemia, and three had HIV infection. The authors concluded that nephropathy in this group of white heroin addicts was frequently associated with HCV-associated MPGN rather than the FSGS previously reported in black individuals. Dettmeyer *et al.* (120) reported similar findings from 179 autopsies of white heroin addicts.

Lynn *et al.* (121) described renal biopsies of five intravenous opiate abusers who had large amounts of vacuolated material deposited within the mesangium and within endothelial and epithelial cells. The one commonality that was shared among these patients was the intravenous use of opiates mixed with lemon juice or acetic anhydride and sodium bicarbonate as vehicle. Some authors have speculated that the drug vehicle or adulterants in drugs may be the cause of kidney injury, rather than the opiate itself (100,113,122). Friedman and Rao (122) studied the declining incidence of heroin-associated nephropathy at Kings County Hospital in Brooklyn, NY, from 1983 to 1993. There were no cases reported from 1991 through 1993, despite a rise in opioid-related hospital admissions. Cases were defined histologically by FSGS and mesangial deposition of IgG, IgM, and C3, with varying degrees of tubular injury. The authors speculated that the increased purity of street heroin from 6.9 to 8% in 1980 to 1981 to 61% in 1992 and the concomitant decline in accompanying adulterants may have been responsible for the reduction in the incidence of heroin nephropathy. They suggested that the presence of concomitant infectious processes, such as HIV infection in heroin users, may have contributed to the development of renal injury.

Infective endocarditis, HIV, and HBV and HBC infections are associated with renal pathologic patterns similar to those previously described in heroin users (123–137). Because reports of heroin-associated nephropathy predated the surveillance of HCV and HIV infection with serologic and virologic tools, it is conceivable that some of the various histologic findings might have been related to the spectrum of viral illnesses that are encountered in injection drug users (3). Transmission of HIV, HBV, and HCV among injection drug users is common. In several cohorts, seroprevalence rates for HCV, HBV, and HIV

were 85, 77 to 84, and 24 to 28%, respectively (138–141). A high prevalence of HIV, HCV, and HBV infections among intravenous drug abusers therefore may limit the ability to discriminate putative infectious from heroin-related renal disease. Similarly, the increasing incidence of injection drug use has had an impact on the overall incidence of infectious endocarditis (135,136).

An increased frequency of HLA-B53 was found in 47 black patients with presumed heroin-associated nephropathy (142). Rather than a genetic susceptibility of heroin users to developing nephropathy, several authors have suggested that there is a genetic link predisposing black individuals to developing FSGS (79–84,142–144). Idiopathic FSGS has become the leading cause of nephrotic syndrome in black individuals, as well as a common cause of renal disease in white individuals in the United States (79). However, black individuals are four times more likely to develop FSGS than are white individuals (79,80). Recently, several investigators identified gene mutations that are associated with the development of sporadic FSGS. Single-nucleotide polymorphisms of the Wilms' tumor gene (WT1) and an upstream gene, WIT1, were found to be associated with idiopathic FSGS (84). Mutations in the WT1 gene are responsible for Frasier and Denys Drash syndromes, two childhood diseases that are characterized by FSGS (145–147). Genetic mutations in podocyte-associated proteins such as α -actinin-4, podocin, and β -integrin also have been implicated in the development of FSGS (148–150).

Epidemiology of Heroin-Associated Nephropathy

Although the prevalence of heroin abuse in the United States has increased, the incidence of "heroin nephropathy" has declined. Since the rise in heroin abuse in the United States, there also has been an increased incidence of HIV and HCV infection and their associated renal diseases (126,151,152) (Figure 1). There has been a consistent decline in the number of reported cases of heroin nephropathy since 1992, and the incidence of

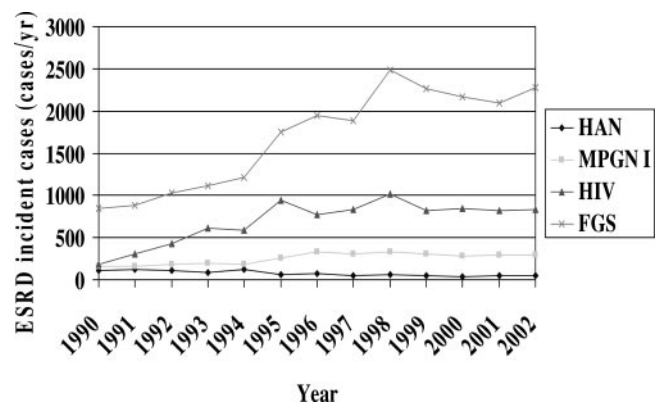


Figure 1. Incident cases of ESRD secondary to heroin-associated nephropathy, membranoproliferative glomerulonephritis type 1, HIV infection, and focal segmental glomerulosclerosis. HAN, heroin-associated nephropathy; MPGN, membranoproliferative glomerulonephritis; FGS, focal segmental glomerulosclerosis. Data from Dr. Paul Eggers, US Renal Data Systems, personal communication (February 4, 2005).

ESRD has increased 53.6% from 306,000 from 1991 to 1995 to 470,000 from 1998 to 2002 (153,154). Although there are small differences in the racial/ethnic distribution of heroin users in the United States (Table 2), the overwhelming preponderance of heroin nephropathy cases is in black men. From 1998 to 2002, 59.2% of patients with heroin nephropathy were black and 37.6% were white (153). Heroin nephropathy also is more common in male individuals, comprising 75.5% of all cases reported (153).

Case series suggest a low prevalence of renal disease in heroin users (155,156). Only three of 145 asymptomatic male heroin users who were admitted to a methadone detoxification program had daily urinary protein excretion >150 mg (155). One patient was found to have membranous glomerulonephritis, and all but one patient had normal renal function (155). Although there was a three-fold increased relative risk for mild renal functional decline in heroin users *versus* non-drug users among 647 hypertensive men, the difference was NS in multivariate analyses (91). A strong association between opiate use and ESRD among subgroups defined by gender, race, or demographic differences was demonstrated (89). However, causal links between opiate use and ESRD could not be determined (89). We could find no other studies of the incidence of proteinuria or renal dysfunction in addiction or methadone clinics to establish valid epidemiologic data on the association of opiate use and renal disease. It may be that socioeconomic conditions, cultural and behavioral practices, or differences in genetic susceptibilities to developing nephropathy are more associated with the development of nephropathy in heroin users than the pharmacologic properties of the drug (90,144).

Direct Effects of Heroin/Morphine on the Kidney: Pathophysiologic Basis for Renal Disease

Currently, there is no *in vivo* animal model of heroin nephropathy; however, there is a growing body of literature to support *in vitro* changes in renal cells that are exposed to morphine. Although few direct effects of heroin on renal structure and function have been reported, recent studies suggest that morphine has direct effects on mesangial and glomerular epithelial cells (GEC), kidney fibroblasts, and the interaction of mesangial cells with circulating and resident macrophages. Heroin cannot be metabolized to its active metabolite, morphine, in most renal cell cultures. Therefore, morphine was used instead of heroin in most *in vitro* studies.

The classic lesion of FSGS starts with mesangial cell hyperplasia and GEC hypertrophy (157). Nevertheless, in the course of either classic or variant forms of FSGS, there is eventual loss of mesangial epithelial cells and GEC (158–162). Loss of GEC or apoptosis has been suggested as an underlying mechanism in the development of FSGS (163–167).

Glomerulosclerosis is thought to result from mesangial cell expansion, increased matrix deposition, and secretory factors that are modulated by macrophages (168–178). Mesangial expansion can occur either by mesangial cell proliferation or enhanced deposition of extracellular matrix or both. Matrix-degrading metalloproteinases are regulated by tissue inhibitors of metalloproteinases (179,180). Morphine amplifies cocaine-

induced renal cortical messenger RNA expression of tissue inhibitors of metalloproteinase-2 (181), resulting in matrix accumulation. Macrophages have been implicated in the pathogenesis of FSGS (182,183). Morphine induces both inhibitory and proliferative effects on fibroblasts, mesangial cells, and macrophage activity (184–189). At lower concentrations, morphine predominantly stimulates mesangial cell and fibroblast proliferation, mesangial matrix deposition, and macrophage activity. At higher concentrations, morphine inhibits mesangial cell and fibroblast proliferation, mesangial matrix deposition, and macrophage activity (185–189).

Morphine has a bimodal effect on GEC (190). At lower concentrations, morphine promotes GEC growth, whereas at higher concentrations, morphine triggers GEC apoptosis. Moreover, antioxidants and free-radical scavengers prevent morphine-induced GEC growth as well as apoptosis, suggesting that morphine's effects may be mediated through oxidative stress. Morphine stimulates the production of superoxide by macrophages and mesangial cells (187,191), as well as the activity of macrophage heme oxygenase (192), an oxidative stress marker (193). Morphine exerts a bimodal effect on heme oxygenase activity in GEC as well (192), stimulatory at lower and suppressive at higher concentrations.

Indirect Effects of Heroin on the Kidney

AA (or secondary) amyloidosis has been described as an important cause of nephropathy among heroin users (194–208). The incidence of biopsy-proven renal amyloidosis among drug abusers with systemic amyloidosis and proteinuria varied between 25 and 67% in several series (197–199), whereas autopsies that were performed on 150 drug addicts showed an incidence of renal amyloidosis of approximately 5% (200). Menchel *et al.* (200) surveyed 150 heroin users and reported that six of the seven addicts with renal amyloidosis also had extensive skin infections from subcutaneous administration of heroin ("skin popping"). In 23 patients with skin infections, 26% had renal amyloidosis. Subcutaneous heroin administration and resultant chronic suppurative infections were presumed to be pathogenically responsible (198). The average duration of heroin abuse was 15.8 yr. This is in contrast to an average of 6.3 yr in 40 intravenous heroin users with FSGS in a different series (198). Heroin abusers primarily were black men. At the time, 38% of heroin abusers in New York State were black (198). Crowley *et al.* (195) speculated that cessation of skin popping and treatment of chronic indolent skin infections may have led to stabilization of renal function in a heroin user who developed renal amyloidosis. Although amyloidosis still was present on a subsequent renal biopsy 6 yr after the diagnosis of disease, proteinuria decreased from 6.8 g to 170 mg/d, and creatinine clearance remained unchanged. Furthermore, the route of heroin administration, the presence of suppurative skin infections, and a longer duration of heroin exposure may be associated with a chronic inflammatory state that is necessary for the pathogenesis of renal amyloidosis. It still is unclear whether cessation of skin popping can lead to its resolution.

Conclusion

Renal disease is seen frequently in drug users. It is interesting that cases of “heroin nephropathy” are few in number and have continued to decrease over the years, despite the increased prevalence of heroin use. Heroin nephropathy has been linked to a single diagnosis, FSGS, by some groups (110–112,122). The literature, however, suggests that no uniform histologic presentation of renal disease is associated with heroin use (107,108,113–116,119,120). Historically, many renal diseases have been associated with heroin use, with FSGS being the most predominant in black individuals and MPGN being the most predominant in white individuals. It is uncertain whether drug use is causal in the development of renal disease or whether nephropathy is more related to demographic, socioeconomic, or genetic factors of individual users (3,90,132,144,209). It is unclear whether FSGS in heroin users is a consequence of the habit or rather in fact represents the occurrence of a type of nephropathy that is present or over-represented in populations of drug users in the United States (79), in effect “a true, true and unrelated” condition (3,132).

The incidence of FSGS has increased in the last 20 yr and now is considered the most common cause of glomerular disease that leads to ESRD in the United States (79). Genetic factors may play a role in the development of FSGS (79–86). Recent studies suggest that black individuals with idiopathic FSGS may have a genetic predisposition to developing renal disease (79,81,83–85,144,209). It therefore is plausible that black heroin users with FSGS have a genetic susceptibility to the development of renal disease, unrelated to the drug use.

The wide spectrum of renal pathology that is found among heroin users has raised controversy regarding whether there is a causal relationship between heroin use and renal disease (100,122). The heterogeneity of responses that are associated with heroin use is not consistent with a single or simple notion of nephropathogenesis (132). Unfortunately, investigators have focused largely on descriptive studies (132). Common co-infections with HIV, HCV, HBV, and endocarditis in intravenous drug users may manifest similar histologic presentations as those described in patients who had unrelated renal disease and used heroin (123–137). Because reports of “heroin nephropathy” occurred before the identification of HCV and the dissemination of virologic, serologic, and molecular biologic diagnostic tools, it is conceivable that some of the variation in the histologic findings might have been related to the spectrum of viral illnesses that are encountered in injection drug users (3). Few studies delineate pathogenesis of a presumed heroin nephropathy or detail extensive evaluation of viral infections and host responses in patients with presumed disease (3,132). Differences in the purity of heroin and the concurrent use of various adulterants make it difficult to distinguish the effects of repeated heroin exposure from the idiosyncratic effects that accompanying contaminants may have on the kidney. Furthermore, it may be difficult to verify a history of single-drug use in patients who may not have a close relationship with their physicians (3,100,122). Therefore, in humans, it is impossible to separate the effects of contaminants or concomitant drugs on development of renal injury.

In *in vitro* cell cultures, there is a bimodal effect of morphine on mesangial epithelial cells, GEC and fibroblast proliferation; mesangial matrix deposition; and macrophage activity, depending on the concentration and temporal relationship of morphine exposure (184–189). Clearly, there has been neither a standardized concentration nor an agreed-on temporal exposure of morphine used *in vitro* that unequivocally simulates the physiologic state of the morphine/heroin addict. Moreover, there has been no *in vivo* animal model of heroin nephropathy to date. Furthermore, there is a paucity of evidence to support that morphine’s effects on renal cells in *in vitro* cell cultures are associated with the development of clinical renal disease in *in vivo* animal models.

Finally, no well-designed, prospective, epidemiologic studies have assessed the incidence and prevalence of renal disease, including urinary abnormalities, in large, well-established populations of opiate users, to establish the validity of a syndrome such as “heroin nephropathy.” Previous studies have inherent biases as case series and are subject to selection biases according to criteria outlined by investigators.

We conclude that although there is a paucity of evidence to support a heroin-associated nephropathy, the evidence from *in vitro* cellular and animal studies to support the existence of cocaine-induced renal changes is more convincing. However, clinical evidence of the association between cocaine and CKD also is sparse. In the future, well-designed, epidemiologic studies may help to elucidate the association between cocaine and renal disease.

References

1. Substance Abuse and Mental Health Services Administration: *Data from the National Survey on Drug Use and Health, 2003 Data File. Table 1.1B: Illicit Drug Use in Lifetime, Past Year, and Past Month among Persons Aged 12 or Older: Percentages, 2002 and 2003*, Rockville, Substance Abuse and Mental Health Services Administration, 2003
2. Substance Abuse and Mental Health Services Administration: *Data from the National Survey on Drug Use and Health, 2003 Data File. Table 1.1A: Illicit Drug Use in Lifetime, Past Year, and Past Month among Persons Aged 12 or Older: Numbers in Thousands, 2002 and 2003*, Rockville, Substance Abuse and Mental Health Services Administration, 2003
3. Kimmel PL, Alam S, Lew SQ: Renal disease in patients with substance abuse. In: *Nephrology*, edited by Schena FP, London, McGraw-Hill, 2001, pp 237–243
4. Bakir AA, Dunea G: Drugs of abuse and renal disease. *Curr Opin Nephrol Hypertens* 5: 122–126, 1996
5. Crowe AV, Howse M, Bell GM, Henry JA: Substance abuse and the kidney. *QJM* 93: 147–152, 2000
6. Sanders MM, Marshall AP: Acute and chronic toxic nephropathies. *Ann Clin Lab Sci* 19: 216–220, 1989
7. Paller MS: Drug-induced nephropathies. *Med Clin North Am* 74: 909–917, 1990
8. Orth SR: Adverse renal effects of legal and illicit drugs. *Ther Umsch* 59: 122–130, 2002
9. Chudhury D, Ahmed Z: Drug-induced nephrotoxicity. *Med Clin North Am* 81: 705–717, 1997
10. Giannini AJ, Price WA, Giannini MC: Contemporary drugs of abuse. *Am Fam Physician* 33: 43, 1986

11. Gay GR, Inaba DS, Sheppard CW, Newmayer JA: Cocaine: History, epidemiology, human pharmacology, and treatment. *Clin Toxicol* 8: 149–178, 1975
12. Nzerue CM, Hewan-Lowe K, Riley LJ: Cocaine and the kidney: A synthesis of pathophysiologic and clinical perspectives. *Am J Kidney Dis* 35: 783–795, 2000
13. Hollister LE: Drugs of abuse. In: *Basic and Clinical Pharmacology*, edited by Katzung BG, Norwalk, Appleton & Lange, 1992, pp 437–449
14. Zafar H, Vaz A, Carlson RW: Acute complications of cocaine intoxication. *Hosp Pract* 32: 167–181, 1997
15. Kokko JP: Presidential address of the SSCI: Metabolic and social consequences of cocaine abuse. *Am J Med Sci* 299: 361–365, 1990
16. Pitts WR, Lange RA, Cigarroa JE, Hillis DL: Cocaine-induced myocardial ischemia and infarction. Pathophysiology, recognition and management. *Prog Cardiovasc Dis* 40: 65–76, 1997
17. Substance Abuse and Mental Health Services Administration: Data from the National Survey on Drug Use and Health, Substance Abuse and Mental Health Data Archive (SAMHDA), 2002. Available: <http://www.icpsr.umich.edu/SAMHDA/archive.html>
18. Marzuk PM, Tardiff K, Leon AC, Portera L, Weiner C: Fatal injuries after cocaine use as a leading cause of death among young adults in New York City. *N Engl J Med* 332: 1753–1757, 1995
19. Boghdadi MS, Henning RJ: Cocaine: Pathophysiology and clinical toxicology. *Heart Lung* 26: 466–481, 1997
20. Substance Abuse and Mental Health Services Administration: Drug Abuse Warning Network. Annual Emergency Department Data 1994–2002. Table 2.2.0 ED mentions for selected drug categories, total ED drug episodes and mentions, and total ED visits: Estimates for the coterminous US by year. Available: http://dawninfo.samhsa.gov/old_dawn/. Accessed February 11, 2005
21. Pogue VA, Nurse HM: Cocaine-associated acute myoglobinuric renal failure. *Am J Med* 86: 183–186, 1989
22. Anand V, Siami G, Stone WJ: Cocaine-associated rhabdomyolysis and acute renal failure. *South Med J* 82: 67–69, 1989
23. Roth D, Alarcon FJ, Fernandez JA, Preston RA, Bourgoignie JJ: Acute rhabdomyolysis associated with cocaine intoxication. *N Engl J Med* 319: 673–677, 1988
24. Horst E, Bennett RL, Barrett O Jr: Recurrent rhabdomyolysis in association with cocaine use. *South Med J* 84: 269–270, 1991
25. Welch R, Todd K, Krause G: Incidence of cocaine-associated rhabdomyolysis. *Ann Emerg Med* 20: 154–157, 1991
26. Singhal P, Harowitz B, Quinones MC, Sommer M, Faulkner M, Grosser M: Acute renal failure following cocaine abuse. *Nephron* 52: 76–78, 1989
27. Nolte KB: Rhabdomyolysis associated with cocaine abuse. *Hum Pathol* 22: 1141–1145, 1991
28. Rutenber AJ, McAnally HB, Wetli CV: Cocaine-associated rhabdomyolysis and excited delirium: Different stages of the same syndrome. *Am J Forensic Med Pathol* 20: 120–127, 1999
29. Singhal PC, Rubin RB, Peters A, Santiago A, Neugarten J: Rhabdomyolysis and acute renal failure associated with cocaine abuse. *J Toxicol Clin Toxicol* 28: 321–330, 1990
30. Candnapaphornchai P, Taher S, McDonald FD: Acute drug-associated rhabdomyolysis: An examination of its diverse renal manifestations and complications. *Am J Med Sci* 280: 66–72, 1980
31. Veenstra J, Smit WM, Krediet RT, Arisz L: Relationship between elevated creatinine phosphokinase and the clinical spectrum of rhabdomyolysis. *Nephrol Dial Transplant* 9: 637–641, 1994
32. Brody SL, Wrenn KD, Wilber MM, Slovis CM: Predicting the severity of cocaine-associated rhabdomyolysis. *Ann Emerg Med* 19: 1137–1143, 1990
33. Pagala M, Amaladevi B, Azad D, Pagala S, Herzlich B, Namba T, Grob D: Effect of cocaine on leakage of creatine kinase from isolated fast and slow muscles of rat. *Life Sci* 52: 751–756, 1993
34. Daras M, Kakkouras L, Tuchman AJ, Koppel BS: Rhabdomyolysis and hyperthermia after cocaine abuse: A variant of the neuroleptic malignant syndrome? *Acta Neurol Scand* 92: 161–165, 1995
35. Pagala M, Amaladevi B, Bernstein A, Herzlich B, Namba T, Grob D: Dantrolene sodium reduces the enhanced leakage of creatine kinase caused by ethanol, cocaine, and electrical stimulation in isolated fast and slow muscles of rat. *Alcohol Clin Exp Res* 21:63–67, 1997
36. Richards JR: Rhabdomyolysis and drugs of abuse. *J Emerg Med* 19: 51–56, 2000
37. Shanti CM, Lucas CE: Cocaine and the critical care challenge. *Crit Care Med* 31: 1851–1859, 2003
38. Herlich BC, Arsura EL, Pagala M, Grob D: Rhabdomyolysis related to cocaine abuse. *Ann Intern Med* 109: 335–336, 1988
39. Menashe PI, Gottlieb JE: Hyperthermia, rhabdomyolysis, and myoglobinuric renal failure after recreational use of cocaine. *South Med J* 81: 379–380, 1988
40. Gitman MD, Singhal PC: Cocaine-induced renal disease. *Expert Opin Drug Saf* 3: 441–448, 2004
41. Cregler LL, Mark H: Medical complications of cocaine abuse. *N Engl J Med* 315: 1495–1500, 1986
42. Resnick RB, Kestenbaum RS, Schwartz LR: Acute systemic effects of cocaine in man: A controlled study by intranasal and intravenous routes. *Science* 195: 696–698, 1976
43. Warner EA: Cocaine abuse. *Ann Intern Med* 119: 226–235, 1993
44. Chiueh CC, Kopin IJ: Centrally mediated release by cocaine of endogenous epinephrine and norepinephrine from the sympathoadrenal medullary system of unanesthetized rats. *J Pharmacol Exp Ther* 205: 148–154, 1978
45. Karch SB: Serum catecholamines in cocaine-intoxicated patients with cardiac symptoms. *Ann Emerg Med* 16: 481–482, 1987
46. Rogione AJ, Steg PG, Gal D, Isner JM: Cocaine causes endothelium-independent vasoconstriction of vascular smooth muscle [Abstract]. *Circulation* 78: 5436A, 1988
47. Isner J, Chokshi S: Cardiovascular complications of cocaine. *Curr Probl Cardiol* 16: 89–123, 1991
48. Kohan DE: Endothelins in normal and diseased kidney. *Am J Kidney Dis* 29: 2–25, 1997
49. Kon V, Yoshioka T, Fogo A, Ichikawa I: Glomerular actions of endothelin in vivo. *J Clin Invest* 83: 1762–1767, 1989
50. Hendricks-Munoz KD, Gerrets PR, Higgins RD, Munoz JL, Caines VV: Cocaine-stimulated endothelin-1 release is decreased by ACE inhibitors in cultured endothelial cells. *Cardiovasc Res* 31: 117–123, 1996

51. Wilbert-Lampen U, Seliger C, Zilker T, Arendt R: Cocaine increases the endothelial release of immunoreactive endothelin and its concentrations in human plasma and urine: Reversal by cocubation with sigma-receptor antagonists. *Circulation* 98: 385–390, 1998
52. Samuels P, Steinfeld JD, Braitman LE, Rhoa MF, Cines DB, McCrae KR: Plasma concentration of endothelin-1 in women with cocaine-associated pregnancy complications. *Am J Obstet Gynecol* 168: 528–533, 1993
53. Miyazaki M, Okunishi H, Nishimura K, Toda N: Vascular angiotensin-converting enzyme activity in man and other species. *Clin Sci* 66: 39–45, 1984
54. Momose N, Fukuo K, Morimoto S, Ogihara T: Captopril inhibits endothelin-1 secretion from endothelial cells through bradykinin. *Hypertension* 21: 921–924, 1993
55. Trouve R, Latour C, Nahas G: Cocaine and the renin-angiotensin system. *Adv Biosci* 80: 165–176, 1991
56. Mo W, Singh AK, Arruda JA, Dunea G: Role of nitric oxide in cocaine-induced acute hypertension. *Am J Hypertens* 11: 708–714, 1998
57. Kolodgie FD, Wilson PS, Corhill JF, Herderick EE, Mergner WJ, Viran R: Increased prevalence of aortic fatty streaks in cholesterol-fed rabbits administered intravenous cocaine: The role of vascular endothelium. *Toxicol Pathol* 21: 425–435, 1993
58. Lagner RO, Bement CL, Cohen L, Nielsen SW: Stimulation of atherogenesis by cocaine in cholesterol-fed rabbits [Abstract]. *FASEB J* 3: 297A, 1989
59. Dressler FA, Malekzadeh SJ, Roberts WC: Quantitative analysis of amounts of coronary artery narrowing in cocaine addicts. *Am J Cardiol* 65: 303–308, 1990
60. Om A, Warner M, Sabri N, Cecich L, Vetrovec G: Frequency of coronary artery disease and left ventricular dysfunction in cocaine users. *Am J Cardiol* 69: 1549–1552, 1992
61. Lagner R, Bement C: Cocaine-induced changes in biochemistry and morphology of rabbit aorta. *Natl Inst Drug Abuse Res Monogr Ser* 108: 154–166, 1991
62. Eichorn EJ, Demian SE, Alvarez G: Cocaine-induced alterations in prostaglandin production in rabbit aorta. *J Am Coll Cardiol* 92: 696–703, 1992
63. Mattana J, Gibbons N, Singhal PC: Cocaine interacts with macrophages to modulate mesangial cell and epithelial cell proliferation. *J Pharmacol Exp Ther* 271: 311–318, 1994
64. Dipaolo N, Fineschi V, Dipaolo M, Wetly CV, Garosi G, Delveccio MT, Branciardi G: Kidney vascular damage and cocaine. *Clin Nephrol* 47: 298–303, 1997
65. Fogo A, Keith R, Superdock I, Atkinson JB: Severe atherosclerosis in the kidney of a cocaine addict. *Am J Kidney Dis* 20: 513–515, 1992
66. Van der Woude FJ, Waldherr R: Severe arterio-arteriosclerosis after cocaine use. *Nephrol Dial Transplant* 14: 434–435, 1999
67. Escobedo LG, Ruttenberg AJ, Anda RF, Sweeney PA, Wetli CV: Coronary artery disease, left ventricular hypertrophy, and the risk of cocaine overdose death. *Coronary Artery Dis* 3: 853, 1992
68. Kolodgie FD, Virmani R, Cornhill JF, Herderick EE, Smialek J: Increase in atherosclerosis and adventitial mast cells in cocaine abusers: An alternative mechanism of cocaine-associated coronary vasospasm and thrombosis. *J Am Coll Cardiol* 17: 1553–1560, 1991
69. Lange RA, Hillis LD: Cardiovascular complications of cocaine use. *N Engl J Med* 345: 351–358, 2001
70. Dressler FA, Malekzadeh S, Roberts WC: Quantitative analysis of amounts of coronary arterial narrowing in cocaine addicts. *Am J Cardiol* 65: 303–308, 1990
71. Palamara AT, DiFrancesco P, Ciriolo MR, Bue C, Lafaria E, Rotilio G, Garaci E: Cocaine increases Sendai virus replication in cultured epithelial cells: Critical role of intracellular redox status. *Biochem Biophys Res Commun* 228: 579–585, 1996
72. Tonga G, Tempesta E, Tonga A: Platelet responsiveness and biosynthesis of thromboxane and prostacyclin in response to in vitro cocaine treatment. *Haemostasis* 15: 100–107, 1989
73. Kugelmass AD, Oda A, Monahan K, Cabral C, Ware JA: Activation of human platelets by cocaine. *Circulation* 88: 876–883, 1993
74. Kugelmass AD, Shannon R, Yeo E, Ware JA: Intravenous cocaine induces platelet activation in the conscious dog. *Circulation* 91: 1336–1340, 1995
75. Thakur VK, Godley C, Weed S, Cook ME, Hoffman E: Cocaine-associated accelerated hypertension and renal failure. *Am J Med Sci* 312: 295–298, 1996
76. Dunea G, Arruda JL, Bakir AA, Share DS, Smith EC: Role of cocaine in end-stage renal disease in some hypertensive African-Americans. *Am J Nephrol* 15: 5–9, 1995
77. Bakir AA, Bazilinski NG, Rhee HI, Ainis H, Dunea G: Focal segmental glomerulosclerosis. A common entity in nephrotic black adults. *Arch Intern Med* 149: 1802–1804, 1989
78. Korbet SM: Clinical picture and outcome of primary focal segmental glomerulosclerosis. *Nephrol Dial Transplant* 14[Suppl 3]: 68–73, 1999
79. Kitiyakara C, Kopp JB, Eggers PW: Trends in the epidemiology of focal segmental glomerulosclerosis. *Semin Nephrol* 23: 172–182, 2003
80. Kitiyakara C, Eggers PW, Kopp JB: Twenty-one-year trend in ESRD due to focal segmental glomerulosclerosis in the United States. *Am J Kidney Dis* 44: 815–825, 2004
81. Kopp JB, Winkler C: HIV-associated nephropathy in African Americans. *Kidney Int Suppl* 83: s43–s49, 2003
82. Winn MP: Approach to the evaluation of heritable diseases and update on familial focal segmental glomerulosclerosis. *Nephrol Dial Transplant* 18[Suppl 6]: 14–20, 2003
83. Andreoli SP: Racial and ethnic differences in the incidence and progression of focal segmental glomerulosclerosis in children. *Adv Ren Replace Ther* 11: 105–109, 2004
84. Orloff MS, Iyengar SK, Winkler CA, Goddard KA, Dart RA, Ahuja TS, Mokrzycki M, Briggs WA, Korbet SM, Kimmel PL, Simon EE, Trachtman H, Vlahov D, Michel DM, Berns JS, Smith MC, Schelling JR, Sedor JR, Kopp JB: Variants in the Wilms tumor gene are associated with focal segmental glomerulosclerosis in the African American population. *Physiol Genomics* 21: 212–221, 2005
85. Tucker JK: Focal segmental glomerulosclerosis in African Americans. *Am J Med Sci* 323: 90–93, 2002
86. Devarajan P, Spitzer A: Towards a biological characterization of focal glomerulosclerosis. *Am J Kidney Dis* 39: 625–636, 2002
87. Schena FP: Primary glomerulonephritides with nephrotic syndrome. Limitations of therapy in adult patients. *J Nephrol* 12[Suppl 2]: S125–S130, 1999
88. Barroso-Moguel R, Mendez-Armenta M, Villeda-Hernan-

- dez J: Experimental nephropathy by chronic administration of cocaine in rats. *Toxicol* 98: 41–46, 1995
89. Perneger T, Klag M, Whelton PK: Recreational drug use: A neglected risk factor for end-stage renal disease. *Am J Kidney Dis* 38: 49–56, 2001
 90. Norris KC, Thornhill-Joynes M, Tareen N: Cocaine use and chronic renal failure. *Semin Nephrol* 21: 262–366, 2001
 91. Vupputuri S, Batuman V, Muntner P, Bazzano LA, Lefante JJ, Whelton PK, He J: The risk for mild kidney function decline associated with illicit drug use among hypertensive men. *Am J Kidney Dis* 43: 629–635, 2004
 92. Norris KC, Thornhill-Joynes M, Robinson C, Strickland T, Alpers BL, Witana SC, Ward HJ: Cocaine use, hypertension, and end-stage renal disease. *Am J Kidney Dis* 38: 523–528, 2001
 93. Shea S, Misra D, Ehrlich MH, Field L, Francis CK: Predisposing factors for severe, uncontrolled hypertension in an inner-city minority population. *N Engl J Med* 327: 776–781, 1992
 94. Pettinger WA, Lee HC, Reisch J, Mitchell HC: Long-term improvement in renal function after short-term strict blood pressure control in hypertensive nephrosclerosis. *Hypertension* 13: 766–772, 1989
 95. Strickland TL, Turner S: Cultural considerations in the assessment and treatment of mental and substance abuse disorders. *J Psychopathol Behav Assess* 19: 75–175, 1997
 96. Perneger TV, Rossiter KA, Klag MJ, Whelton PK: Diagnosis of hypertensive end-stage renal disease: Effect of patient's race. *Am J Epidemiol* 41: 10–15, 1995
 97. Goodman PE, Rennie PM: Renal infarction secondary to nasal insufflation of cocaine. *Am J Emerg Med* 13: 421–423, 1995
 98. Peces R, Navascues RA, Baltar J, Seco M, Alvarez J: Anti-glomerular basement membrane antibody-mediated glomerulonephritis after intranasal cocaine. *Nephron* 81: 434–438, 1999
 99. Alvarez D, Nzerue CM, Faruque S, Daniel JF, Hewan-Lowe K: Crack-cocaine induced acute interstitial nephritis. *Nephrol Dial Transplant* 14: 1260–1262, 1999
 100. Cunningham EE, Venuto RC, Zielesny MA: Adulterants in heroin/cocaine: Implications concerning heroin-associated nephropathy. *Drug Alcohol Depend* 14: 1–22, 1984
 101. US Drug Threat Assessment: *Drug Intelligence Report, DEA-93042*, Washington, DC, US Department of Justice, Drug Enforcement Administration, 1993
 102. National Institute on Drug Abuse: *Drug Use Among Racial/Ethnic Minorities* [DHHS pub. no. NIH 03–3888], Rockville, National Institute on Drug Abuse, 2003
 103. Substance Abuse and Mental Health Services Administration: *Summary of Findings from the 2003 National Household Survey on Drug Abuse. Table 4.4A: Numbers (in Thousands) of Persons Who First Used Heroin in the United States, Their Mean Age at First Use, and Rates of First Use (Per 1,000 Person-Years of Exposure): 1965–2002, Based on 2002 and 2003 NSDUHs*, Rockville, Substance Abuse and Mental Health Services Administration, 2004. Available: <http://oas.samhsa.gov/nhsda/2k3tabs/Sect4peTabs1to60.htm#tab4.4a>. Accessed February 11, 2005
 104. Substance Abuse and Mental Health Services Administration: *Drug Abuse Warning Network. Annual Emergency Department Data 2003. DAWN Series D- 24* [DHHS pub. no. (SMA) 03-3780], Rockville, Substance Abuse and Mental Health Services Administration, 2003. Available: <http://dawninfo.samhsa.gov/>. Accessed February 11, 2005
 105. Substance Abuse and Mental Health Services Administration: *Summary of Findings from the 2000 National Household Survey on Drug Abuse* [DHHS pub. no. (SMA) 01-3549], Rockville, Substance Abuse and Mental Health Services Administration, 2001
 106. Substance Abuse and Mental Health Services Administration: *Summary of Findings from the 1999 National Household Survey on Drug Abuse* [DHHS pub. no. (SMA) 00-3466], Rockville, Substance Abuse and Mental Health Services Administration, 2000
 107. McGinn JT, McGinn TG, Hoffman RS: Nephrotic syndrome in heroin and cocaine addicts [Abstract]. *Clin Res* 18: 699A, 1970
 108. Kilcoyne MM, Gocke DG, Meltzer JL, Daly JJ, Thomson GE, Hsu KC, Tannenbaum M: Nephrotic syndrome in heroin addicts. *Lancet* 1: 17, 1972
 109. Rao TKS, Nicastrì AD, Friedman EA: Natural history of heroin associated nephropathy. *N Engl J Med* 290: 19, 1974
 110. Friedman EA, Rao TK, Nicastrì AD: Heroin-associated nephropathy. *Nephron* 13: 421–426, 1974
 111. Rao TKS, Nicastrì AD, Friedman EA: Renal consequences of narcotic abuse. *Adv Nephrol Necker Hosp* 7: 261–290, 1977
 112. Salomon MI, Poon TP, Goldblatt M, Tchertkoff V: Renal lesions in heroin addicts. A study based on kidney biopsies. *Nephron* 9: 356–363, 1972
 113. Cunningham EE, Brentjens JR, Zielesny MA, Andres GA, Venuto RC: Heroin nephropathy. A clinicopathologic and epidemiologic study. *Am J Med* 68: 47–53, 1980
 114. Cunningham EE, Zielesny MA, Venuto RC: Heroin-associated nephropathy. A nationwide problem. *JAMA* 250: 2935–2936, 1983
 115. Llach F, Descoeudres C, Massry SG: Heroin associated nephropathy. Clinical and histological studies in 19 patients. *Clin Nephrol* 11: 7–12, 1979
 116. Grisham E, Chung J, Porush JG: Glomerular morphology in nephrotic heroin addicts. *Lab Invest* 35: 415–424, 1976
 117. McAllister CJ, Horn R, Havron S, Abramson JH: Granulomatous interstitial nephritis: A complication of heroin abuse. *South Med J* 72: 162–165, 1979
 118. May DC, Helderma JH, Eigenbrodt EH, Silva FG: Chronic sclerosing glomerulopathy (heroin-associated nephropathy) in intravenous T's and Blues abusers. *Am J Kidney Dis* 8: 404–409, 1986
 119. do Sameiro Fario M, Sampaio S, Faria V, Carvalho E: Nephropathy associated with heroin abuse in Caucasian patients. *Nephrol Dial Transplant* 18: 2308–2313, 2003
 120. Dettmeyer R, Wessling B, Madea B: Heroin associated nephropathy: A post-mortem study. *Forensic Sci Int* 95: 109–116, 1998
 121. Lynn KL, Pickering W, Gardner J, Bailey RR, Robson RA: Intravenous drug use and glomerular deposition of lipid-like material. *Nephron* 80: 274–276, 1998
 122. Friedman EA, Rao TK: Disappearance of uremia due to heroin-associated nephropathy. *Am J Kidney Dis* 12: 45–50, 1995
 123. Pardo V, Meneses R, Ossa L, Jaffe DJ, Strauss J, Roth D, Bourgoignie JJ: AIDS-related glomerulopathy: Occurrence in specific risk groups. *Kidney Int* 31: 1167–1173, 1987
 124. Bourgoignie JJ, Pardo V: The nephropathology in human

- immunodeficiency virus infection. *Kidney Int* 40[Suppl 35]: S19–S23, 1991
125. Humphreys MH: Human immunodeficiency virus infection. *Kidney Int* 48: 311–320, 1995
 126. Johnson RJ, Willson R, Yamabe H, Couser W, Alpers CE, Wener MH, Davis C, Gretch DR: Renal manifestations of hepatitis C virus infection. *Kidney Int* 46: 1255–1263, 1994
 127. Casanova S, Mazzucco G, di Belgiojoso GB, Motta M, Boldorini R, Genderini A, Monga G: Pattern of glomerular involvement in human immunodeficiency virus-infected patients: An Italian study. *Am J Kidney Dis* 26: 446–453, 1995
 128. D'Amico G, Fornasieri A: Cryoglobulinemic glomerulonephritis: A membranoproliferative glomerulonephritis induced by hepatitis C virus. *Am J Kidney Dis* 25: 361–369, 1995
 129. D'Amico G: Hepatitis B and C virus-associated glomerulonephritis and mixed cryoglobulinemia. In: *Current Therapy in Nephrology and Hypertension*, 4th Ed., edited by Glassock RJ, St. Louis, Mosby-Year Book, 1998, pp 152–155
 130. D'Agati V, Appel GB: HIV infection and the kidney. *J Am Soc Nephrol* 8: 138–152, 1998
 131. Weiner NJ, Goodman JW, Kimmel PL: Human immunodeficiency virus-associated renal diseases: Current insight into pathogenesis and treatment. *Kidney Int* 63: 1618–1631, 2003
 132. Kimmel PL, Moore J Jr: Viral glomerulonephritides. In: *Diseases of the Kidney*, 6th Ed., edited by Schrier RW, Boston, Little, Brown and Co., 1997, pp 1595–1618
 133. Lai KN, Lai FM: Clinical features and natural history of hepatitis B virus-related glomerulopathy in adults. *Kidney Int Suppl* 35: S40–S45, 1991
 134. Lai KN, Li PK, Lui SF, Au TC, Tam JS, Tong KL, Lai FM: Membranous nephropathy related to hepatitis B virus in adults. *N Engl J Med* 324: 1457–1563, 1991
 135. Neugarten J, Baldwin DS: Glomerulonephritis in bacterial endocarditis. *Am J Med* 77: 297–304, 1984
 136. Neugarten J, Gallo GR, Baldwin DS: Glomerulonephritis in bacterial endocarditis. *Am J Kidney Dis* 3: 371–379, 1984
 137. Johnson RJ, Couser WG: Hepatitis B infection and renal disease. Clinical, immunopathogenetic and therapeutic considerations. *Kidney Int* 37: 663–676, 1990
 138. Garfein R, Vlahov D, Galei N, Doherty MC, Nelson KE: Viral infections in short-term drug users. *Am J Public Health* 86: 655–661, 1996
 139. Donahue JG, Nelson KE, Munoz A, Vlahov D, Rennie LL, Taylor EL, Saah AJ, Cohn S, Odaka NJ, Farzadegan H: Antibody to hepatitis C virus among cardiac surgery patients, homosexual men, and intravenous drug users in Baltimore, Maryland. *Am J Epidemiol* 134: 1206–1211, 1991
 140. Levine OS, Vlahov D, Koehler J, Cohn S, Spronk AM, Nelson KE: Seroepidemiology of hepatitis B virus in a population of injection drug users: Association with drug injection patterns. *Am J Epidemiol* 142: 331–341, 1995
 141. Vlahov D, Anthony JC, Munoz A, Margolick J, Nelson KE, Celentano DD, Solomon L, Polk BF: The ALIVE study: A longitudinal study of HIV-1 infection in intravenous drug users: Description of methods. *J Drug Issues* 21: 759–776, 1991
 142. Haskell LP, Glicklich D, Senitzer D: HLA associations in heroin-associated nephropathy. *Am J Kidney Dis* 12: 45–50, 1988
 143. Friedman EA, Rao TK: Why does uremia in heroin abusers occur predominantly among blacks? *JAMA* 250: 2965–2966, 1983
 144. Satko SG, Freedman BI: The importance of family history on the development of renal disease. *Curr Opin Nephrol Hypertens* 13: 337–341, 2004
 145. Barbaux S, Niaudet P, Gubler MC, Grunfeld JP, Jaubert F, Kuttann F, Fekete CN, Souleyreau-Therville N, Thibaud E, Fellous M, McElreavey K: Donor splice-site mutations in WT1 are responsible for Frasier syndrome. *Nat Genet* 17: 467–470, 1997
 146. Patek CE, Little MH, Fleming S, Miles C, Charlier JP, Clarke AR, Miyagawa K, Christie S, Doig J, Harrison DJ, Porteous DJ, Brookes AJ, Hooper ML, Hastie ND: A zinc finger truncation of murine WT1 results in the characteristic urogenital abnormalities of Denys-Drash syndrome. *Proc Natl Acad Sci U S A* 96: 2931–2936, 1999
 147. Pelletier J, Bruening W, Kashtan CE, Mauer SM, Manivel JC, Striegel JE, Houghton DC, Junien C, Habib R, Fouser L, et al.: Germline mutations in the Wilms' tumor suppressor gene are associated with abnormal urogenital development in Denys-Drash syndrome. *Cell* 67: 437–447, 1991
 148. Kaplan JM, Kim SH, North KN, Rennke H, Correia LA, Tong HQ, Mathis BJ, Rodriguez-Perez JC, Allen PG, Beggs AH, Pollak MR: Mutations in ACTN4, encoding alpha-actinin-4, cause familial focal segmental glomerulosclerosis. *Nat Genet* 24: 251–256, 2000
 149. Boute N, Gribouval O, Roselli S, Benessy F, Attie T, Gubler MC, Niaudet P, Antignac C: NPHS2, encoding the glomerular podocin, is mutated in autosomal recessive steroid-resistant nephrotic syndrome. *Nat Genet* 24: 349–354, 2000
 150. Kambham N, Tanji N, Seigle RL, Markowitz GS, Pulkkinen L, Uitto J, D'Agati VD: Congenital focal segmental glomerulosclerosis associated with beta-4 integrin and epidermolysis bullosa. *Am J Kidney Dis* 36: 190–196, 2000
 151. Kimmel PL, Barisoni L, Kopp JB: Pathogenesis and treatment of HIV-associated renal diseases: Lessons from clinical and animal studies, molecular pathologic correlations, and genetic investigations. *Ann Intern Med* 139: 214–226, 2003
 152. Eggers PW, Kimmel PL: Is there an epidemic of HIV infection in the US ESRD program? *J Am Soc Nephrol* 15: 2477–2485, 2004
 153. US Renal Data System: *USRDS 2004 Annual Data Report. Reference Table A. 11: Incidence of Reported ESRD: All Patients, Row Percent 1998–2002*, Bethesda, National Institutes of Health, National Institute of Diabetes and Digestive and Kidney Diseases, 2004. Available: <http://www.usrds.org>. Accessed February 11, 2005
 154. US Renal Data System: *USRDS 1997 Annual Data Report. Reference Table II-2: Incidence of Reported ESRD: All Patients, Row Percent 1998–2002*, Bethesda, National Institutes of Health, National Institute of Diabetes and Digestive and Kidney Diseases, 1997. Available: <http://www.usrds.org>. Accessed February 11, 2005
 155. Arruda JA, Kurtzman NA, Pillay VK: Prevalence of renal disease in asymptomatic heroin addicts. *Arch Intern Med* 135: 535–537, 1975
 156. Arruda JA, Kurtzman NA: Heroin addiction and renal disease. *Contrib Nephrol* 7: 69–78, 1977
 157. Pesce CM, Striker LJ, Peten E, Elliot S, Striker GE: Glomerulosclerosis at both early and late stage is associated with

- increased cell turnover in mice transgenic for growth hormone. *Lab Invest* 65: 601–605, 1991
158. Barisoni L, Kriz W, Mundel P, and D'Agati V: The dysregulated podocyte phenotype: A novel concept in the pathogenesis of collapsing idiopathic focal segmental glomerulosclerosis and HIV-associated nephropathy. *J Am Soc Nephrol* 10: 51–61, 1999
 159. Fogo AB: Progression and potential regression of glomerulosclerosis. *Kidney Int* 59: 804–819, 2001
 160. Kriz W, LeHir M: Pathways to nephron loss starting from glomerular diseases—insights from animal models. *Kidney Int* 67: 404–419, 2005
 161. Kriz W, Endlich K: Hypertrophy of podocytes: a mechanism to cope with increased glomerular capillary pressures? *Kidney Int* 67: 373–374, 2005
 162. Kriz W: The pathogenesis of 'classic' focal segmental glomerulosclerosis: Lessons from rat models. *Nephrol Dial Transplant* 18[Suppl 6]: 39–44, 2003
 163. Hattori T, Shindo S, Kawamura H: Apoptosis and expression of Bax protein and Fas antigen in glomeruli of a remnant-kidney model. *Nephron* 79: 86–191, 1998
 164. Shankland SJ, Floege J, Thomas SE, Nangaku M, Hugo C, Pippin J, Henne K, Hockenberry DM, Johnson RJ, Couser WG: Cyclin kinase inhibitors are increased during experimental membranous nephropathy: Potential role in limiting glomerular epithelial cell proliferation in vitro. *Kidney Int* 52: 404–413, 1997
 165. Shankland SJ, Wolf G: Cell cycle regulatory proteins in renal disease: Role in hypertrophy, proliferation, and apoptosis. *Am J Physiol Renal Physiol* 278: F515–F529, 2000
 166. Johnson JE Jr, White JJ Jr, Walovitch RC, London ED: Effects of morphine on rat kidney glomerular podocytes: A scanning electron microscopic study. *Drug Alcohol Depend* 19: 249–257, 1987
 167. Bodi I, Abraham AA, Kimmel PL: Apoptosis in human immunodeficiency virus-associated nephropathy. *Am J Kidney Dis* 26: 286–291, 1995
 168. Schlondorff D: The glomerular mesangial cell: An expanding role for a specialized pericyte. *FASEB J* 1: 272–281, 1987
 169. Diamond JR, Pesek I, Ruggieri S, Karnovsky MJ: Essential fatty acid deficiency during acute aminonucleoside nephrosis ameliorates late renal injury. *Am J Physiol* 257: F798–F807, 1989
 170. Diamond JR, Pesek I: Sublethal X-irradiation during acute puromycin nephrosis prevents late renal injury: Role of glomerular and interstitial macrophages. *Am J Physiol* 260: F760–F767, 1991
 171. Ding G, Pesek-Diamond I, Diamond JR: Cholesterol, macrophages, gene expression of TGF-beta1 and fibronectin during nephrosis. *Am J Physiol* 264: F577–F584, 1993
 172. Harris L, Lefkowitz J, Klahr S, Schreiner GF: Essential fatty acid deficiency ameliorates acute renal dysfunction in the rat after the administration of puromycin. *J Clin Invest* 86: 1115–1123, 1990
 173. Van Goor H, Fidler V, Weening JJ, Grond J: Determinants of focal and segmental glomerulosclerosis in the rat after ablation. Evidence for involvement of macrophages and lipids. *Lab Invest* 64: 754–765, 1991
 174. Van Goor H, Horst MLC, Fidler V, Grond J: Glomerular macrophage modulation affects mesangial expansion in the rat after renal ablation. *Lab Invest* 66: 564–571, 1992
 175. Kapasi AA, Gibbons N, Mattana J, Singhal PC: Morphine stimulates mesangial cell TNF-alpha and nitrite production. *Inflammation* 24: 263–476, 2000
 176. Saito T, Atkins RC: Contribution of mononuclear leukocytes to the progression of experimental focal glomerulosclerosis. *Kidney Int* 37: 1076–1083, 1990
 177. Pan CQ, Singhal PC: Coordinate and independent effects of cocaine, alcohol and morphine on accumulation of IgG aggregates in rat glomeruli. *Proc Soc Exp Biol Med* 205: 29–34, 1994
 178. Sagar S, Sorbi D, Arbeit LA, Singhal PC: Morphine modulates 72-kDa matrix metalloproteinase. *Am J Physiol* 267: F654–F659, 1994
 179. Matrisian LM: Metalloproteinases and their inhibitors in connective tissue remodeling. *Trends Genet* 6: 121–125, 1990
 180. Woessner JF: Matrix metalloproteinases and their inhibitors in connective tissue remodeling. *FASEB J* 5: 2145–2154, 1991
 181. Kapasi AJ, Mattana J, Wagner J: Morphine amplifies cocaine-induced renal cortical expression of tissue inhibitors of metalloproteinase (TIMP)-2 [Abstract]. *J Am Soc Nephrol* 6: 528A, 1997
 182. Nikolic-Paterson DJ, Atkins RC: The role of macrophages in glomerulonephritis. *Nephrol Dial Transplant* 16[Suppl 5]: 3–7, 2001
 183. Nikolic-Paterson DJ, Lan HY, Hill PA, Atkins RC: Macrophages in renal injury. *Kidney Int Suppl* 45: S79–S82, 1994
 184. Singhal PC, Pan CQ, Sagar S, Gibbons N, Valderrama E: Morphine enhances deposition of ferritin-antiferritin complexes in the glomerular mesangium. *Nephron* 70: 229–234, 1995
 185. Singhal PC, Kapasi AA, Franki N, Reddy K: Morphine-induced macrophage apoptosis: The role of TGF-beta. *Immunology* 100: 57–62, 2000
 186. Singhal PC, Gibbons N, Abramovici M: Long-term effects of morphine on mesangial cell proliferation and matrix synthesis. *Kidney Int* 41: 1560–1570, 1992
 187. Singhal PC, Pamarthi M, Shah R, Chandra D, Gibbons N: Morphine stimulates superoxide formation by glomerular mesangial cells. *Inflammation* 18: 293–299, 1994
 188. Singhal PC, Mattana J, Garg P, Arya M, Shan Z, Gibbons N, Franki N: Morphine-induced macrophage activity modulates mesangial cell proliferation and matrix synthesis. *Kidney Int* 49: 94–102, 1996
 189. Singhal PC, Sharma P, Sanwal V, Prasad A, Kapasi A, Franki N, Reddy K, Gibbons N: Morphine modulates proliferation of kidney fibroblasts. *Kidney Int* 53: 350–357, 1998
 190. Patel J, Manjappa N, Bhat R, Mehrotra P, Bhaskaran M, Singhal PC: Role of oxidative stress and heme oxygenase activity in morphine-induced glomerular epithelial growth. *Am J Physiol Renal Physiol* 258: F861–F869, 2003
 191. Sharp BM, Keane WF, Suh HJ, Gekker G, Tsukayama D, Peterson PK: Opioid peptides stimulate superoxide production by human polymorphonuclear leukocytes and macrophages. *Endocrinology* 117: 793–795, 1985
 192. Patel K, Bhaskaran M, Dani D, Reddy K, Singhal PC: Role of heme oxygenase (HO)-1 in morphine-modulated apoptosis and migration of macrophages. *J Infect Dis* 187: 47–54, 2003
 193. Maines MD: Heme oxygenase, function, multiplicity, regulatory mechanisms and clinical implications. *FASEB J* 2: 2557–2568, 1988

194. Neugarten J, Gallo GR, Buxbaum J, Katz LA, Rubenstein J, Baldwin DS: Amyloidosis in subcutaneous heroin abusers ("skin poppers' amyloidosis"). *Am J Med* 81: 635, 1986
195. Crowley S, Feinfeld DA, Janis R: Resolution of nephrotic syndrome and lack of progression of heroin-associated renal amyloidosis. *Am J Kidney Dis* 35: 1358–1370, 1989
196. Dubrow A, Mittman N, Ghali V, Flamenbaum W: The changing spectrum of heroin associated nephropathy. *Am J Kidney Dis* 5: 36–41, 1985
197. Kunis C, Olesnicky M, Nurse H, Pirani C, Appel G: Heroin nephropathy: clinical pathologic correlations. *Proc 9th Int Congr Nephrol* 102A, 1984
198. Baldwin DS, Neugarten J, Gallo GR: Nephrotoxicity secondary to drug abuse and lithium use. In: *Diseases of the Kidney*, 6th Ed., edited by Schrier RW, Gottschalk CE, Boston, Little, Brown, 1997, pp 1203–1230
199. Brus I, Steiner G, Maceda A, Lejano R: Amyloid fibrils in urinary sediment. Heroin addiction with renal amyloidosis. *N Y State J Med* 79: 768–771, 1979
200. Menchel S, Cohen D, Gross E, Frangione B, Gallo G: AA protein-related renal amyloidosis in drug addicts. *Am J Pathol* 112: 195–199, 1983
201. Jacob H, Charytan C, Rascoff JH, Golden R, Janis R: Amyloidosis secondary to drug abuse and chronic skin suppuration. *Arch Intern Med* 138: 1150–1151, 1978
202. Jao W, Pirani CL: Renal amyloidosis: Electron microscopic observations. *Acta Pathol Microbiol Scand [A]* 80[Suppl 233]: 217–227, 1972
203. Lowenstein J, Gallo G: Remission of the nephrotic syndrome in renal amyloidosis. *N Engl J Med* 282: 128–132, 1970
204. Meador KH, Sharon Z, Lewis EJ: Renal amyloidosis and subcutaneous drug abuse. *Ann Intern Med* 91: 565–567, 1979
205. Triger DR, Joekes AM: Renal amyloidosis: A fourteen year follow-up. *Q J Med* 42: 15–40, 1973
206. Scholes J, Derosena R, Appel GB, Jao W, Boyd MT, Pirani CL: Amyloidosis in chronic heroin addicts with the nephrotic syndrome. *Ann Intern Med* 91: 26–29, 1979
207. Derosena R, Koss MN, Pirani CL: Demonstration of amyloid fibrils in the urinary sediment. *N Engl J Med* 293: 1131–1133, 1975
208. Tan AU Jr, Cohen AH, Levine BS: Renal amyloidosis in a drug abuser. *J Am Soc Nephrol* 5: 1653–1658, 1995
209. Freedman BI, Soucie JM, Stone SM, Pegram S: Familial clustering of end-stage renal disease in blacks with HIV-associated nephropathy. *Am J Kidney Dis* 34: 254–258, 1999